

# The Relationship Between Achilles Tendon Thickness and In-stent Restenosis in Patients with Carotid Stents

Cemalettin Yılmaz<sup>1,2</sup>, Büşra Güvendi Şengör<sup>1</sup>, Mehmet Hasan Özdil<sup>3</sup>, Ahmet Ferhat Kaya<sup>3</sup>, Lütfi Öcal<sup>1</sup>, Nuri Havan<sup>1,4</sup>, Ali Karagöz<sup>1</sup>, Mehmet Vefik Yazıcıoğlu<sup>1</sup>, Regayip Zehir<sup>1</sup>

<sup>1</sup> Kartal Kosuyolu Research and Education Hospital, Department of Cardiology, İstanbul, Türkiye.

<sup>2</sup> Malazgirt State Hospital, Department of Cardiology, Muş, Türkiye.

<sup>3</sup> Muş State Hospital, Department of Cardiology, Muş, Türkiye.

<sup>4</sup> Demiroğlu Science University, Florence Nightingale Ataşehir Hospital, Department of Radiology, İstanbul, Türkiye.

Correspondence Author: Cemalettin Yılmaz

E-mail: cmlddyn@gmail.com

Received: 29.06.2023

Accepted: 31.03.2024

## ABSTRACT

**Objective:** Considering that atherosclerosis and Achilles tendon thickening share common mechanisms, the aim of this study to reveal the relationship between Achilles tendon thickness (ATT) and carotid in-stent restenosis (ISR).

**Methods:** In this study, 89 patients who had carotid stenting for carotid artery disease at our institute between 2016 and 2020 were included. Subjects were divided into two groups as restenosis (+) and restenosis (-) based on the ultrasonographic and/or angiographic findings. The development of 50% or more restenosis in the carotid stent was defined as ISR. Bilateral ATT was measured for all patients who satisfied the inclusion criteria.

**Results:** In our study, 16 (17.9%) patients constituted the restenosis group and 73 (82%) the no-restenosis group. ATT values were similar between groups ( $4.9 \pm 0.8$  vs  $4.7 \pm 0.6$ ,  $p = .27$ ). However, in the marginal effect graphic, it has been demonstrated that the probability of carotid stent restenosis increases with the increase in the mean ATT. The probability of restenosis was 14% when the mean ATT value was 4.16 mm (mean - 1 SD) and the probability of restenosis was 22% when the mean ATT value was 5.36 mm (mean + 1 SD).

**Conclusion:** No significant difference was found in ATT between the restenosis and no-restenosis group, however, the probability of restenosis increased with increasing ATT. In addition, ultrasonographic measurement of ATT is an easy, inexpensive and safe method that can be used to identify patients at high risk for carotid stent restenosis.

**Keywords:** Carotid artery disease, carotid stent restenosis, Achilles tendon thickness, atherosclerosis, cerebrovascular disease

## 1. INTRODUCTION

Advances in catheter-based techniques have allowed symptomatic carotid artery patients and asymptomatic patients at increased risk of stroke to be treated with results similar to conventional carotid endarterectomy. Carotid artery stenting (CAS) is an alternative to carotid endarterectomy (CEA). Despite advances in stent technology, carotid in-stent restenosis (ISR) continues to occur at a rate of approximately 10% (1–3).

Restenosis can be defined as measuring the degree of recurrent stenosis  $\geq 50\%$  (moderate) or  $\geq 70\%$  (severe) in the treated artery (4). While half of the cases are seen in the first 6 months, data on stent restenosis are limited in long-term follow-ups (5). Female gender, advanced age, diabetes mellitus (DM), hyperlipidemia, smoking, history of radiation

to the neck, type of stent used, and residual stenosis after CAS are the most important risk factors (6).

Two important mechanisms have explained the development of carotid restenosis. Early carotid restenosis that develops within 12 months after the procedure is associated with neointimal hyperplasia (7,8). As a result of the force applied by the stent to the vessel wall, there is smooth muscle and fibroblast migration from the media layer to the intima in response to the damage to the intima layer. Activation of platelets and lymphocytes causes the release of cellular mediators. These mediators result in smooth muscle cell and collagen matrix proliferation, resulting in neointimal hyperplasia. Damage from stenting causes a more severe reaction compared to angioplasty (9,10). Carotid restenosis

that developed after 12 months after stenting was associated with progressive neo-atherosclerosis (11).

Achilles tendon thickness (ATT) has been identified as an independent predictor of coronary artery disease (CAD) and atherosclerosis (12–16). Especially in patients who are genetically predisposed to hypercholesterolemia, lipid and connective tissue accumulation occurs in the extracellular matrix of tendons. Lipid deposition in tendons appears clinically as a tendon xanthoma and is often seen in the Achilles tendon. The initial form of xanthomas is the thickening of the tendon. This is not usually reflected in the clinic, but can be viewed via ultrasonography or magnetic resonance imaging (MRI). In fact, xanthomas are accumulations of lipid-laden macrophages (foam cells) in the tendon matrix. Xanthomas and cardiovascular diseases, beyond being related to each other, share common pathophysiological mechanisms (17). The purpose of this study was to examine the relationship between ATT and carotid stent restenosis.

## 2. METHODS

In this study, 89 patients who had carotid stenting for carotid artery disease at our institute between 2016 and 2020 were included. The study was constituted in accordance with the Declaration of Helsinki and protocol of study was approved by own ethics committees of our institution. The patients who signed the informed consent form were included in our study population. The patients with severe stroke sequelae that cannot be mobilized, Achilles tendon rupture, foot deformity that may affect image quality, a history of amputation owing to peripheral artery disease, rheumatoid arthritis, ankylosing spondylitis, Achilles tendinitis or tenosynovitis, bursitis, tuberculum attriticum, and Achilles patients with conditions that will affect the thickness of the Achilles tendon, such as tendon surgery were excluded.

### 2.1. Measurement of Achilles Tendon Thickness

Bilateral ATT was measured for all patients who satisfied the inclusion criteria. The measurement of thickness and width of the Achilles tendons of the patients was performed blindly by an experienced radiologist. A high-resolution B-mode ultrasonography device (Hitachi Medical Systems – HiVision Preirus) with a 7 MHz linear probe was used in measurement. The Achilles tendon was imaged with the patient lying prone (prone position) and ankles extended from the examination stretcher (Fig. 1(A)). The ankle was slightly bent by 90 degrees to increase the contact between the probe and tendon (Fig. 1(B)). The thickness and width of a tendon; they measured bilaterally by taking the mean of three measurements at the medial malleolus level in transverse scans above the tuber calcaneus insertion site, and the mean values were taken (Fig. 1(C),1(D)). Ultrasonographically measured ATT and Achilles tendon width (ATW) were measured as right and left for both extremities, mean values were obtained by summing the right and left measurements and dividing them into two. Average measurements were divided by body

surface area (BSA) and average Achilles tendon thickness and width were indexed. BSA was calculated using the formula  $BSA = 0.007184 \times \text{Height}^{0.725} \times \text{Weight}^{0.425}$ .

### 2.2. Carotid Duplex Ultrasonography (DUS)

The primary outcome of our study was carotid stent restenosis. The development of 50% or more stenosis in the stent is defined as stent restenosis (18). In the Radiology and Imaging Center of our hospital, Peak Systolic Velocity (PSV) and B Mode imaging are used in the grading of carotid stent restenosis. As described by Setacci et al., gradients above 3 m/s were defined as significant restenosis (18). Carotid Doppler USG was performed on the patients at the 1st and 6th months, 1st year and then annually after CAS, and it was evaluated whether there was an ISR. Patients diagnosed with restenosis ultrasonographically were confirmed by angiography.

### 2.3. Statistical analysis

The distribution of numerical data was evaluated with a histogram and Shapiro-Wilks test. Numerical baseline characteristics were evaluated by the Mann-Whitney-u test and independent t-test, and according to the distribution of variables, categorical ones were evaluated by the chi-square test. Normally distributed numerical variables were expressed as mean±standard deviation, and categorical variables were expressed as absolute numbers and percentages. A *p* value of <.05 was identified as significant. For carotid stent restenosis, which is the main outcome, the Achilles tendon thickness parameter, which is the parameter we are interested in, was added to the regression model, except for the parameters taken in previous studies (variables such as age, gender, creatinine). The predicted probability model was checked for the best explanatory model. In addition, the explanatory feature of Achilles tendon thickness was shown with the marginal mean.

## 3. RESULTS

89 patients who underwent CAS due to carotid artery disease were enrolled in our study. In the study population, restenosis was found in 16 (17.9%) patients. The mean age of the study population was 65.9±7.2 years. Comparisons of clinical, demographic and laboratory features according to the presence of restenosis are shown in Table 1. Variables such as age, DM, hypertension (HT), CAD, lower extremity peripheral arterial disease, smoking, statin use, low or high dose statin use were similar between groups. The association between thickness and width of the Achilles tendon and carotid stent restenosis, is shown in Table 2. When the right ATT measurements were 5±0.9 mm in the restenosis group, it was 4.8±0.6 mm in the non-restenosis group (*p*=.21). When the left ATT was 4.8±0.7 mm in patients with restenosis, it was 4.7±0.6 mm in patients without restenosis (*p*=.41). The mean ATT values were 4.9±0.8 mm and 4.7±0.6 mm in patients with restenosis and without restenosis, respectively. There was no remarkable difference between the groups

( $p=.27$ ). In addition, ATT was indexed to BSA but, results were similar between restenosis and no-restenosis groups ( $2.6\pm 0.5$  mm/m<sup>2</sup> vs  $2.5\pm 0.4$  mm/m<sup>2</sup>,  $p=.37$ , respectively). Additionally, measurements of Achilles tendon width did not differ between groups.

**Table 1.** Comparison of clinical and laboratory characteristics according to the presence of restenosis.

Variables	Restenosis (-) (N:73)	Restenosis (+) (N:16)	All patients (N:89)	<i>p</i> value
Age, year	65.7±7.2	66.6±7.7	65.9±7.2	.64
BMI, kg/m <sup>2</sup>	27.8±4.06	28.2±4.40	27.8±4.1	.80
BSA, m <sup>2</sup>	1.9±0.2	1.9±0.2	1.9±0.2	.97
DM, n (%)	31.0 (42.5)	7.0 (43.8)	38.0 (42.7)	.92
HT, n (%)	63.0 (86.3)	11.0 (68.8)	74.0 (83.1)	.089
HL, n (%)	52.0 (71.2)	14.0 (87.5)	66.0 (74.2)	.178
CAD n (%)	55.0 (75.3)	12.0 (75)	67.0 (75.3)	.97
Smoking, n (%)	42 (57.5)	8 (50)	50 (56.2)	.58
Peripheral artery disease, n (%)	16 (21.9)	4 (25)	20 (22.5)	.079
Statin therapy, n (%)				.95
Not using	25 (34.2)	6 (37.5)	31 (34.8)	
Low dose	27 (37)	6 (37.5)	33 (37.1)	
High dose	21 (28.8)	4 (25)	25 (28.1)	
Total cholesterol, mg/dl	168 ±44	182±57	171±46	.26
HDL cholesterol mg/dl	44±11	46±11	45±11	.57
LDL cholesterol, mg/dl	91±38	103±47	93±40	.25
Triglyceride, mg/dl	164±87	164±61	164±82	.99
Creatinin, mg/dl	1.2±1.1	1.1±0.4	1.2±1	.75
CRP, mg/L	8.2±25	7.5±8.9	8.1±23	.90
Albumin, g/dl	6±8.1	4.2±0.5	5.6±7.4	.38
WBC, 10 <sup>3</sup> /μL	8.6±2.6	7.4±1.1	8.4±2.4	.08
Neutrophil, 10 <sup>3</sup> /μL	5.2±2.3	4.7±0.8	5.1±2.2	.38
Lymphocyte, 10 <sup>3</sup> /μL	2.3±0.8	1.8±0.6	2.2±0.7	.02
Hemoglobin, g/dl	13.5±2.1	12.8±2.3	13.4±2.2	.25
Platelet, 10 <sup>3</sup> /μL	267±75	244±63	263±73	.26

BSA, body surface area; BMI, body mass index; DM, Diabetes mellitus; HT, Hypertension; HL, hyperlipidemia; CAD, Coronary artery disease; HDL, High Density lipoprotein; LDL, low density lipoprotein; CRP, C-reactive protein; WBC, white blood cell.

**Table 2.** Comparison of Achilles tendon thickness and Achilles tendon width according to the presence of restenosis.

Variables	Restenosis (-) (N:73)	Restenosis (+) (N:16)	All patients (N:89)	<i>p</i> value
Right ATT, mm	4.8±0.6	5±0.9	4.8±0.7	.21
Left ATT, mm	4.7±0.6	4.8±0.7	4.7±0.6	.41
Mean ATT, mm	4.7±0.6	4.9±0.8	4.8±0.6	.27
Mean ATT index, mm/m <sup>2</sup>	2.5±0.4	2.6±0.5	2.5±0.4	.37
Right ATW, mm	16.3±2.1	17±2.5	16.5±2.2	.26
Left ATW, mm	16±1.8	16.1±2.7	16±2	.74
Mean ATW, mm	16.1±1.9	16.6±2.5	16.2±2	.44
Mean ATW index, mm/m <sup>2</sup>	8.5±1.3	8.7±1.4	8.5±1.3	.61

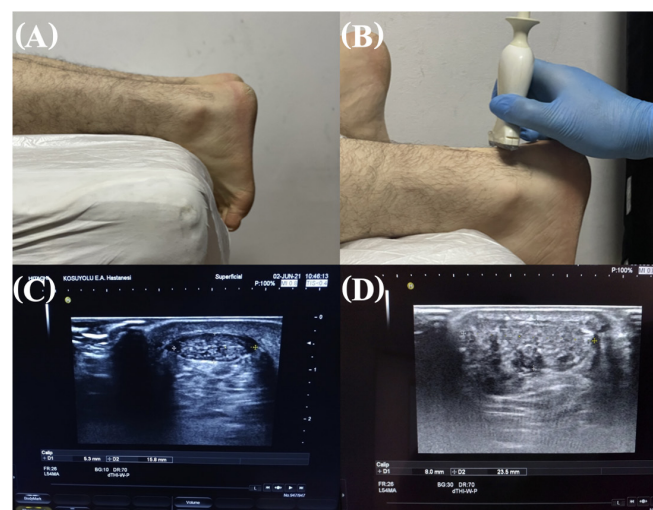
ATT, Achilles tendon thickness; ATW, Achilles tendon width.

The distribution of ATT values in subjects with and without restenosis is shown in Figure 2. After correcting for age, the probability of restenosis was 14% when the mean ATT value was 4.16 mm (Mean-1 SD), while the probability of restenosis was 22% when the mean ATT value was 5.36 mm (mean + 1SD) (Table 3). This value suggests that ATT may be associated with the possibility of restenosis. The marginal effect graph showing the relationship between ATT and the probability of restenosis is shown in Figure 3. In this graph, when the ATT value is 5.7 mm, the probability of restenosis is 25%, when the ATT value is 6.8 mm, the probability reaches 37.5%.

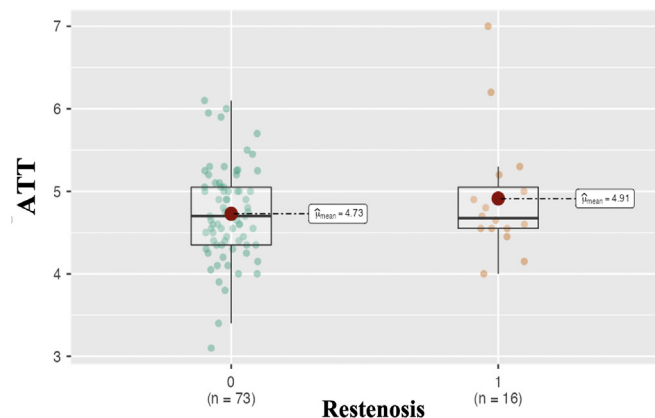
**Table 3.** Mean Achilles tendon thickness and probability of restenosis.

	ATT	Probability of restenosis	Standard error
Mean - 1 SD	4.16	0.14	0.05
Mean	4.76	0.18	0.04
Mean +1 SD	5.36	0.22	0.06

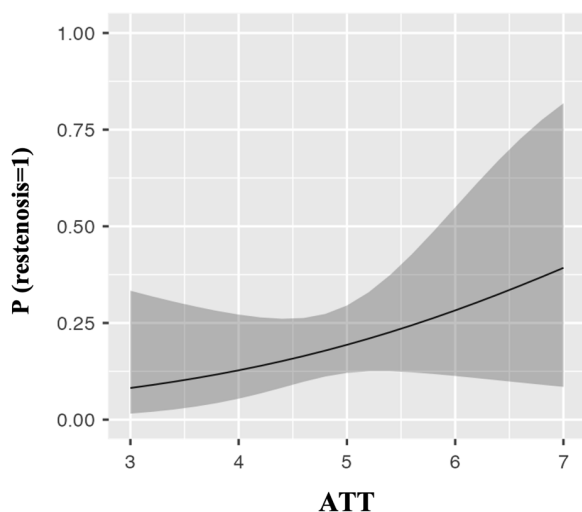
SD, standard deviation; ATT, Achilles tendon thickness.



**Figure 1.** Position of patient and probe in Achilles tendon thickness measurement. (A). Achilles tendon imaging was performed with the patient prone position and ankles extended from the examination stretcher. (B). To facilitate contact between the probe and the tendon, the probe was positioned by bending the ankle slightly by 90 degrees. (C). Measurement of Achilles tendon thickness (5.3 mm) and width (15.8 mm) in transverse section. (D). Achilles tendon ultrasonography of a patient with familial hypercholesterolemia and stent restenosis on carotid DUS. The thickness (8 mm) and width (23.5 mm) of the Achilles tendon have increased, the fibrillar structure of the tendon has deteriorated, and a type 3 sonographic pattern with nodular xanthomatous appearance is observed.



**Figure 2.** Bar graph showing the distribution of mean ATT values with standard error in patients with and without restenosis.



**Figure 3.** Marginal effect plot showing the relationship between the mean Achilles tendon thickness (ATT) and the probability of restenosis (P).

#### 4. DISCUSSION

ATT, which shares common mechanisms with atherosclerosis, has been identified as an independent predictor of CAD and atherosclerosis (12,13,15,17). In present study, we revealed that mean ATT values were similar in subjects with and without restenosis. However, according to marginal effect graphic (Figure 3), the probability of carotid stent restenosis may tend to be increased when the ATT level increased.

Identification of predictors of ISR is clinically important. However, there is no study in the literature determining the relationship between carotid ISR and ATT, hence our study is the first. The association of ATT with restenosis has been attributed to atherosclerosis, but the relationship of ATT to neo-intimal hyperplasia is unclear. Perhaps this uncertainty can be investigated in more comprehensive and larger studies. Our findings showed that the right, left, mean ATT and mean indexed ATT were not different in patients with and without restenosis. However, the probability of carotid stent restenosis increased with the increase in

mean ATT (Figure 3). It might suggest that ATT value may be associated with carotid stent restenosis. Currently, several studies have evaluated the association between ATT and carotid artery disease. A previous study revealed that a remarkable correlation occurred between ATT and carotid intima media thickness in patients diagnosed with familial hyperlipidemia (19). In another study, ATT was identified as an independent predictor of atherosclerosis in carotid artery (20). ATT, which was discovered that it has a relationship with carotid plaque burden, was found significantly increased in patients with carotid stenosis. It has been discovered that when ATT reaches to  $\approx 5.07$  mm, predicting the presence of atherosclerotic plaques in the carotid arteries might be possible (sensitivity: 68.3% and specificity: 62.5%) (20). Similarly, the mean ATT value of 89 patients who underwent CAS in our study was measured as 4.76 mm. At this value, the probability of carotid stent restenosis was 18% with a standard error of 0.04. With an increase in this value, the probability of restenosis increases. Although a cut-off value for ATT required for restenosis is not clear in the literature, these results suggest that the Achilles tendon must reach a certain thickness for restenosis to occur.

Several studies evaluated the relationship between ATT and CAD (12–15,21,22) in literature. In our study, 67 (75.3%) patients were diagnosed with CAD and 12 (75%) patients with carotid stent restenosis had CAD. CAD was more widespread in patients with increased ATT, and also they have more left main coronary artery (LMCA) disease and more advanced and/or vulnerable plaque structure (14). Thus, it has been claimed that ATT may be a marker to identify high-risk patients. Hirobe et al. reported that ATT was thicker in patients diagnosed with familial hyperlipidemia with CAD than without CAD (22). ATT was found to be higher in diabetic patients and patients with a Syntax score  $>23$ , in a study included patients who underwent percutaneous coronary procedure (12). It has been also discovered a linear relationship between tendon xanthomas and coronary calcium score (15). These studies demonstrated that ATT is an independent predictor of CAD and atherosclerosis.

ATT is a clinical marker to identify patients who have a high risk for cardiovascular diseases and elevated LDL cholesterol levels (23). A few studies showed that tendon xanthomas regress after drugs such as statin, ezetimibe, and PCSK-9 inhibitors are used in the treatment of hyperlipidemia (24,25). As we showed in our study, while the increase in the mean ATT value increases the probability of restenosis, when we think in the opposite direction, it seems possible to decrease the probability of restenosis with the decrease in the mean ATT value. Reducing Achilles tendon thickness with lipid-lowering therapy might be an affective method to reduce the possibility of restenosis. Nonetheless, the relationship between the use of lipid-lowering therapy and the possibility of restenosis could not be demonstrated in our study. The small size of patient population and the low persistence on statin therapy might make the clinical impact of statin therapy uncertain.

Recently, also a relationship between ATT and, diabetes, hyperuricemia, obesity has been revealed (26). In particular, ATT has been associated with diabetes in many studies (26,27). It is well known that DM is also a risk factor for carotid stent restenosis. This association can be attributed to diabetes being a strong predictor of atherosclerosis. Interestingly, significant difference was not occurred between DM and restenosis in our study.

In diabetic patients, ATT has increased in male patients with retinopathy or neuropathy compared to the group without these complications (26). When the relationship between DM, HT or obesity and ATT was evaluated, no significant difference was found in our study. This results can be explained by the fact that our patient group consists of very high-risk patients. However, the examination of the ATT is important in determining the high-risk group that will be exposed to the complications of diabetes (26).

Consequently, ultrasonographic measurement of ATT is an easily accessible, inexpensive and applicable method to determine the high-risk group for carotid stent restenosis. Our study has some limitations: 1) In our small sample group with very high cardiovascular risk, DM and multiple drug use may have affected ATT; 2) The single-center design of our study may prevent the generalization of the study results; 3) Evaluation with Doppler USG and B mode requires user experience, in our study, the measurements were made blindly by a radiologist. If the measurements were made blindly by two different users, more reliable results could be obtained.

## 5. CONCLUSION

To our best knowledge, our study is the first single institutional study evaluated the association of ATT with carotid stent restenosis. No significant difference was found in ATT between the restenosis and the no-restenosis group. However, the probability of restenosis increased with increasing ATT. In addition, ultrasonographic measurement of ATT is an easy, inexpensive and safe method to identify patients at increased risk for carotid stent restenosis. Further large-scale multicenter studies are required to accept ATT, which is considered a marker of atherosclerosis, as a predictor of carotid stent restenosis.

**Acknowledgement:** None

**Funding:** The authors have no relevant financial or non-financial interests to disclose.

**Conflicts of interest:** None

**Ethics Committee Approval:** This study was approved by Ethics Committee of Kartal Koşuyolu Training and Research Hospital (approval date 09.03.2021 and number 2021/5/484)

**Peer-review:** Externally peer-reviewed.

**Author Contributions:**

Research idea: MVY, RZ, CY.

Design of the study: CY, RZ.

Acquisition of data for the study: RZ, AFK, BGŞ, MHÖ.

Analysis of data for the study: AK, NH, LÖ.

Interpretation of data for the study: LO, AK, RZ.

Drafting the manuscript: RZ, CY, BGŞ.

Revising it critically for important intellectual content: RZ, MVY, LO.

Final approval of the version to be published: RZ, MVY, CY, BGŞ.

## REFERENCES

- [1] Brott TG, Howard G, Roubin GS, Meschia JF, Mackey A, Brooks W, Moore WS, Hill MD, Mantese VA, Clark WM, Timaran CH, Heck D, Leimgruber PP, Sheffet AJ, Howard VJ, Chaturvedi S, Lal BK, Voeks JH, Hobson RW, CREST Investigators. Long-term results of stenting versus endarterectomy for carotid-artery stenosis. *N Engl J Med.* 2016;374(11):1021-1031. DOI: 10.1056/NEJMoa1505215
- [2] Bonati LH, Dobson J, Featherstone RL, Ederle J, van der Worp HB, de Borst GJ, Mali WPTM, Beard JD, Cleveland T, Engelter ST, Lyrer PA, Ford GA, Dorman PJ, Brown MM, International Carotid Stenting Study investigators. Long-term outcomes after stenting versus endarterectomy for treatment of symptomatic carotid stenosis: The International Carotid Stenting Study (ICSS) randomised trial. *Lancet* 2015;385(9967):529-538. DOI: 10.1016/S0140-6736(14)61184-3
- [3] Eckstein HH, Ringleb P, Allenberg JR, Berger J, Fraedrich G, Hacke W, Hennerici M, Stingele R, Fiehler J, Zeumer H, Jansen O. Results of the Stent-Protected Angioplasty versus Carotid Endarterectomy (SPACE) study to treat symptomatic stenoses at 2 years: A multinational, prospective, randomised trial. *Lancet Neurol.* 2008;7(10):893-902. DOI: 10.1016/S1474-4422(08)70196-0
- [4] Barros P, Felgueiras H, Pinheiro D, Guerra M, Gama V, Veloso M. Restenosis after carotid artery stenting using a specific designed ultrasonographic protocol. *Journal of Stroke and Cerebrovascular Diseases* 2014;23(6):1416-1420. DOI: 10.1016/j.jstrokecerebrovasdis.2013.12.002
- [5] Tekieli Ł, Musiałek P, Kabłak-Ziembicka A, Trystuła M, Przewłocki T, Legutko J, Dzierwa K, Maciejewski D, Michalski M, Pieniżek P. Severe, recurrent in-stent carotid restenosis: Endovascular approach, risk factors. Results from a prospective academic registry of 2637 consecutive carotid artery stenting procedures (TARGET-CAS). *Postepy Kardiologii Interwencyjnej.* 2019;15(4):465. DOI: 10.5114/AIC.2019.90221
- [6] Lal BK, Beach KW, Roubin GS, Lutsep HL, Moore WS, Malas MB, Chiu D, Gonzales NR, Burke JL, Rinaldi M, Elmore JR, Weaver FA, Narins CR, Foster M, Hodgson KJ, Shepard AD, Meschia JF, Bergelin RO, Voeks JH, Howard G, Brott TG, CREST Investigators. Restenosis after carotid artery stenting and endarterectomy: A secondary analysis of CREST, a randomised controlled trial. *Lancet Neurol.* 2012;11(9):755-763. DOI: 10.1016/S1474-4422(12)70159-X
- [7] Mousa AY, AbuRahma AF, Bozzay J, Broce M, Kali M, Yacoub M, Stone P, Bates MC. Long-term Comparative Outcomes of Carotid Artery Stenting Following Previous Carotid Endarterectomy vs De Novo Lesions. *J Endovasc Ther.* 2015;22(3):449-456. DOI: 10.1177/152.660.2815581597
- [8] Clark DJ, Lessio S, O'Donoghue M, Tsalamandris C, Schainfeld R, Rosenfield K. Mechanisms and predictors of carotid artery stent restenosis: A serial intravascular ultrasound study. *J Am Coll Cardiol.* 2006;47(12):2390-2396. DOI: 10.1016/J.JACC.2006.01.076
- [9] Kornowski R, Hong MK, Tio FO, Bramwell O, Wu H, Leon MB. In-stent restenosis: Contributions of inflammatory responses

- and arterial injury to neointimal hyperplasia. *J Am Coll Cardiol.* 1998;31(1):224-230. DOI: 10.1016/s0735-1097(97)00450-6
- [10] Schwartz RS, Huber KC, Murphy JG, Edwards WD, Camrud AR, Vlietstra RE, Holmes DR. Restenosis and the proportional neointimal response to coronary artery injury: Results in a porcine model. *J Am Coll Cardiol.* 1992;19(2):267-274. DOI: 10.1016/0735-1097(92)90476-4
- [11] Matsumoto H, Yako R, Masuo O, Hirayama K, Uematsu Y, Nakao N. A case of in-stent neoatherosclerosis 10 years after carotid artery stent implantation: Observation with optical coherence tomography and plaque histological findings. *Neurol Med Chir (Tokyo).* 2014;54(2):139-144. DOI: 10.2176/NMC.CR2013-0063
- [12] Kitahara H, Nakayama T, Fujimoto Y, Kobayashi Y. Association between Achilles tendon xanthoma and severity of coronary artery disease in patients undergoing percutaneous coronary intervention. *J Cardiol.* 2020;75(6):654-658. DOI: 10.1016/j.jjcc.2020.01.002
- [13] Kitahara H, Mori N, Saito Y, Nakayama T, Fujimoto Y, Kobayashi Y. Prevalence of Achilles tendon xanthoma and familial hypercholesterolemia in patients with coronary artery disease undergoing percutaneous coronary intervention. *Heart Vessels.* 2019;34(10):1595-1599. DOI: 10.1007/s00380.019.01400-6
- [14] Hashimoto T, Minami Y, Kakizaki R, Nemoto T, Fujiyoshi K, Meguro K, Shimohama T, Tojo T, Ako J. Achilles tendon thickening is associated with disease severity and plaque vulnerability in patients with coronary artery disease. *J Clin Lipidol.* 2019;13(1):194-200. DOI: 10.1016/j.jacl.2018.10.007
- [15] Mangili LC, Miname MH, Silva PRS, Bittencourt MS, Rocha VZ, Mangili OC, Salgado Filho W, Chacra AP, Jannes CE, Pereira AC, Santos RD. Achilles tendon xanthomas are associated with the presence and burden of subclinical coronary atherosclerosis in heterozygous familial hypercholesterolemia: A pilot study. *Atherosclerosis.* 2017;263:393-397. DOI: 10.1016/J.ATHEROSCLEROSIS.2017.04.025
- [16] Oosterveer DM, Versmissen J, Yazdanpanah M, Hamza TH, Sijbrands EJG. Differences in characteristics and risk of cardiovascular disease in familial hypercholesterolemia patients with and without tendon xanthomas: A systematic review and meta-analysis. *Atherosclerosis* 2009;207(2):311-317. DOI: 10.1016/J.ATHEROSCLEROSIS.2009.04.009
- [17] Soslowsky LJ, Fryhofer GW. Tendon homeostasis in hypercholesterolemia. *Advances in Experimental Medicine and Biology.* Springer New York LLC; 2016:151-165. DOI: 10.1007/978-3-319-33943-6\_14
- [18] Setacci C, Chisci E, Setacci F, Iacoponi F, De Donato G. Grading carotid intrastent restenosis: a 6-year follow-up study. *Stroke* 2008;39(4):1189-1196. DOI:10.1161/STROKEAHA.107.497487
- [19] Kiortsis DN, Argyropoulou MI, Tsouli SG, Xydis V, Elisaf MS. Correlation of Achilles tendon thickness evaluated by ultrasonography with carotid intima-media thickness in patients with familial hypercholesterolemia. *Atherosclerosis* 2006;186(1):228-229. DOI: 10.1016/J.ATHEROSCLEROSIS.2006.02.002
- [20] Genkel V, Kuznetsova A, Lebedev E, Sinitskii A, Pykhova L, Shaposhnik I. Achilles tendon thickness is an independent predictor of carotid atherosclerosis and is associated with a carotid plaque burden. *Angiology* 2020;71(8):734-739. DOI: 10.1177/000.331.9720928226
- [21] Mabuchi H, Tatami R, Haba T, Ueda K, Ueda R, Ito S, Karnetani T, Koizumi J, Miyamoto S, Ohta M, Takeda R, Takegoshi T, Takeshita H. Achilles tendon thickness and ischemic heart disease in familial hypercholesterolemia. *Metabolism* 1978;27(11):1672-1679. DOI: 10.1016/0026-0495(78)90289-5
- [22] Hirobe K, Matsuzawa Y, Ishikawa K, Tarui S, Yamamoto A, Nambu S, Fujimoto K. Coronary artery disease in heterozygous familial hypercholesterolemia. *Atherosclerosis* 1982;44(2):201-210. DOI: 10.1016/0021-9150(82)90114-9
- [23] Wang B, Zhang Q, Lin L, Pan LL, He CY, Wan XX, Zheng ZA, Huang ZX, Zou CB, Fu MC, Kutryk MJ. Association of Achilles tendon thickness and LDL-cholesterol levels in patients with hypercholesterolemia. *Lipids Health Dis.* 2018;17(1):131. DOI: 10.1186/s12944.018.0765-x
- [24] Illingworth DR, Cope R, Bacon SP. Regression of tendon xanthomas in patients with familial hypercholesterolemia treated with lovastatin. *South Med J.* 1990;83(9):1053-1057. DOI: 10.1097/00007.611.199009000-00019
- [25] Tsouli SG, Xydis V, Argyropoulou MI, Tselepis AD, Elisaf M, Kiortsis DN. Regression of Achilles tendon thickness after statin treatment in patients with familial hypercholesterolemia: An ultrasonographic study. *Atherosclerosis* 2009;205(1):151-155. DOI: 10.1016/j.atherosclerosis.2008.10.032
- [26] Akturk M, Ozdemir A, Maral I, Yetkin I, Arslan M. Evaluation of achilles tendon thickening in type 2 diabetes mellitus. *Experimental and Clinical Endocrinology and Diabetes* 2007;115(2):92-96. DOI: 10.1055/s-2007-955097
- [27] Khor BYC, Woodburn J, Newcombe L, Barn R. Plantar soft tissues and Achilles tendon thickness and stiffness in people with diabetes: A systematic review. *J Foot Ankle Res.* 2021;14(1). DOI: 10.1186/S13047.021.00475-7

**How to cite this article:** Yılmaz C, Güvendi Şengör B, Özdil MH, Kaya AF, Öcal L, Havan N, Karagöz A, Yazıcıoğlu MV, Zehir R. The Relationship Between Achilles Tendon Thickness and In-stent Restenosis in Patients with Carotid Stents. *Clin Exp Health Sci* 2024; 14: 393-398. DOI: 10.33808/clinexphealthsci.1320825