

# VOLUMETRIC ANALYSIS OF OSTEOMAS OF THE SPHENOID SINUS USING CONE BEAM COMPUTED TOMOGRAPHY

## KONİK IŞINLI BİLGİSAYARLI TOMOGRAFİ KULLANILARAK SFENOİD SINÜS OSTEOMLARININ HACİMSEL ANALİZİ

Sevde GÖKSEL<sup>1</sup>, Hülya ÇAKIR KARABAŞ<sup>2</sup>, Ahmet Faruk ERTÜRK<sup>3</sup>, İlkur ÖZCAN<sup>3</sup>,  
Kaan ORHAN<sup>4,5,6</sup>

<sup>1</sup>Ankara Tepebaşı Oral and Dental Health Hospital, Ankara, Türkiye

<sup>2</sup>İstanbul University, Faculty of Dentistry, Department of Oral and Maxillofacial Radiology, İstanbul, Türkiye

<sup>3</sup>Biruni University, Faculty of Dentistry, Department of Oral and Maxillofacial Radiology, İstanbul, Türkiye

<sup>4</sup>Ankara University, Faculty of Dentistry, Department of Oral and Maxillofacial Radiology, Ankara, Türkiye

<sup>5</sup>Ankara University, Medical Design Application, and Research Center (MEDITAM), Ankara, Türkiye

<sup>6</sup>Medical University of Lublin, Department of Dental and Maxillofacial Radiodiagnostics, Lublin, Poland

ORCID ID: S.G. 0000-0003-0092-7079; H.Ç.K. 0000-0001-9258-053X; A.F.E. 0000-0002-4404-1547; İ.Ö. 0000-0001-9006-5630; K.O. 0000-0001-6768-0176

**Citation/Atf:** Gökse S, Çakır Karabaş H, Ertürk AF, Özcan İ, Orhan K. Volumetric analysis of osteomas of the sphenoid sinus using Cone Beam Computed Tomography. Journal of Advanced Research in Health Sciences 2024;7(1):50-54. <https://doi.org/10.26650/JARHS2023-1326592>

### ABSTRACT

**Objectives:** Osteomas are benign bone tumors characterized by slow growth, well-defined borders, and often asymptomatic presentation, frequently incidentally identified through radiography. Sphenoid sinus osteomas are particularly rare occurrences within the paranasal sinuses. This study aims to investigate the incidence and volumetric characteristics of sphenoid sinus osteomas.

**Material and Methods:** This retrospective analysis involved the examination of cone-beam computed tomography (CBCT) images obtained from patients referred to the Department of Oral and Maxillofacial Radiology for various complaints. Two radiologists independently reviewed the images, recording instances of sphenoid sinus osteomas, their volumes, and patient demographics, which were subsequently subjected to statistical analysis.

**Results:** A total of 1466 tomography images (821 females, 645 males) were assessed. Among these, 23 osteomas were identified within the sphenoid sinuses of 17 patients (eight females, nine males). The mean volume of these osteomas was 183.59 mm<sup>3</sup>±168.56 (with a range of 9.98 to 552.80). No statistically significant difference in sphenoid osteoma volumes between males and females was observed (Mann-Whitney U test, U=30.000, p=0.564, z=-0.577).

**Conclusion:** Consistent with existing literature, the incidence of sphenoid sinus osteomas in this study was found to be 1.15%. While asymptomatic osteomas detected via radiography typically do not warrant surgical intervention, regular radiographic follow-up is recommended to monitor for potential complications.

**Keywords:** Cone-beam computed tomography, osteoma, sphenoid sinus

### Öz

**Amaç:** Osteomlar, yavaş büyüme, iyi tanımlanmış sınırlar ve sıklıkla asemptomatik görünüm ile karakterize, sıklıkla tesadüfen radyografi ile tanımlanan iyi huylu kemik tümörleridir. Sfenoit sinüs osteomu paranasal sinüste görülen en nadir osteomlardır. Bu çalışmanın amacı sfenoit sinüs osteomlarının sıklığını ve volümetrik analizini araştırmaktır.

**Gereç ve Yöntemler:** Bu retrospektif analiz, Ağız Diş ve Çene Radyolojisi Bölümü'ne çeşitli şikayetler nedeniyle başvuran hastalardan elde edilen konik ışınli bilgisayarlı tomografi (KİBT) görüntülerinin incelenmesini içeriyordu. İki radyolog görüntüleri bağımsız olarak inceledi, sfenoit sinüs osteomlarının örneklerini, hacimlerini ve hasta demografik özelliklerini kaydetti ve bunlar daha sonra istatistiksel analize tabi tutuldu.

**Bulgular:** 1466 (821 kadın, 645 erkek) hastanın tomografi görüntüleri değerlendirildi. 17 hastanın (Sekiz kadın, dokuz erkek) sfenoit sinüslerinde toplam 23 osteom saptandı. Ortalama osteoma hacmi 183,59 mm<sup>3</sup>±168,56 (min. 9,98, maks. 552,80) idi. Erkek ve kadın sfenoit osteoma hacimleri arasında anlamlı fark bulunamadı (Mann-Whitney U testi, U=30,000, p=0,564, z=-0,577).

**Sonuç:** Literatüre uygun olarak bu çalışmada sfenoit sinüste osteom görülme sıklığı %1,15 olarak bulundu. Radyografide asemptomatik saptanan osteomlarda cerrahi tedavi önerilmemekle birlikte olası komplikasyon riskine karşı periyodik radyografik muayene ile takip edilmelidir.

**Anahtar Kelimeler:** Konik ışınli bilgisayarlı tomografi, osteoma, sfenoit sinüs

**Corresponding Author/Sorumlu Yazar:** Sevde GÖKSEL E-mail: dt.sevde@gmail.com

**Submitted/Başvuru:** 12.07.2023 • **Revision Requested/Revizyon Talebi:** 23.08.2023 • **Last Revision Received/Son Revizyon:** 09.10.2023

• **Accepted/Kabul:** 06.11.2023 • **Published Online/Online Yayın:** 07.02.2024



This work is licensed under Creative Commons Attribution-NonCommercial 4.0 International License

## INTRODUCTION

Osteomas are generally benign, slow-growing bone tumors often discovered incidentally due to their asymptomatic nature. They are commonly found in the paranasal sinuses (PNS) and the mandible within the head and neck region (1-3). Osteomas can be composed of cancellous bone, cortical bone, or a combination of both (4, 5). While Veiga's pioneering report in 1586 marked the initial removal of a frontal sinus tumor, subsequent literature began featuring cases of osteomas (6). Although osteomas are the prevailing benign PNS tumors, they frequently remain symptomless, emerging only as chance findings in radiographic assessments (7, 8). Sinus osteomas initiate from the sinus walls and develop toward the sinus cavity.

Among the PNS, osteomas predominantly appear in the frontal sinus, followed by the ethmoid, maxillary, and sphenoid sinuses in decreasing order of prevalence (3, 7, 9). The literature predominantly consists of case reports detailing sphenoid sinus osteomas, while scant resources address the frequency of these occurrences. This study endeavors to assess the incidence and volumes of sphenoid sinus osteomas using cone beam computed tomography (CBCT) scans.

## MATERIALS and METHODS

Ethical approval for this study was granted by the Clinical Research Ethics Committee of Istanbul University, Faculty of Dentistry (Date: 30.04.2021, No: 2021/24). CBCT images from patients attending our clinic between December 2015 and October 2019 were reviewed, and only images capturing the sphenoid sinus within the field of view (FOV) were included.

A total of 1466 patients (821 females and 641 males) aged 18 to 94 were retrospectively evaluated using CBCT images. Patients with prior pathologies or surgical procedures in the evaluation site, syndromic conditions, and images marred by image-quality impairing artifacts were excluded. CBCT images, acquired via

a Scanora® 3Dx CBCT device (Soredex, Tuusula, Finland), were analyzed using OnDemand 3D™ software (Cybermed, California, USA) on a medical monitor. Images with a FOV size of 14x16 and a slice thickness of 0.2 mm were evaluated.

Two- and five-year dentomaxillofacial specialists assessed and measured the variables. A senior oral and maxillofacial radiologist with over 30 years of experience made the final determinations. The CBCT images were reviewed in axial, sagittal, and coronal sections. Osteoma presence within the sphenoid sinus, patients' age and gender details, and volumetric measurements were recorded (Figure 1-3). The ITK-SNAP (Penn Image Computing and Science Laboratory) software was employed for osteoma volume measurements.

Statistical analysis entailed using the chi-square test for categorical variable ratios, while the Mann-Whitney U test gauged the correlation between sphenoid osteoma volume and gender. Intra- and inter-examiner reliability was evaluated using Kappa tests. A significance level of  $p < 0.05$  was set.

## RESULTS

This study encompassed 1466 patients (821 females, 645 males) with an average age of  $42.88 \pm 17.704$  (range: 18 to 94). Sphenoid osteomas were identified in 17 patients (1.15%) with an average age of  $32.29 \pm 12.922$  (Range: 20 to 67). The distribution of the patients by gender is outlined in Table 1. No statistically significant difference emerged between osteoma presence and gender ( $p > 0.05$ ).

While single osteomas were observed in 13 patients, four patients presented multiple osteomas (3 osteomas in 2 patients, 2 osteomas in 2 patients). Among these four patients, two were female, and two were male.

The average osteoma volume across the 17 patients was  $183.59 \text{ mm}^3 \pm 168.56$  (range: 9.98 to 552.80, median: 120.10, range: 543). The volumetric analysis based on gender is displayed in

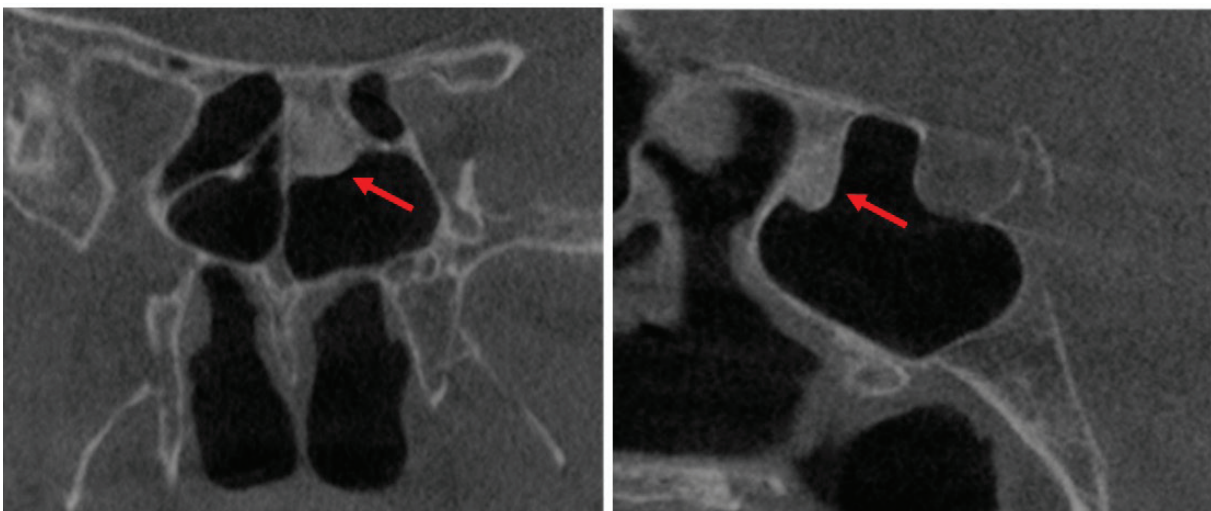
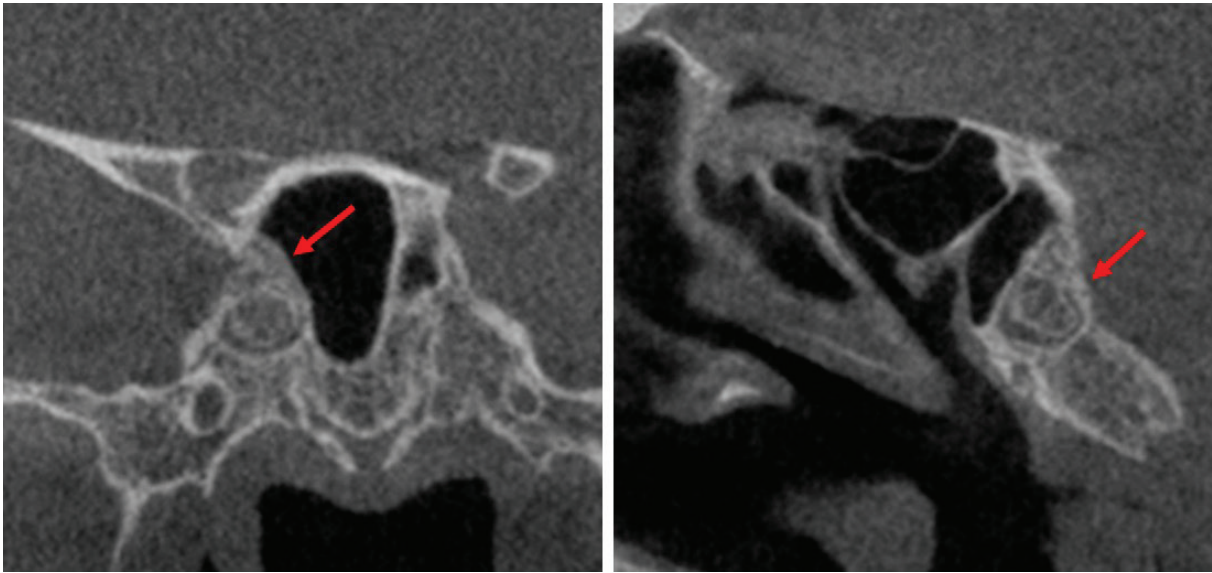
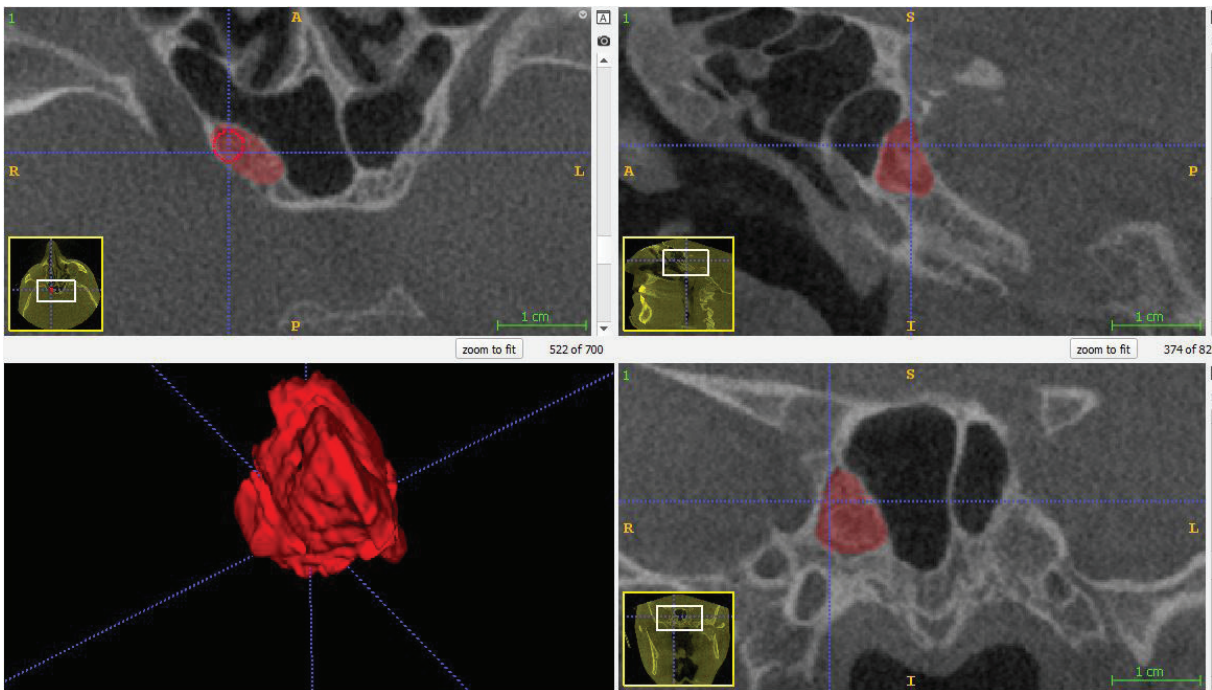


Figure 1: Osteoma located on the left sphenoid sinus



**Figure 2:** Osteoma located on the right sphenoid sinus base



**Figure 3:** Volumetric measurements of the osteoma in Figure 2

Table 2. Mann-Whitney U test results indicated no significant disparity in sphenoid osteoma volumes between males and females ( $U=30.000$ ,  $p=0.564$ ,  $z=-0.577$ ).

Intra- and inter-observer agreement showed strong concordance ranging from 81% to 90%.

## DISCUSSION

The present study unveils a 1.15% occurrence rate for sphenoid sinus osteomas. Additionally, CBCT images of the 17 patients exhibiting radiologically diagnosed sphenoid osteomas were scrutinized. The detected sphenoid osteoma frequency aligns

with reported PNS osteoma prevalence figures; however, specific investigations into sphenoid sinus osteomas remain limited.

The literature reports PNS osteoma prevalence ranging from 0.01% to 3%, signifying their rare nature (1, 3, 9, 10). The exact etiology behind PNS osteomas remains elusive, though they are speculated to result from craniofacial trauma, abnormal embryonic tissue growth, chronic nasal and PNS inflammation, calcification of polyps, metaplasia, calcium metabolism alterations, and heredity (1, 2, 7, 11).

Compact osteomas, also referred to as “ivory” osteomas, consist of fully developed lamellar bone characterized by minimal

**Table 1:** Distribution of osteoma according to gender.

Presence of osteoma	Gender		Total	p value
	Female	Male		
Absent	813	636	1449	0.616*
Present	8	9	17	
Total	821	645	1466	

\*Yates Chi Square Test

**Table 2:** Volumetric analysis of sphenoid sinus osteomas according to gender.

Volume (mm <sup>3</sup> )	Mean±SD [Min-Max]	*p
Male (n=9)	163.96±165.64 [9.99-552.80]	0.564
Female (n=8)	205.67±180.38 [32.02-509.00]	
Total (n=17)	183.59±168.56 [9.99-552.80]	

\*Mann-Whitney U test

marrow spaces and occasional haversian canals, lacking any fibrous structure. Computed Tomography (CT) stands as the preferred imaging technique for investigating osteomas. It effectively identifies their “ivory-like” appearance, facilitating differentiation from other bone disorders and supporting pre-surgical assessments (12-14).

Over the past two decades, CBCT has gained significant traction in diagnosing and planning treatment for craniofacial osteomas. CBCT offers the advantages of requiring lower radiation exposure compared to conventional multi-detector CT scans (MDCT), ensuring precise spatial resolution, and enabling multi-planar reconstructions for comprehensive pre- and post-treatment evaluations (14-19).

While PNS osteomas can emerge at any age, they are more common within the 4th to 6th decades and in males (male-to-female ratio of 1.3:1 to 3.1:1) (1, 6, 7, 10). In our study, 10 out of the 17 patients with sphenoid osteomas were within their third decade. This age divergence might be attributed to the potential detection of even small osteomas using thin CBCT sectioning.

Due to their slow growth patterns, only around 10% of osteomas produce clinical symptoms (11). Among these symptoms, facial pain and headaches rank prominently. Headache frequency varies between 52% and 100% across various osteoma series (6-9). Osteomas can also lead to severe complications like facial deformity, anosmia, diplopia, proptosis, and even vision loss due to pressure exerted on the optic nerve (11, 20).

While osteomas can present as isolated occurrences, they may also be symptomatic components of Gardner syndrome, an autosomal dominant hereditary disorder characterized by osteomas, intestinal polyposis, epidermal cysts, and fibromatosis. Typically, multiple and appearing in the jaw, skull, and long bones, these osteomas can also manifest within the PNS (1, 21, 22). In this study, 23.52% of osteoma patients displayed

multiple osteomas within the sphenoid sinus. Notably, secondary mucocele development has been linked to PNS osteomas. Although slow-growing and often asymptomatic, osteomas can lead to aggressive behavior when concurrent with mucoceles (23, 24).

Radiologically, osteomas present as well-defined, hyperdense masses that are generally round or oval and homogenous (3, 9). Differential diagnoses encompass other bone tumors, fibrous dysplasia, and ossifying fibroma (2, 3). Computed tomography is the diagnostic gold standard, particularly in surgical decision-making. Magnetic resonance imaging aids in differential diagnosis, especially for cases involving intracranial or intra-orbital soft tissue expansion (4, 9). The volumetric analysis of osteomas is clinically significant, and CBCT proves valuable for preoperative assessment (25).

While the treatment approach for PNS osteomas is disputed, asymptomatic small osteomas, particularly in older patients, are typically monitored clinically and radiographically over time. Surgical intervention is advised if certain criteria are met, such as rapid growth (>1 mm/year), size exceeding 50% of the sinus volume, extension into intracranial or intraorbital structures, symptomatic manifestations, bone erosion and facial deformity, chronic sinusitis and mucocele induction (9-11, 26). Surgical objectives center on removing the lesion without harming adjacent structures. Surgical strategies hinge on osteoma location, size, and extent, alongside surgeon expertise (2, 9, 27). Asymptomatic and small osteomas generally do not warrant surgical intervention, yet regular imaging follow-up at 1 to 2 year intervals is recommended to mitigate potential complications (2, 3).

## CONCLUSION

The infrequently encountered sphenoid sinus osteoma holds critical importance in surgical decision-making, with CBCT serving as a vital detection tool. The study reveals a 1.15% osteoma incidence within the sphenoid sinus via CBCT. Utilizing CBCT for volumetric analysis aids in precise surgical planning and improved postoperative clinical-radiological monitoring. The research highlights radiological attributes tied to osteoma volume and underscores the value of CBCT volumetric analysis in crafting treatment strategies for critically affected patients.

**Ethics Committee Approval:** This study was approved by Istanbul University, Faculty of Dentistry (Date: 30.04.2021, No: 2021/24).

**Informed Consent:** Written informed consent was obtained from patients who participated in this study.

**Peer Review:** Externally peer-reviewed.

**Author Contributions:** Conception/Design of Study- S.G., K.O.; Data Acquisition- S.G., H.Ç.K.; Data Analysis/Interpretation- S.G., H.Ç.K., A.F.E.; Drafting Manuscript- S.G., H.Ç.K.; Crit-

ical Revision of Manuscript- S.G., H.Ç.K.; Final Approval and Accountability- S.G.

**Conflict of Interest:** The authors have no conflict of interest to declare.

**Financial Disclosure:** The authors declared that this study has received no financial support.

## REFERENCES

1. Mali S. Paranasal sinus osteoma: review of literature. *Oral Surgery* 2014;7(1):3-11.
2. Keskin IG, İla K, İşeri M, Öztürk M. Paranasal sinüs osteomaları. *Türkiye Klinikleri Tıp Bilimleri Dergisi* 2013;33(5):1250-8.
3. Buyuklu F, Akdoğan MV, Ozer C, Cakmak O. Growth characteristics and clinical manifestations of the paranasal sinus osteomas. *Otolaryngol Head Neck Surg* 2011;145(2):319-23.
4. Chen CY, Ying SH, Yao MS, Chiu WT, Chan WP. Sphenoid sinus osteoma at the sella turcica associated with empty sella: CT and MR imaging findings. *AJNR Am J Neuroradiol* 2008;29(3):550-1.
5. Dzhamaludinov YA, Shakhnazarov G, Dzhamaludinova PY, Gadzhimirzaeva RG, Gadzhimirzaeva RG. [The analysis of 42 observations of paranasal sinus osteoma]. *Vestn Otorinolaringol* 2016;81(5):23-6.
6. Earwaker J. Paranasal sinus osteomas: a review of 46 cases. *Skeletal Radiol* 1993;22(6):417-23.
7. Lee DH, Jung SH, Yoon TM, Lee JK, Joo YE, Lim SC. Characteristics of paranasal sinus osteoma and treatment outcomes. *Acta Otolaryngol* 2015;135(6):602-7.
8. Sinha R, Aggarwal N, Dutta M. Isolated osteoma of the sphenoid sinus. *Acta Otorinolaringol Esp* 2017;68(3):186-7.
9. Chahed H, Hachicha H, Bachraoui R, Marrakchi J, Mediouni A, Zainine R, et al. Paranasal sinus osteomas: diagnosis and treatment. *Rev Stomatol Chir Maxillofac Chir Orale* 2016;117(5):306-10.
10. Arslan HH, Tasli H, Cebeci S, Gerek M. The management of the paranasal sinus osteomas. *J Craniofac Surg* 2017;28(3):741-5.
11. Cokkeser Y, Bayarogullari H, Kahraman SS. Our experience with the surgical management of paranasal sinus osteomas. *Eur Arch Otorhinolaryngol* 2013;270(1):123-8.
12. Bessho K, Murakami K, Iizuka T, Ono T. Osteoma in mandibular condyle. *Int J Oral Maxillofac Surg* 1987;16(3):372-5.
13. Mubeen K, Vijayalakshmi KR, Abhishek PRJJol, Dentistry C. Peripheral ivory osteoma of the mandible in a young female patient. *J Investig Clin Dent* 2012;3(2):148-51.
14. Tarsitano A, Ricotta F, Spinnato P, Chiesa AM, Di Carlo M, Parmeggiani A, et al. Craniofacial osteomas: from diagnosis to therapy. *J Clin Med* 2021;10(23):5584.
15. Pauwels R. Cone beam CT for dental and maxillofacial imaging: dose matters. *Radiat Prot Dosimetry* 2015;165(1-4):156-61.
16. Ludlow JB, Ivanovic M. Endodontology. Comparative dosimetry of dental CBCT devices and 64-slice CT for oral and maxillofacial radiology. *Oral Surg Oral Med Oral Pathol Oral Radiol Endod* 2008;106(1):106-14.
17. Nardi C, Salerno S, Molteni R, Occhipinti M, Grazzini G, Norberti N, et al. Radiation dose in non-dental cone beam CT applications: a systematic review. *Radiol Med* 2018;123:765-77.
18. Yuan XP, Xie BK, Lin XF, Liang BL, Zhang F, Li JT. Value of multi-slice spiral CT with three-dimensional reconstruction in the diagnosis of neoplastic lesions in the jawbones. *Nan Fang Yi Ke Da Xue Xue Bao* 2008;28(9):1700-2.
19. Liang X, Jacobs R, Hassan B, Li L, Pauwels R, Corpas L, et al. A comparative evaluation of cone beam computed tomography (CBCT) and Multi-Slice CT (MSCT) Part I. On subjective image quality. *Eur J Radiol* 2010;75(2):265-9.
20. Nazli Z, Abdul Fattah AW. A rare case of large sphenothmoidal osteoma. *Med J Malaysia* 2017;72(1):60-1.
21. Alexander AA, Patel AA, Odland R. Paranasal sinus osteomas and Gardner's syndrome. *Ann Otol Rhinol Laryngol* 2007;116(9):658-62.
22. Larrea-Oyarbide N, Valmaseda-Castellón E, Berini-Aytés L, Gay-Escoda C. Osteomas of the craniofacial region. Review of 106 cases. *J Oral Pathol Med* 2008;37(1):38-42.
23. Akay KM, Onguru O, Sirin S, Celasun B, Gonul E, Timurkaynak E. Association of paranasal sinus osteoma and intracranial mucocele-two case reports. *Neurol Med Chir (Tokyo)* 2004;44(4):201-4.
24. Sofokleous V, Maragoudakis P, Kyrodimos E, Giotakis E. Management of paranasal sinus osteomas: A comprehensive narrative review of the literature and an up-to-date grading system. *Am J Otolaryngol* 2021;42(5):102644.
25. Lentzen M-P, Riekert M, Grozinger P, Zirk M, Nickenig H-J, Zöllner JE, et al. Anatomical and volumetric analysis of fibro-osseous lesions of the craniofacial skeleton. *J Craniofac Surg* 2021;49(12):1113-8.
26. Çelenk F, Baysal E, Karata ZA, Durucu C, Mumucuş S, Kanlıkama M. Paranasal sinus osteomas. *J Craniofac Surg* 2012;23(5):e433-7.
27. Wolf A, Safran B, Pock J, Tomazic PV, Stammberger H. Surgical treatment of paranasal sinus osteomas: a single center experience of 58 cases. *Laryngoscope*. 2020;130(9):2105-13.