

Sacroileitis Developing in Irregularly Treated Brusellosis

Enes Telli¹([ID](#)) Emsal Aydın¹([ID](#))

¹Giresun Üniversitesi Tıp Fakültesi, Enfeksiyon Hastalıkları ve Klinik Mikrobiyoloji Anabilim dalı, Giresun

Received: 24 August 2023, Accepted: 5 October 2023, Published online: 29 October 2022
© Ordu University Institute of Health Sciences, Turkey, 2023

Abstract

Brucellosis; Fever, also known as corrugated fever, is a zoonotic disease characterized by chills and muscle aches. It can be seen endemic in many countries including our country. Consumption of unpasteurized dairy products is the most common mode of transmission. Diagnosis is made by culture of the organism and increase in antibody titer in serum samples. Complications affecting many systems, mostly osteoarticular, are seen in the disease. In our case, a case of sacroileitis developed as a result of irregular treatment in a patient who was engaged in animal husbandry and was diagnosed with brucellosis is presented. In our case, it was started that osteoarticular involvement could develop under treatment and the importance of regular treatment at correct doses was emphasized.

Keywords: Brucellosis, Complication, Sacroiliitis

Düzensiz Tedavi Edilen Brusellozda Gelişen Sakroileit

Özet

Bruselloz; Ondülan ateş olarak da bilinen ateş, terleme ve kas ağrıları ile seyreden zoonotik bir hastalıktır. Endemik olarak ülkemizin de içinde bulunduğu birçok ülkede görülebilmektedir. Pastörize edilmemiş süt ürünleri tüketimi en sık bulaş yoludur. Tanısı organizmanın kültür ile üretimi ve serum numunelerinde antikor titre artışı ile konulur. Hastalıkta en çok osteoartiküler olmak üzere birçok sistemi etkileyen komplikasyonlar görülür. Olgumuzda hayvancılıkla uğraşan ve brusellozis tanısı alan hastada düzensiz tedavi sonucu gelişen sakroileit vakası sunulmuştur. Olgumuzda osteoartiküler tutulumun tedavi altında da gelişebileceği ifade edilmiş ve doğru dozlarda düzenli tedavinin önemi vurgulanmak istenmiştir.

Anahtar Kelimeler: Bruselloz, Komplikasyon, Sakroileit

Suggested Citation: Telli E, Aydın E. Complicated brucellosis. ODU Med J, 2023;10(3): 153-157.

Copyright@Author(s) - Available online at <https://dergipark.org.tr/pub/odutip>

Content of this journal is licensed under a Creative Commons Attribution-NonCommercial 4.0 International License.



Address for correspondence/reprints:

Enes Telli

E-mail: enestelli1996@gmail.com

Telephone number: +90 (506) 809 19 85

INTRODUCTION

Brucellosis, also known as Undulant Fever, Malta Fever, or Mediterranean Fever, is a zoonotic disease characterized by various clinical symptoms such as fever, sweating, muscle and joint pain. It is endemic in the Mediterranean basin, including Turkey, as well as in the Middle East, Central Asia, sub-Saharan Africa, and some regions of Central and South America (1). *Brucella* spp. non-motile, facultative, intracellular aerobic coccobacilli in structure (2). Four species that cause the disease in humans have been identified. Worldwide, *Brucella melitensis* is the most common cause of the disease (3). The disease is transmitted through the consumption of infected unpasteurized animal products, contact with mucous membranes and secretions from infected animals, and inhalation of infected aerosol particles. The consumption of unpasteurized dairy products is the most common mode of transmission. Diagnosis is made by serological tests based on the culture of the organism from blood, body fluids or tissue and the detection of an increase in *Brucella* antibody titers in serum samples (4). The spread and severity of the infection depend on the balance between the microorganism's virulence and the host's defenses (5). Since *Brucella* resides intracellularly, antibiotics that penetrate cells and are effective in an acidic environment are used in its treatment (6). Complications affecting various

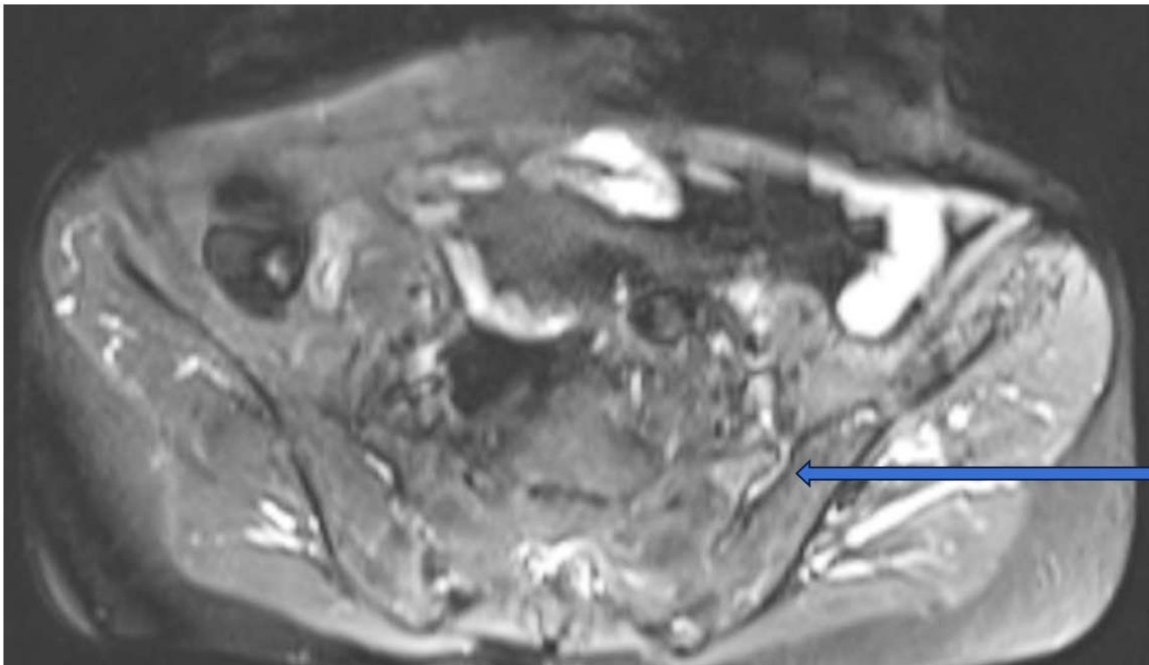
systems can develop in the disease. In this case, a case of sacroiliitis developed under irregular Brucellosis treatment is presented.

CASE REPORT

A 52-year-old female patient with no known comorbidities, who is engaged in animal husbandry, presented to the outpatient clinic with complaints of night sweats, high fever, fatigue, muscle and joint pain lasting for the past 2 weeks. She had no history of consuming unpasteurized milk or dairy products. Initial investigations revealed a white blood cell count of 5000/mm³, neutrophils at 3007/mm³, platelet count of 202.000/mm³, hemoglobin at 12.5 gr/dL, CRP (C-reactive protein) at 32 mg/L (0-5 mg/L), positive *Brucella* agglutination and a positive result at a titer of 1/640 on the standard tube agglutination test for *Brucella*. Blood cultures were obtained from the patient, and she was diagnosed with brucellosis. She was initiated on oral treatment with Doxycycline 2*100 mg and Rifampicin 1*600 mg. On the 14th day of treatment, the patient presented again with persistent muscle and joint pain and the development of lower back pain. Laboratory tests showed a white blood cell count of 5400/mm³, neutrophils at 2930/mm³, CRP of 1.5 mg/L, and an ESR (erythrocyte sedimentation rate) of 15 mm/h (0-20 mm/h). In the blood culture taken at the beginning of the treatment, *Brucella* spp. growth was detected. It was determined that the patient had been using the prescribed treatment

with inadequate dosage and incompleteness. The patient was admitted for further evaluation and supervised treatment to investigate complications. Physical examination revealed tenderness in the left sacroiliac joint. An MRI of the sacroiliac joint confirmed active sacroiliitis on the left side (Figure-1). Gentamicin was added to the patient's treatment regimen at a dose of 5 mg/kg/day, administered parenterally. The

parenteral treatment was completed over 14 days. She was discharged and received outpatient follow-up. Her treatment was continued at an effective dose for a total of 120 days. In her final follow-up visits, there was no evidence of elevated acute-phase reactants, and the patient reported complete resolution of back pain and myalgia. She remained asymptomatic.



Şekil.1. In the STIR sequence, there is an increase in signal intensity in the anterior aspect of the left sacroiliac joint, adjacent to the joint and within the joint space

DISCUSSION

Osteoarticular involvement is the most common complication of brucellosis, occurring in 10% to 85% of patients (7). Magnetic resonance imaging (MRI) and bone scintigraphy are used for diagnosis. The sacroiliac and spinal joints are the most commonly affected regions (7). Sacroiliitis or inflammation of the sacroiliac joint is observed in approximately 80% of

patients with focal complications, more commonly in adults (8). The clinical manifestations of sacroiliitis closely resemble those of acute lower back pain and lumbar disc herniation. Although lower back pain is a significant symptom, a study conducted in Egypt screened 100 brucellosis patients for sacroiliitis using extended rheumatological examination and

imaging methods, revealing asymptomatic sacroiliitis in 24% of patients (9).

Our case underscores the significance of complications that arise due to irregular and incorrect dosing of treatment. However, a review of the literature reveals a noteworthy prevalence of osteoarticular complications in asymptomatic brucellosis cases. This raises the notion of routine complication screening in brucellosis cases, but further research is required to explore this concept thoroughly.

CONCLUSION

Osteoarticular involvement is the most common complication in brucellosis and may require detailed physical examination and imaging. Reporting cases of sacroiliitis that can also have an asymptomatic course further emphasizes the importance of clinical suspicion. Another significant aspect that clinicians should pay particular attention to is the importance of providing regular and accurate dosage of treatment to prevent complications and the treatment from becoming complex.

Ethics Committee Approval: Consent form was obtained from the patient. An informed consent form was signed by the patient/relatives for the case presentation and applied by the Helsinki principles.

Peer-review: Externally peer-reviewed.

Author Contributions: Concept: Design: Literature search: Data Collection and

Processing: Analysis or Interpretation: Written by: ET, EA.

Conflict of Interest: The authors declared no conflict of interest

Financial Disclosure: The authors declared that this study has not received no financial support.

REFERENCES

1. The new global map of human brucellosis. Pappas G, Papadimitriou P, Akritidis N, Christou L, Tsianos EV, Lancet Infect Dis. 2006;6(2):91
2. From the discovery of the Malta fever's agent to the discovery of a marine mammal reservoir, brucellosis has continuously been a reemerging zoonosis, Godfroid J, Cloeckert A, Liautard JP, Kohler S, Fretin D, Walravens K, et al. 2005 May-Jun;36(3):313-26
3. Brucellosis, Pappas G, Akritidis N, Bosilkovski M, Tsianos E, N Engl J Med. 2005;352(22):2325
4. Acute Febrile Illness Caused by Brucella abortus Infection in Humans in Pakistan, Saddique A, Ali S, Akhter S, Khan I, Neubauer H, Melzer F, et al. Int J Environ Res Public Health. 2019;16(21) Epub 2019 Oct 23.
5. Doganay M, Aygen B, Human brucellosis: an overview. Int. J. Infect. Dis. 2003;7:173-182
6. Şimşek S, Göktaş P, Coşkun D. The in vitro effect of some antibiotic combinations

- including Ofloxacin and Ciprofloxacin against *Brucella melitensis*. *Marmara Medical J* 1998; 11 (3):152-5.
7. Osteoarticular manifestations of human brucellosis: A review. Esmailnejad-Ganji SM, Esmailnejad-Ganji SMR, *World J Orthop.* 2019;10(2):54. Epub 2019 Feb 18
 8. Musculoskeletal brucellosis. Arkun R, Mete BD, *Semin Musculoskelet Radiol.* 2011;15:470–479
 9. Gheita TA, Sayed S, Azkalany GS, El Fishawy HS, Aboul-Ezz MA, Shaaban MH, et al. Subclinical sacroiliitis in brucellosis. Clinical presentation and MRI findings. *Z Rheumatol.* 2015;74:240–245.