

■ Research Article

Microsurgical anatomy of the craniovertebral junction: An anatomical study with far lateral approach

Kraniovertebral bileşkenin mikrocerrahi anatomisi: posterolateral yaklaşımla anatomik çalışma

Yahya Efe Guner¹, Emre Yagiz Sayaci*², Emre Bahir Mete³, Ayhan Comert⁴, Umit Eroglu³

¹Department of Neurosurgery, Yuksek Ihtisas University School of Medicine, Ankara, Turkey,

²Department of Neurosurgery, Medicana International Ankara Hospital, Ankara, Turkey,

³Department of Neurosurgery, Ankara University School of Medicine, Ankara, Turkey,

⁴Department of Anatomy, Ankara University School of Medicine, Ankara, Turkey.

Abstract

Aim: The far lateral approach is indicated for lesions located anterior to the dentate ligament between the lower third of the clivus and the upper part of the C2 body. Modified subgroups have also been described for increasing the exposure of level of this highly crowded anatomical region. We present an anatomical and clinical study demonstrating the feasibility of a far lateral approach that provides access to multiple lesions at the craniovertebral junction.

Material and Methods: Four formalin-fixed and mummified adult cadaver specimens were used in this study. Skin incision, followed by careful dissection of various muscle groups, exposed the suboccipital triangle. C1 and C2 posterior arches were removed to reveal the course of the vertebral artery. Finally, suboccipital craniectomy was performed to reach craniovertebral junction and associated regional anatomy was openly exposed.

Results: Numerous anatomical structures that have vast clinical significance provides the delicacy and complexity of this region. Vertebral artery, hypoglossal nerve, spinal accessory nerve, dentate ligaments, first and second cervical neural roots and brainstem were carefully exposed and identified during the dissection process.

Conclusion: Far lateral approach increases the surgical dominance and maneuverability of the pathologies located in craniovertebral junction and upper cervical spine. With this approach, surgical difficulties of the region can be overcome with the development of anatomical knowledge and technical infrastructure. Knowledge of the microtopographic surgical anatomy of this region is the fundamental element to achieve an effective surgery.

Keywords: craniovertebral junction, microsurgery, anatomy, cadaver, far lateral approach

Corresponding Author*: Emre Yağız Sayacı, Department of Neurosurgery, Medicana International Ankara Hospital, Ankara, Turkey.

Orcid: 0000-0002-9397-3834

E-mail: esayaci@gmail.com

Doi: 10.18663/tjcl.1341550

Received: 11.08.2023 accepted: 02.09.2023

Öz

Amaç: Kranioservikal posterolateral yaklaşım, klivusun alt üçte biri ile C2 gövdesinin üst kısmı arasındaki dentat ligamanın önünde yer alan lezyonlar için endikedir. Bu oldukça kalabalık anatomik bölgenin açığa çıkarılma seviyesini artırmak için bu yaklaşım modifiye edilmiş alt grupları da tanımlanmıştır. Bu makalede, kraniovertebral bileşkedeki lezyonlara erişim sağlayan posterolateral yaklaşımın uygulanabilirliğini gösteren anatomik ve klinik bir çalışma sunuyoruz.

Gereç ve Yöntemler: Bu çalışmada formalinle sabitlenmiş ve mumyalanmış dört yetişkin kadavra örneği kullanıldı. Cilt insizyonunu takiben çeşitli kas gruplarının dikkatli diseksiyonu suboksipital üçgeni açığa çıkardı. Vertebral arterin seyrini göstermek için C1 ve C2 arka arkusları çıkarıldı. Son olarak kraniovertebral bileşkeye ulaşmak için suboksipital kraniyektomi yapıldı ve ilişkili bölgesel anatomi açık bir şekilde ortaya kondu.

Bulgular: Geniş klinik öneme sahip çok sayıda anatomik yapı, bu bölgenin hassaslığını ve karmaşıklığını sağlamaktadır. Diseksiyon işlemi sırasında vertebral arter, hipoglossal sinir, spinal aksesuar sinir, dentat ligamanlar, birinci ve ikinci servikal nöral kökler ve beyin sapı dikkatlice açığa çıkarılıp tanımlandı.

Sonuç: Kranioservikal posterolateral yaklaşım, kraniovertebral bileşke ve üst servikal omurgada yer alan patolojilerin cerrahi hakimiyetini ve manevra kabiliyetini artırır. Bu yaklaşımla anatomik bilgi ve teknik altyapının geliştirilmesi ile bölgenin cerrahi zorlukları aşılabılır.

Anahtar Kelimeler: kraniovertebral bileşke, mikrocerrahi, anatomi, kadavra, posterolateral yaklaşım

Introduction

With the description of the unilateral suboccipital approach in 1972, the foundations of the far lateral approach were laid [1]. In 1986, Roberto Heros first described the far lateral approach for vertebral artery (VA) aneurysm and in 1988, George et al. first described this approach for the surgery of lesions located anterior-anterolateral to the foramen magnum (FM) [2, 3]. Today, this approach continues to be used in many modified forms [3-5]. This approach is typically a more lateral approach to the lateral suboccipital approach in which the posterolateral aspect of FM is removed and a C1 (cervical) hemilaminectomy is added, greatly increasing the working space anterior to the brainstem and thus eliminating the need for retraction. Modified subgroups have also been described, including bone resection in the transcondylar, supracondylar or paracondylar region [6, 7]. The far lateral approach is indicated for lesions located anterior to the dentate ligament between the lower third of the clivus and the upper part of the C2 body. Lesions located in the premedullary and lateral cerebellomedullary cistern, including FM meningiomas, neurenteric cysts, aneurysms of the V4 segment of VA, vertebrobasilar junction aneurysms, anterior and lateral medullary segment aneurysms of the posterior inferior cerebellar artery (PICA), schwannomas of the lower cranial nerves, lower brainstem arteriovenous malformations with nidus anterior to the dentate ligament, gliomas and

cavernous hemangiomas affecting the anterolateral aspect of the medulla oblongata and upper cervical cord can be accessed through a far lateral approach [8, 9].

Many different skin incisions have been described in which the myocutaneous flap is elevated in the far lateral approaches. The most commonly used are long curved and hockey stick shaped incisions [2, 3, 5]. One of the most important steps of this procedure is muscle dissection and recognition of triangulation points while maintaining anatomical orientation. The most important structures to be considered from muscle dissection to the end of the procedure, including bone excision, are the suboccipital triangle and VA located there [10]. Many anatomical studies have been conducted to clarify this issue as much as possible [7, 11].

We present an anatomical and clinical study demonstrating the feasibility of a far lateral approach that provides access to multiple lesions at the craniovertebral junction (CVJ) and involves many complex anatomical structures from start to finish.

Material and Methods

Four formalin-fixed and mummified adult cadaver specimens were used in this study. The mean age of these specimens was 73.5 years, ranging from 61 to 83 years. Dissections were performed with the cadavers in prone position. The head was fixed with a Mayfield head holder with the cervical spine in the neutral position.

First transverse skin incision was performed, allowing for the visualization of the bilateral asterion and the highest nuchal line, starting approximately 2 cm superior to the external occipital protuberance. Secondly, a posterior midline skin incision was made starting from the midpoint of this incision and extending to the spinous process of C7. Carefully dissecting the trapezius, sternocleidomastoid, splenius capitis, and semispinalis capitis muscles bilaterally, they were gently displaced laterally to expose the suboccipital triangle, formed by the boundaries of the three muscle groups (Rectus capitis posterior major, superior and inferior oblique capitis muscles). In addition, the rectus capitis posterior minor was identified (Figure 1 A, B). Within the boundaries of the suboccipital triangle, the posterior arch of C1 and VA were visualized (Figure 1 B, C). For ease of the procedure, the rectus capitis posterior major and minor on the working side, along with the inferior oblique capitis muscles, were removed, revealing the posterior atlantooccipital membrane (Figure 1 D, 1E). The close relationship between the bone structures where hemilaminectomy will be performed on C1 and C2, and where suboccipital craniectomy will be applied, was more easily visualized.

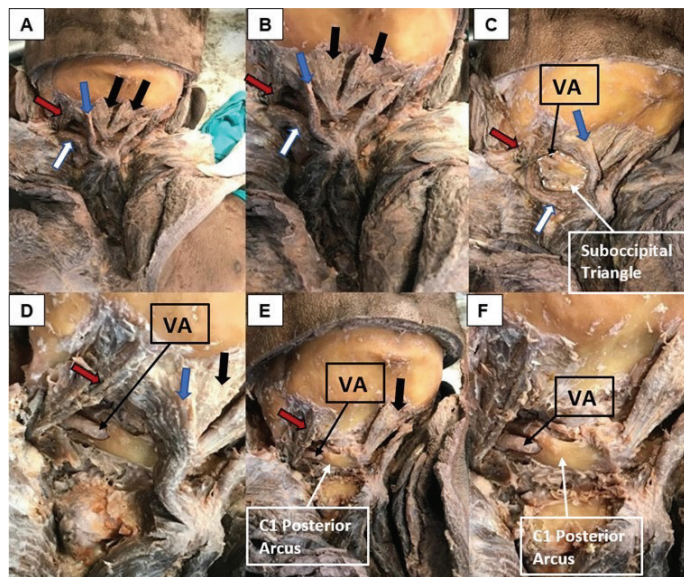


Figure 1: A, B: After the skin incision and dissection of the superficial muscle layer, posterior view, thick black arrow: rectus capitis posterior minor muscle, thick blue arrow: rectus capitis posterior major muscle, thick red arrow: obliquus superior capitis muscle, thick white arrow: obliquus inferior capitis muscle; C, D: Posterior oblique view, area delimited by the white dashed line: Suboccipital Triangle formed by the three muscle groups, thin black arrow: vertebral artery visible in the suboccipital triangle; E, F: After unilateral removal of rectus capitis major/minor and obliquus capitis inferior muscles, posterior oblique view, thin black arrow: vertebral artery, thin white arrow: C1 posterior arch. VA: Vertebral Artery

After thinning the lamina of C2 unilaterally using a high-speed drill, hemilaminectomy of C2 was performed using a Kerrison rongeur-2 mm (Figure 2 A, B, C). Once again, utilizing a drill and Kerrison rongeur, the posterior arch of C1 was removed, taking into consideration the course of VA. The removal of the posterior arch of C1 revealed the course of VA clearly, thereby facilitating the preservation of this structure in the subsequent steps of the procedure (Figure 2 D, E, F, G). After the relevant bone structures of C1 and C2 were removed, a suboccipital craniectomy was performed. The size of this craniectomy could vary based on the characteristics of the present pathology; therefore, an average-sized craniectomy not exceeding 3x3 cm and not crossing the midline was performed. By removing the posterolateral border of the FM, the dural surface of the CVJ was exposed in an open manner (Figure 2 H, I). Subsequently, the dura was opened linearly up to the border of C2 (Figure 2 J, K).

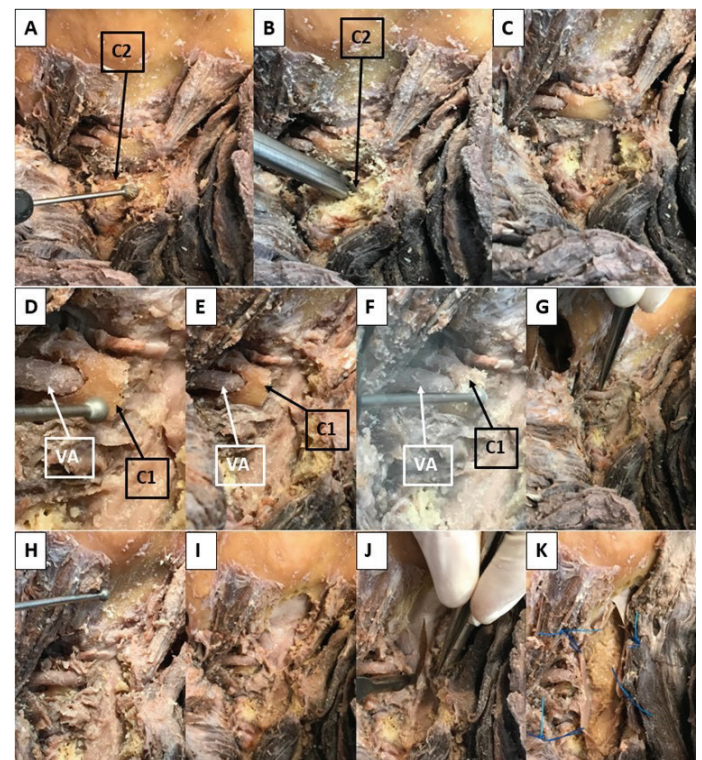


Figure 2: A, B, C: Execution of C2 hemilaminectomy using a drill and Kerrison rongeur; D, E, F, G: Accomplishment of C1 posterior arch removal while preserving the vertebral artery using drill and Kerrison rongeur, and visualization of the vertebral artery; H, I: Performance of suboccipital craniectomy and removal of the posterior-lateral bony border of the foramen magnum; J, K: After the dura is opened linearly up to the border of C2, achieving a broad surgical window. VA: Vertebral Artery

Results

VA is an important anatomical structure to be carefully preserved during this approach. It supplies blood to the brainstem, cerebellum, and parts of the spinal cord. It arises from the subclavian artery, which is a major artery that branches off from the aorta. The course of VA involves several segments. With this study, we had the chance to clearly observe the course of the V2 and V3 segments of VA.

VA originates from the subclavian artery. It runs between the Longus colli and the Scalenus anterior muscles. It passes through the transverse foramina of the C6 in the neck. The artery continues its course and runs vertically upward through the foramina in the transverse processes of the C6 to C2 vertebrae. Within these foramina, the artery is protected by the bony vertebral column. As it ascends through these transverse foramina, it gives off small branches to the muscles and structures in the neck. After passing through the transverse foramen of C1, VA becomes horizontal curving medially and posteriorly behind the superior articular process of C1. Here, it travels within a groove on the posterior aspect of the atlas (C1). This part of VA is more vulnerable to compression or damage due to its close proximity to the cervical vertebrae. Then, it enters the vertebral canal by passing beneath the posterior atlantooccipital membrane. The intracranial part of VA begins with piercing of dura when the artery enters the skull through FM. Inside the skull, after giving rise to ipsilateral PICA's, the two vertebral arteries come together to form the basilar artery, which provides blood supply to the brainstem, cerebellum, and other brain structures.

The suboccipital triangle is composed by the rectus capitis posterior major muscle, above and medially, by the superior oblique muscle above and laterally, and by the inferior oblique muscle below and laterally. It is covered by the semispinalis capitis muscle medially and the splenius capitis muscle laterally. Its floor is formed by the posterior atlantooccipital membrane. Inside the triangle we can find the terminal extradural VA and first and second cervical neural root. In our study, we traced VA and explored the suboccipital triangle step by step and found similar courses as described in the literature.

Eleventh cranial nerve is another critical structure to be exposed during far lateral approach. The accessory nerve, (XI) primarily operates as a motor nerve, controlling specific muscles involved in movements of the head and neck. Its trajectory encompasses two main segments: the cranial and spinal portions.

Cranial Portion (Origin in Brainstem): The accessory nerve's cranial portion originates from a cluster of motor neurons called the nucleus ambiguus. Situated within the from the lateral aspect of the medulla oblongata, this nucleus gives rise to fibers forming the cranial root of the accessory nerve. This root merges with the vagus nerve (cranial nerve X), contributing to motor functions in the pharynx and larynx.

Spinal Portion (Emergence from Spinal Cord): Emerging from upper cervical segments of the spinal cord, specifically from the anterior horn cells of spinal segments C1 to C5/C6, is the spinal portion of the accessory nerve. The spinal root of the accessory nerve takes form from these fibers and exits the skull through the jugular foramen, in partnership with the cranial root.

Once outside the skull, the accessory nerve journeys into the posterior triangle of the neck. Here, it branches to innervate two major muscles: Sternocleidomastoid and Trapezius Muscle. Extracranial course of the accessory nerve is relatively superficial. Hence it is difficult to trace this part. Spinal portion of its origin can be seen within the opened dura.

Condylar approaches give access to hypoglossal canal serving as the exit route of hypoglossal nerve (cranial nerve XII). Condylectomy during transcondylar approach reveals the hypoglossal canal. After exiting the base of the skull through the hypoglossal canal, course of the hypoglossal nerve turns anteriorly alongside carotid sheath descending through the neck.

Opening of spinal dura while reaching ventral FM lesions, exposes thin delicate extensions of the pia mater originating from the nerve roots, attaching to dura mater. These extensions are called dentate, denticulate ligaments. They play significant role in suspension and stabilization the spinal cord in the vertebral canal. In our mummified cadaver specimens, dentate ligaments were not easily observed.

Discussion

CVJ and upper cervical spine pathologies can be challenging for neurosurgeons. Especially anterior dural wall pathologies such as FM meningiomas or schwannomas may be difficult to handle because of the regions anatomical neighboring structures. Vascular and neuronal structures of the area such as VA, accessory nerve, hypoglossal nerve, dentate ligaments, first and second cervical neural roots, and brainstem has to be preserved. On the other hand, any failure on the approach is going to be fatal. This study is focused on the the far lateral suboccipital approach anatomical neighboring structures to be safe, also with a wider approach to ensure precise control on the surgical experience of CVJ pathologies.



Advancements in neurosurgical infrastructure like operative visualization and improved surgical instruments gives the surgeon the chance to look from wider and more dominant angles by providing comfort [12-14]. Wider exposure with hemilaminectomy of C2 and the removal of the posterior arch of C1 (clear visualization and preserving the VA more easily ensured with this step) will provide range of motion to the surgeon on surgical treatment of the region.

It should be kept in mind that 2-3% of anatomical variations of VA in normal population can be found in the far lateral approach to the CVJ [15, 16]. Detection of anomalies and observing the course of VA with preoperative 3-dimensional computerized tomography angiography will be useful to prevent complications.

When this approach is considered in conjunction with the bone tissues removed from the relevant vertebrae and the craniectomy, along with the expanded surgical bone window, and with the appropriate dural incision, it offers a comfortable surgical window opportunity for posterior-posterolateral- anterolateral lesions extending from the lower 1/3 of the clivus to C2, while ensuring the ease of preserving neurovascular structures specific to this region, depending on their size and characteristics.

Conclusion

CVJ and upper cervical spine pathologies can be managed with far lateral approach. This approach increases the surgical dominance and maneuverability of the pathology, which is already in a difficult location. With this approach, surgical difficulties of the region can be overcome with the development of anatomical knowledge and technical infrastructure. Thus, defining the microtopographic surgical anatomy of this region will allow an effective surgery by spreading the range of motion over a wider area in the surgical intervention to be performed.

Conflicts of interest: All authors certify that they have no affiliations with or involvement in any organization or entity with any financial interest (such as honoraria; educational grants; participation in speakers' bureaus; membership, employment, consultancies, stock ownership, or other equity interest; and expert testimony or patent-licensing arrangements), or non-financial interest (such as personal or professional relationships, affiliations, knowledge or beliefs) in the subject matter or materials discussed in this manuscript.

Funding

No funding was received for this research.

Ethical Approval

Conducting scientific studies on cadavers or cadaveric body parts, contribution to education and science is not "human subjects" research and do not require ethical approval. The authors would like to express their sincere gratitude to the donors and their families.

References

1. Hammon WM, Kempe LG. The posterior fossa approach to aneurysms of the vertebral and basilar arteries. *J Neurosurg.* 1972 Sep;37(3):339-47. doi:10.3171/jns.1972.37.3.0339. Cited in: Pubmed; PMID 5069379.
2. Heros RC. Lateral suboccipital approach for vertebral and vertebrobasilar artery lesions. *J Neurosurg.* 1986 Apr;64(4):559-62. doi:10.3171/jns.1986.64.4.0559. Cited in: Pubmed; PMID 3950739.
3. George B, Dematons C, Cophignon J. Lateral approach to the anterior portion of the foramen magnum. Application to surgical removal of 14 benign tumors: technical note. *Surg Neurol.* 1988 Jun;29(6):484-90. doi:10.1016/0090-3019(88)90145-0. Cited in: Pubmed; PMID 3375978.
4. Baldwin HZ, Miller CG, van Loveren HR, Keller JT, Daspt CP, Spetzler RF. The far lateral/combined supra- and infratentorial approach. A human cadaveric prosection model for routes of access to the petroclival region and ventral brain stem. *J Neurosurg.* 1994 Jul;81(1):60-8. doi:10.3171/jns.1994.81.1.0060. Cited in: Pubmed; PMID 8207528.
5. Sen CN, Sekhar LN. Surgical management of anteriorly placed lesions at the craniocervical junction—an alternative approach. *Acta Neurochir (Wien).* 1991;108(1-2):70-7. doi:10.1007/BF01407670. Cited in: Pubmed; PMID 2058431.
6. Luzzi S, Giotta Lucifero A, Bruno N, Baldoncini M, Campero A, Galzio R. Far Lateral Approach. *Acta Biomed.* 2022 Mar 21;92(S4):e2021352. Epub 20220321. doi:10.23750/abm.v92iS4.12823. Cited in: Pubmed; PMID 35441601.
7. Rhoton AL, Jr. The far-lateral approach and its transcondylar, supracondylar, and paracondylar extensions. *Neurosurgery.* 2000 Sep;47(3 Suppl):S195-209. doi:10.1097/00006123-200009001-00020. Cited in: Pubmed; PMID 10983309.
8. Bruneau M, George B. Classification system of foramen magnum meningiomas. *J Craniovertebr Junction Spine.* 2010 Jan;1(1):10-7. Conflict of Interest: None declared. doi:10.4103/0974-8237.65476. Cited in: Pubmed; PMID 20890409.
9. Liu JK, Couldwell WT. Far-lateral transcondylar approach: surgical technique and its application in neurenteric cysts of the cervicomedullary junction. Report of two cases. *Neurosurg Focus.* 2005 Aug 15;19(2):E9. Epub 20050815. doi:10.3171/foc.2005.19.2.10. Cited in: Pubmed; PMID 16122218.

10. Lanzino G, Paolini S, Spetzler RF. Far-lateral approach to the craniocervical junction. *Neurosurgery*. 2005 Oct;57(4 Suppl):367-71; discussion 367-71. doi:10.1227/01.neu.0000176848.05925.80. Cited in: Pubmed; PMID 16234687.
11. Wen HT, Rhoton AL, Jr., Katsuta T, de Oliveira E. Microsurgical anatomy of the transcondylar, supracondylar, and paracondylar extensions of the far-lateral approach. *J Neurosurg*. 1997 Oct;87(4):555-85. doi:10.3171/jns.1997.87.4.0555. Cited in: Pubmed; PMID 9322846.
12. Visocchi M. *New Trends in Craniovertebral Junction Surgery Experimental and Clinical Updates for a New State of Art: Experimental and Clinical Updates for a New State of Art*. 2019. ISBN: 978-3-319-62514-0.
13. Cacciola F, Boszczyk B, Perrini P, Gallina P, Di Lorenzo N. Realignment of Basilar Invagination by C1-C2 Joint Distraction: A Modified Approach to a Paradigm Shift. *Acta Neurochir Suppl*. 2019;125:273-277. eng. doi:10.1007/978-3-319-62515-7_39. Cited in: Pubmed; PMID 30610333.
14. Goel A. Treatment of basilar invagination by atlantoaxial joint distraction and direct lateral mass fixation. *J Neurosurg Spine*. 2004 Oct;1(3):281-6. eng. doi:10.3171/spi.2004.1.3.0281. Cited in: Pubmed; PMID 15478366.
15. Yamazaki M, Koda M, Aramomi MA, Hashimoto M, Masaki Y, Okawa A. Anomalous vertebral artery at the extraosseous and intraosseous regions of the craniovertebral junction: analysis by three-dimensional computed tomography angiography. *Spine (Phila Pa 1976)*. 2005 Nov 1;30(21):2452-7. eng. doi:10.1097/01.brs.0000184306.19870.a8. Cited in: Pubmed; PMID 16261125.
16. Cacciola F, Phalke U, Goel A. Vertebral artery in relationship to C1-C2 vertebrae: an anatomical study. *Neurol India*. 2004 Jun;52(2):178-84. eng. Cited in: Pubmed; PMID 15269464.