

# Hyper-Dominant Left-Circumflex Artery Supplying Left Anterior Descending Artery Territory

Sol Ön Inen Arter Bölgesini Besleyen Hiper-Dominant Sol Sirkümfleks Arter

Süha Çetin<sup>1</sup>, Gülümser Heper<sup>1</sup>, Mustafa Vural<sup>2</sup>

<sup>1</sup> Dept. of Cardiology Okan University Hospital, 34947 Istanbul, Turkey;

<sup>2</sup> Dept. of Cardiology Sakarya University School of Medicine, 54100 Sakarya, Turkey

Correspondence / Yazışma Adresi:

**Süha ÇETİN**

Dept. of Cardiology, Okan University Hospital

Aydınlı Cad. Nr.2 34947 İçmeler -Istanbul/ Turkey

P: :+90 216 444 98 63

E-mail: [ceramos3@gmail.com](mailto:ceramos3@gmail.com)

Geliş Tarihi / Received : **26.04.2017**

Kabul Tarihi / Accepted : **24.05.2017**

## Özet

Bu olgu sunumunda 77 yaşında ST-segman elevasyonu olmayan miyokart enfarktüsü ile değerlendirilen bir bayan hastaya değinilecek. Yapılan koroner anjiyografide proksimal sağ koroner arterde ciddi bir darlık bu duruma neden olan lezyon olarak saptandı. Sol koroner anjiyografide alışılmamışın dışında uzun bir sol sirkümfleks arteri görüldü. Bu damar aynı zamanda sol ön inen koroner arter bölgesinin belirli bir kısmını besliyordu. Amacımız bu çok seyrek görülen konjenital koroner anomaliyi oluşabilecek klinik sonuçlarıyla sunmak ve tartışmaktır. ( *Sakarya Med J* 2017, 7(2):113-116 ).

Anahtar Kelimeler: Koroner arter anomali; hiper-dominant sol sirkümfleks arter; sol ön inen arter

## Abstract

We report an interesting case of a 77-year-old woman who presented with a non-ST-segment-elevation myocardial infarction. Coronary angiogram revealed a critical stenosis of the proximal right coronary artery as the culprit lesion. Left coronary angiography showed an extraordinarily long vessel supplying left circumflex and partly left anterior descending artery territory. We aimed to present and discuss this very rare congenital coronary abnormality and its possible clinical consequences. ( *Sakarya Tıp Dergisi* 2017, 7(2):113-116 )

Keywords: Coronary artery anomaly; hyper-dominant left circumflex artery; left anterior descending artery

## Introduction

Coronary artery anomalies (CA) are defined in accordance with their origin, course, and termination<sup>1</sup>. Herein, we describe the case of a patient who in the diagnostic coronary angiography showed an extremely seldom anomaly of the left coronary artery system in terms of remarkably developed long vessel supplying left-circumflex (LCX) and partly left anterior descending (LAD) artery territory of the myocardium. Further, this unusual coronary pattern may have dangerous clinical implications.

## Case Report

A 77-year-old woman was admitted to our hospital's emergency department due to sudden beginning of a sharp retrosternal pain one hour before admission in May 2015. Chest pain was diagnosed as typical angina on the basis of its location and characteristics. Past medical history is consistent with hypertension and hyperlipidemia. She had shortness of breath and chest pain with marked limitation of ordinary physical activation for the last few months. High blood pressure was diagnosed during admittance (160/90 mmHg) while the rest of her vital signs were considered as normal. A 12-lead electrocardiogram revealed ST and T-wave abnormalities in leads II, V4-6 (Fig. 1).

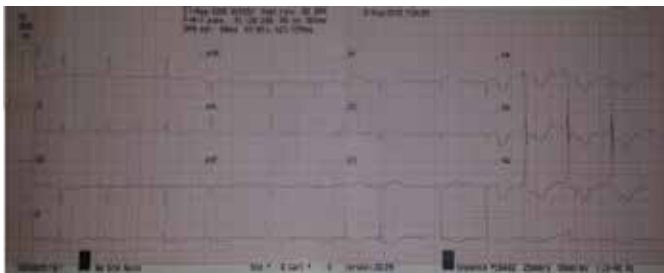


Figure 1: 12-lead electrocardiogram showing ST and T-wave abnormalities in leads II and V<sup>4-6</sup>.

Chest x-ray was unremarkable. Her laboratory findings in terms of cardiac markers were positive. Her symptoms were immediately relieved by administration of antianginal medication according to American Heart Association Acute Coronary Syndrome guidelines<sup>2</sup>. She was diagnosed with non-ST-elevation myocardial infarction and was referred to the cath-lab. Coronary angiography revealed a significant stenosis of the proximal RCA segment as the

culprit lesion (Fig. 2).

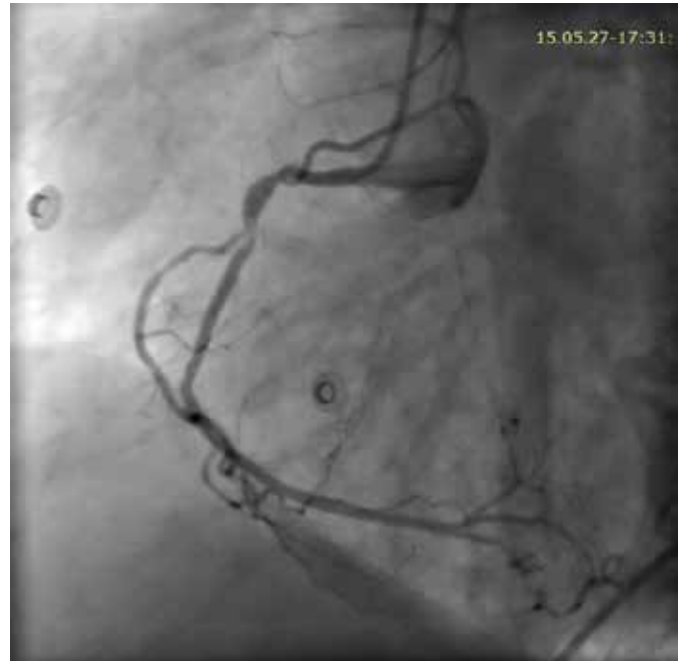

Figure 2: Right selective coronary angiography with left anterior oblique projection showing proximal severe right coronary artery stenosis.

Left coronary artery angiogram demonstrated an extraordinarily long serpentine vessel supplying LCX artery territory and the apex, which is normally supplied by the LAD (Fig. 3, 4). LAD was diagnosed as a totally occluded rudimentary vessel taking collaterals from the hyper-dominant LCX and the intermediate artery (Fig. 4).

## Discussion

The incidence of CA ranges from 0.6% to 1.3%<sup>3</sup>. These CA vary with respect to number, location, orientation of the ostia and origin of the coronary arteries<sup>4</sup>. Some anomalies are merely anatomic variants without clinical relevance; others can present with chest pain, syncope, or sudden cardiac death<sup>5</sup>. Our case is very original due to the left coronary angiography revealing an extraordinarily long vessel supplying LCX territory as well as the apex, which is usually supplied by the LAD. Different angulations like left lateral view or LAO caudal view showed totally occluded rudimentary LAD taking collaterals from the hyper-dominant LCX and the intermediate artery. Normally CA are best diagnosed using computed tomography (CT) angiogram, which gives three-dimensional infor-

mation of the origin as well as the course of coronary arteries. But in the present case, a CT angiogram was refused by the patient.

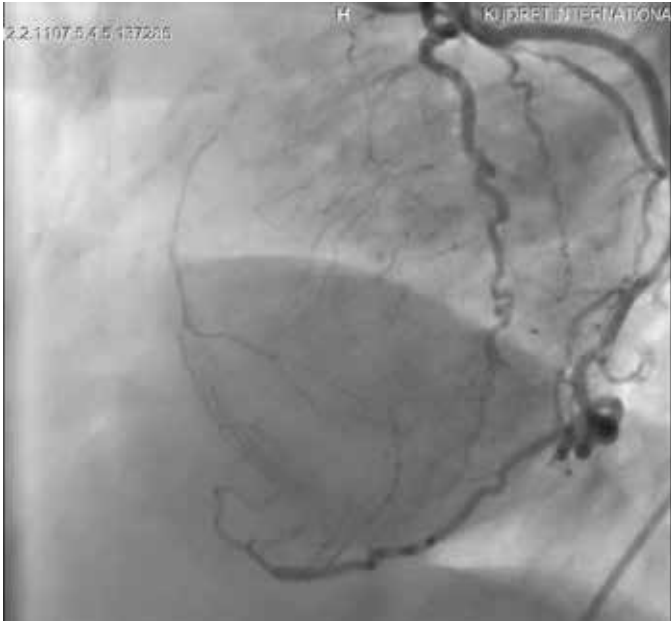

Figure 3: Left selective coronary angiography (10° right anterior oblique view with 19° caudal angulation): Hyper-dominant serpentine left circumflex artery.

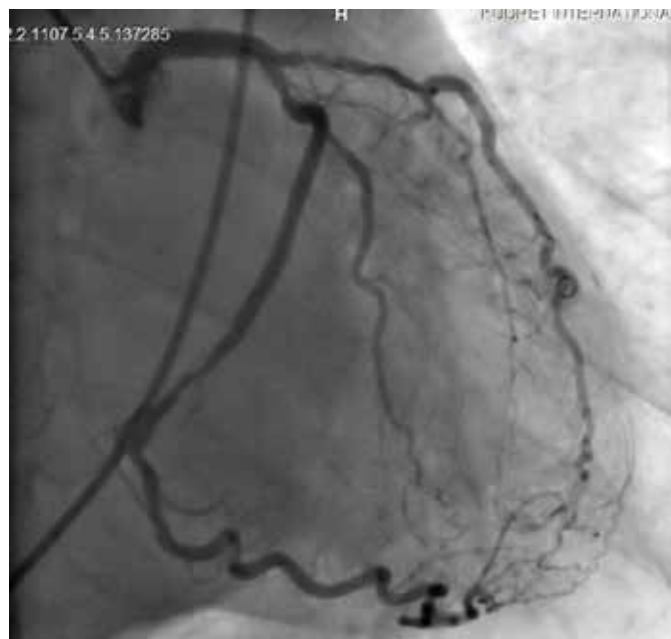

Figure 4: Left selective coronary angiography in left lateral view: Left circumflex artery wrapping around the apex and supplying left anterior descending artery territory.

A hyper-dominant LCX artery wrapping around the apex and supplying LAD territory is a very seldom diagnosed occurrence. CA in terms of a hyper-dominant vessel leads to an increased dependence of the myocardium on this artery. Therefore the stenosis or occlusion of this vessel may have deleterious consequences.

# References

1. Popma JJ. Coronary angiography. In: Bonow RO, Mann DL, Zipes DP, Libby P, editors. Braunwald's heart disease: a textbook of cardiovascular medicine. 9th ed. Washington: Elsevier Saunders; 2012. p. 406-440.
2. Braunwald E, Antman EM, Beasley JW, Califf RM, Cheitlin MD, Hochman JS, et al. ACC/AHA guidelines for the management of patients with unstable angina and non-ST-segment elevation myocardial infarction: executive summary and recommendations. A report of the American College of Cardiology/American Heart Association task force on practice guidelines (committee on management of patients with unstable angina). *Circulation* 2000; 102(10): 1193-209.
3. Yamanaka O, Hobbs RE. Coronary artery anomalies in 126,595 patients undergoing coronary angiography. *Cathet Cardiovasc Diagn* 1990; 21(1): 28-40.
4. Chadha S, Husain SI, Shetty V, Hollander G, Frankel R, Shani J. Anomalous origin of the left main coronary artery from right sinus of valsalva. *Tex Heart Inst J* 2014; 41(5): 558-9.
5. Angelini P. Coronary artery anomalies—current clinical issues: definitions, classifications, incidence, clinical relevance, and treatment guidelines. *Tex Heart Inst J* 2002; 29(4): 271-8.

