




CASE REPORT

Pityriasis Rosea-like Drug Eruption Due to Isotretinoin

Isotretinoine Bağlı Gelişen Pitriasis Rosea Benzeri İlaç Döküntüsü

¹Cahit Yavuz , ¹Büşra Taşkın , ¹Fatma Tunçez Akyürek , ¹Gülcan Saylam Kurtipek 

¹Selcuk University, Faculty of Medicine, Department of Dermatology and Venereology, Konya, Türkiye

Correspondence

Cahit Yavuz, Selcuk University, Faculty of Medicine, Department of Dermatology and Venereology, Konya, Türkiye

E-Mail: yavuzcahit@yahoo.com

NOTE: Accepted as e-poster for 31st National Dermatology Congress, 18-22 October 2023, Antalya, Türkiye

How to cite ?

Yavuz C, Taşkın B, Tuncez Akyurek F, Saylam Kurtipek G. Pityriasis Rosea-like Drug Eruption Due to Isotretinoin. Genel Tıp Derg. 2024;34(3):413-5.

ABSTRACT

Healthcare professionals often encounter the challenge of drug-induced skin eruptions in their daily practice. Typically, dermatologists are tasked with diagnosing these conditions, which can vary from common rashes to specific dermatoses. Our report highlights two patients who experienced a pityriasis rosea-like eruption due to systemic isotretinoin treatment for acne vulgaris

Keywords: Pityriasis rosea, Isotretinoin, Eruption

ÖZ

İlaçla ilişkili deri döküntüleri dermatoloji pratiğinde sık görülmektedir. Bu durumların tanısı diğer uzmanlık alanı çalışanları için zorlayıcı olabildiği için çoğunlukla dermatoloji hekimlerinin alanına girmektedir. Sık görülen makülopapüler ilaç döküntüleri dışında spesifik dermatozların benzeri durumlarda görülebilmektedir. Kliniğimizde akne vulgaris tanısıyla sistemik isotretinoin tedavisi alırken pityriasis rosea benzeri döküntüsü gelişen iki hastayı bildirmek istiyoruz.

Anahtar Kelimeler: Pitriasis Rosea, İso-tretinoin, Döküntü

Introduction

Skin eruptions caused by medications are commonly observed in daily medical practice. The diagnosis of such conditions is often based on intuition and guesswork, but in a certain group of patients, a definite conclusion can be made through drug-related tests and evaluations. It is important to note that some drug-induced skin eruptions can resemble common skin diseases, making accurate diagnosis challenging (1).

Pityriasis rosea (P.rosea) is a common, acute-onset disease; have not a clearly known etiology. Many cases of drug-induced P.rosea have been reported. In drug-induced P.rosea cases, failure to recognize and timely discontinue the potentially responsible drug may lead to prolonged course and difficulties in treatment.

We would like to report 2 cases presenting as P.rosea which we thought to be eruption induced by isotretinoin.

Case-1

A 14-year-old female patient admitted to our outpatient clinic with the complaint of pruritic rashes. In her anamnesis, it was learned that the rashes started 5 days ago and increased over time.

Dermatologic examination revealed erythematous, collar-like squamous macules and plaques especially on the neck, anterior and posterior aspect of the trunk, flexor aspects of the upper extremities and thighs. (Figure-1a) Oral mucosa and nails were normal. It was determined that the patient had not had any recent infection and had no additional systemic disease. When drug use was questioned, it was found that she had been receiving systemic isotretinoin treatment at a dose of 20 mg/day for 5 months with a diagnosis the acne vulgaris. Laboratory tests revealed normal active inflammation markers and no additional features. The patient was diagnosed as P.rosea-like isotretinoin rash with clinical findings and systemic isotretinoin treatment was discontinued and systemic steroid treatment was started. On the 10th day examination, it was observed that the lesions regressed almost completely (Figure-1b). Verbal consent was granted from patient for his report.

Case-2

A 20-year-old woman was admitted to our outpatient clinic with complaints of pruritus and rash. In her anamnesis, it was stated that the rashes started 2 days ago. Dermatologic examination revealed the presence of some collar-like squamous plaque lesions

Table-1. Drugs reported to cause Pytriasis rosea-like rash

Domperidone	Ondansetron	Bismuth	Omeprazole
Imatinib	Nortriptyline	Clozapine	Ergotamine
Ibrutinib	Bupropion	Metronidazole	Acetyl salicylic acid - Codeine
Asenapine	Rituximab	Lithium	Pristinamycin
Isotretinoin	Terbinafine	Benfluorex	Captopril
Atenolol	Lamotrigine	Infliximab	BCG immunotherapy
Vaccines (Covid19, tbc, pneumococcal, hepatitis etc.)			

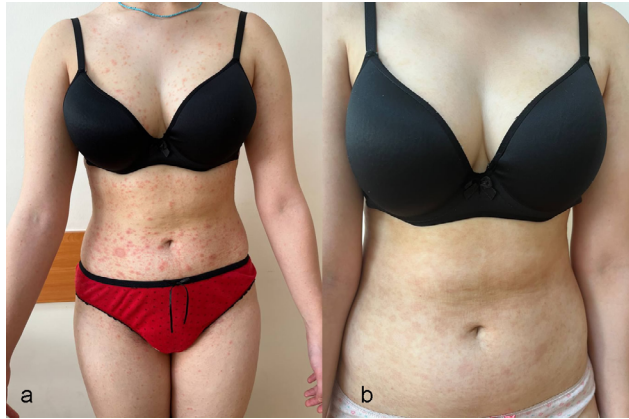

Figure 1:

located on the abdominal wall and pubis. (Figure-2) Oral mucosa and nails were normal. It was reported that she had no recent infection and no additional systemic disease. Laboratory tests were unremarkable. In the medication history, it was found that the patient had been receiving systemic isotretinoin treatment at a dose of 20 mg/day for acne vulgaris for 4 months. Biopsy was taken from the patient before treatment. Histopathologic examination revealed intermittent parakeratosis, orthokeratosis and subacute spongiotic dermatitis. The patient was diagnosed as P.rosea-like isotretinoin rash and systemic isotretinoin treatment was discontinued and systemic steroid treatment was started. The lesions regressed within 1 week. Histopathologic examination was interpreted as nonspecific dermatitis. Verbal consent was granted from patient for his report.

Systemic isotretinoin treatments was discontinued and not restarted in both patients after eruption resolved.

Discussion

As the skin is a common target for drug reactions, dermatologists have a critical role in recognizing and managing drug reactions. Drug reactions may present with unique clinical pictures or they can also be seen mimicking common skin diseases.

P.rosea is one of the common skin diseases. Its incidence is between 0.5-2% and it is frequently observed in the 15-30 age group (2). It is characterized by erythematous squamous plaques with an exanthematous appearance. The distinctive features are that the squames are in the shape of a collar and the first lesion to appear is in the shape of a medallion (Herald patch). Although the etiology is not known with certainty, viral infections, autoimmunity, psychogenic factors, and drugs are among the causes

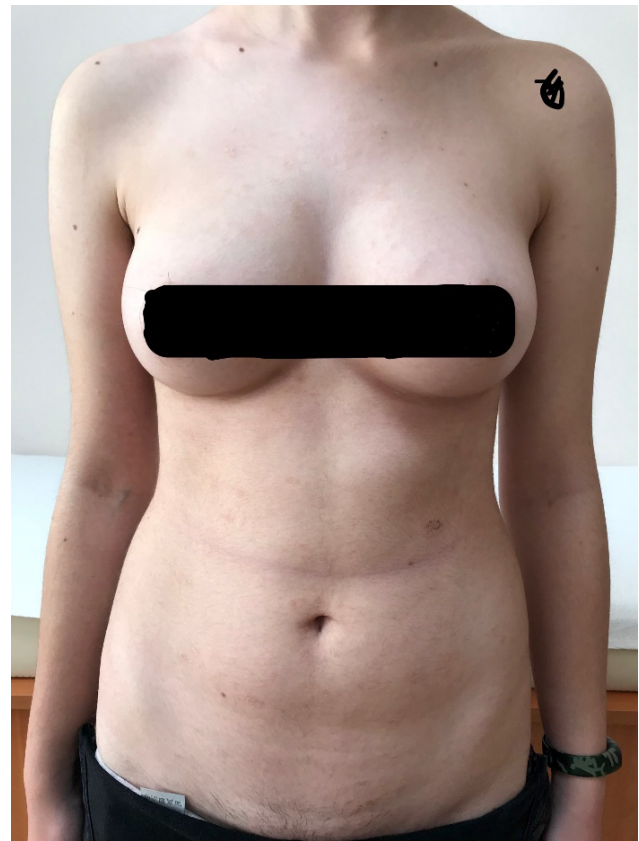

Figure 2:

(3). Endogenous reactivation of human herpes virus 6 and 7 (HHV-6, HHV-7) is one of the factors blamed in the etiology (4). Prodromal symptoms, including headache, malaise, and fever may be observed in some patients. There are many drug-induced P.rosea case reports in the literature. These drugs include atenolol, bismuth, gold salts, clozapine, omeprazole and isotretinoin (Table-1).

There are some clues that can be used to differentiate P.rosea cases thought to develop due to drugs from idiopathic P.rosea;

- Lack of Herald patch
- The color of the lesions is more vivid and prominent
- Itching is severe and does not respond to antihistamines
- Increased eosinophil infiltration in the skin
- Absence of prodromal symptoms such as headache and fatigue
- Lesions regress in a shorter time than classic P.rosea (1,5,6)

Herald patches were absent in two of our cases, the clinical presentation was characterized by multiple plaques with vivid erythematous plaques in the first case and more limited lesions in the second case. Pruritus was the major symptom in both cases. Histopathologic examination was not performed

in the first case because of the typical clinical appearance, whereas histopathologic examination of the second case revealed intermittent parakeratosis, orthokeratosis and subacute spongiotic dermatitis.

Isotretinoin is an agent used in the treatment of moderate to severe acne vulgaris. Although many mucocutaneous and systemic side effects are known, P.rosea-like drug rash has been reported in isolated case reports. Isotretinoin received FDA approval in 1982 and was first reported to cause P.rosea-like rash by Helfman et al. in 1984 (7). The second case report in the literature was made by Gürel et al. in 2018. According to our estimation, our cases will be the third report in the literature.

In our two cases, rash developed while receiving systemic isotretinoin treatment. In the first case, the rash was observed in the fifth month of treatment, while in the second case, the rash appeared in the sixth month of treatment.

The cause and mechanism of P.rosea-like drug eruption is not clearly known. Melnik suggests that the use of isotretinoin induces apoptosis and it can be play a role to develop P.rosea like rash. (8)

The rate of drug reactions with P.rosea-like rash is not clearly known. The fact that it shows differences compared to the classical form and the presence of a drug history are helpful in making the diagnosis. Drago et al. reported that the lesions of 12 patients who were thought to have P.rosea-like drug eruption regressed within 2 weeks after discontinuation of the suspected drugs, which is shorter than 6 weeks, the recovery period of classical P.rosea (9). Similar rapid regression was also observed by Drago et al. in patients with vaccine-associated P.rosea, and the duration of regression of lesions in patients with vaccine-associated P.rosea was observed as 2 weeks (6).

The age range in which classical P.rosea is frequently observed is between 15-30 years while the age range of P.rosea cases thought to develop drug-induced is mostly over 30 years. The increased likelihood of systemic diseases after the third decade and the increase in the rate of drug use are considered to be the reasons for this age difference (6).

Prodromal symptoms such as headache, malaise and fever, which can be observed in patients with classical P.rosea, are not observed in patients with P.rosea thought to develop drug-related. Two of our patients stated that they had no symptoms before the lesion emergence.

In conclusion, dermatologists should be knowledgeable about drug reactions. Controlled prospective studies are needed to understand better and define drug-induced P.rosea.

References

1. Atzori L, Pinna AL, Ferrelli C, Aste N. Pityriasis rosea-like adverse reaction: review of the literature and experience of an Italian drug-surveillance center. *Dermatol Online J.* 2006;12:1.
2. Zavar V, Jerajani H, Pol R. Current trends in pityriasis rosea. *Expert Rev Dermatol* 2010;5:325-33.
3. Mahajan K, Relhan V, Relhan AK, Garg VK. Pityriasis rosea: an update on etiopathogenesis and management of difficult aspects. *Indian J Dermatol* 2016;61:375-84.
4. Broccolo F, Drago F, Careddu AM, et al. Additional evidence that pityriasis rosea is associated with reactivation of human herpesvirus-6 and-7. *J Invest Dermatol* 2005; 124: 1234-1240
5. Saad S, Gammoudi R, Abdessayed N, Denguezli M. Domperidone-induced pityriasis rosea-like drug eruption. *Clin Case Rep.* 2022;10:e05674.
6. Drago F, Ciccarese G, Javor S, Parodi A. Vaccine-induced pityriasis rosea and pityriasis rosea-like eruptions: a review of the literature. *J Eur Acad Dermatol Venereol.* 2016;30:544-5.
7. Helfman RJ, Brickman M, Fahey J. Isotretinoin dermatitis simulating acute pityriasis rosea. *Cutis.* 1984;33:297-300.
8. Gürel G, Şahin S, Çölgeçen E. Pityriasis rosea-like eruption induced by isotretinoin. *Cutan Ocul Toxicol.* 2018;37:100-102.
9. Drago F, Broccolo F, Agnoletti A, et al. Pityriasis rosea and pityriasis rosea-like eruptions. *J Am Acad Dermatol* 2014;70:196.