



## Comparison of Ectoparasites Infestation for Fresh and Saltwater Fishes from Euphrates, and Razzaza Lake, Iraq

Marva JAWAD<sup>1</sup>, Firas ALALI<sup>2</sup>, Mohammed B. Shaheed AL-KHATEEB<sup>2</sup>, Asaad Sh. ALHESNAWI<sup>2</sup>

<sup>1</sup>University of Kerbala/ College of Sciences/Department of Biology, Karbala, Iraq.

<sup>2</sup>University of Kerbala /College of Veterinary Medicine/Department of Veterinary Microbiology and Parasitology, Karbala, Iraq

<sup>3</sup>University of Kerbala/ College of Sciences/Department of Biology, Karbala, Iraq.

<sup>4</sup>University of Kerbala/College of Applied Medical Sciences, Karbala, Iraq.

◆ Geliş Tarihi/Received: 17.10.2023

◆ Kabul Tarihi/Accepted: 22.11.2023

◆ Yayın Tarihi/Published: 29.12.2023

**Bu makaleye atıfta bulunmak için/To cite this article:**

Jawad M, Alali F, Al- Khateeb MBS, Alhesnawi AS. Comparison of Ectoparasites infestation.n for fresh and saltwater Fishes from Euphrates, and Razzaza Lake, Iraq. Bozok Vet Sci (2023) 4, (2):45-50.

**Abstract:** Parasitic infestations represent one of the main challenges to freshwater and marine fish in all areas of the world. The infections are commonly found on the skin and gills of fish and can cause dangerous problems, as mortality, in heavily parasitized infections. This study was conducted to detect of ectoparasite types in fishes, 200 of *Coptodon zillii* from Euphrates and 120 *Cyprinus carpio* from Razzaza Lake, was used for this studying aquatic environment. The samples were obtained from the market by purchasing fish caught using gill nets in different periods in 2022-2023. After the macroscopic examination of the fish brought to the laboratory alive, native preparations prepared from the skin, gills and eyes were examined under a light microscope. The results of the both infected fishes revealed the presence of several clinical signs. The prevalence was 65.6%, in *Coptodon zillii* was 60% and *Cyprinus carpio* was 100%. Indeed, we observed the appearance of necrotic areas, ulcerations and hemorrhage on the gills. On other body parts, we found protozoan and monogenean parasites. The identification of ectoparasite was obtained in fins, skin, and gills and no infection in the eyes. *Coptodon zillii* were infected with 4 types of ectoparasites, *Trichodina* spp., *Ichthyophthirius multifiliis* spp., *Dactylogyrus* spp., and *Gyrodactylus* spp. *Cyprinus carpio* was infected by 2 types of parasites, *I. multifiliis* and *Gyrodactylus* spp. significant of results at  $P \leq 0.05$  of fish type with weight and long but not significant for genders in both types. In future studies should be focusing on modern tools to the identification of parasite species in different environments.

**Keywords:** Ectoparasites, Euphrates river, Iraq, Razzaza Lake.

## Irak'taki Fırat Nehri ve Razzaza Gölü'ndeki Tatlı ve Tuzlu Su Balıklarında Ektoparazit Enfestasyonlarının Karşılaştırılması

**Özet:** Parazit istilaları, dünyanın her yerinde tatlı su ve deniz balıkları için ana zorluklardan birini temsil etmektedir. Enfeksiyonlar genellikle balıkların derisinde ve solungaçlarında bulunur ve parazitlerin yoğun olduğu enfeksiyonlarda ölüm gibi tehlikeli sorunlara neden olabilir. Balıklarda ektoparazit türlerinin tespiti amacıyla yürütülen bu çalışmada, su ortamındaki çalışma için Fırat Nehri'nden 200 adet *Coptodon zillii* ve Razzaza Gölü'nden 120 adet *Cyprinus carpio* kullanıldı. Örnekler 2022-2023 yılında farklı dönemlerde solungaç ağları kullanılarak yakalanmış balıklar piyasadan satın alınma yoluyla ve temin edildi. Canlı olarak laboratuvara getirilen balıkların, makroskopik incelemeleri yapıldıktan sonra deri, solungaçlar ve gözlerden hazırlanan natif preparatlar ışık mikroskopunda incelendi. Her iki balıkta da enfeksiyonla ilişkili çeşitli klinik belirtilerin varlığı ortaya konuldu. Prevalans %65,6, *Coptodon zillii* 'de %60 ve *Cyprinus carpio* 'da %100 olarak tespit edildi. Gerçekten de solungaçlarda nekrotik alanların, ülserasyonların ve kanamaların ortaya çıktığını gözlemledik. Diğer vücut kısımlarında tek hücreli ve monojen parazitler bulduk. Ektoparazitlerin tanımlanması yüzgeçlerde, deride ve solungaçlarda yapıldı ve gözlerde enfeksiyon görülmedi. *Coptodon zillii* 'yi enfekte eden 4 tip ektoparazit vardı: *Trichodina* spp., *Ichthyophthirius multifiliis* spp., *Dactylogyrus* spp. ve *Gyrodactylus* spp. *Cyprinus carpio*, *I. multifiliis* ve *Gyrodactylus* spp. olmak üzere 2 tür parazitte enfekte oldu. Balık tipinin ağırlığı ve uzunluğu açısından  $P \leq 0.05$ 'teki sonuçlar anlamlıdır ancak her iki türde de cinsiyetler için anlamlı değildir. Gelecek çalışmalarda farklı ortamlardaki parazit türlerinin tanımlanmasına yönelik modern araçlara odaklanılmalıdır.

**Anahtar Kelimeler:** Ektoparazitler, Fırat nehri, Irak, Razzaza gölü

### 1. Introduction

Fish inhabit the majority of aquatic habitats globally. Fish are the most species-rich group of vertebrates on Earth and inhabit the majority of aquatic habitats globally. They are one of the key sources of proteins for human consumption and

fisheries through aquaculture represent an important part of food security (1). Diseases in fish, especially those caused by parasites, can cause a decrease in the quality of fish and health problems in humans (2). Ectoparasites are widely recognized as valuable indicators of environmental quality due to their monoxenic life cycle characterized by rapid reproduction

rates, enabling them to promptly respond to changes in aquatic biota (3).

Ectoparasite infection in fish is generally considered to be less detrimental compared to losses resulting from infections caused by other pathogens, such as viruses and bacteria. However, it is important to note that ectoparasite infection may contribute to secondary assaults, which in turn may lead to the development of viral and bacterial illnesses (4). *Ichthyophthirius multifiliis* Fouquet, 1876 is an important parasitic ciliate that infects gills, skin and fins of freshwater fish causing the so-called “white spot disease”. *I. multifiliis* was found to infect more than 190 freshwater fish and distributed in 26 countries. However, the epizootic occurrence of *Ichthyophthiriasis* in high plateau, Tibet, China by (5) which infecting an indigenous and endangered fish, *Schizothorax macropogon*, by reducing the breathing capacity and promoting secondary bacterial or viral infections (6), as an important feature, *I. multifiliis* is characterized by low host specificity and broad geographical distribution (7). *Ichthyophthiriasis* in common carp (*Cyprinus carpio*) from Tigris River has heavy infection was (35%) and mortality reached more than (40%) of 10000 farmed fishes in Baghdad city, Iraq. The wet smear discovered high number of *I. multifiliis* in skin and gills (8).

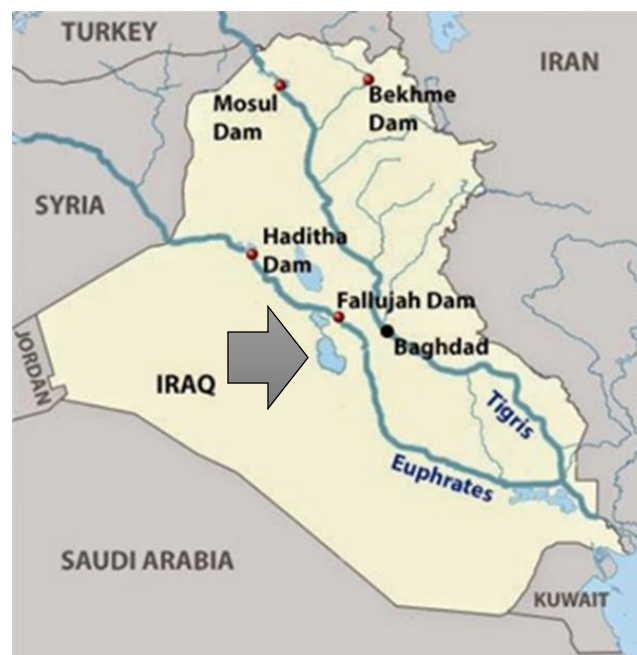Trichodinids are probably the most commonly encountered protozoan parasites on fishes in marine and freshwater environments. They are typically found on the gills, skin and fins of fish with more than 200 species described from trichodinid species. Trichodinids are best known as ectoparasites of skin, fin and gill of the fish with most of the species reported from freshwater environments (9). To date, about 400 Trichodina species have been found on various aquatic animals worldwide in a range of habitats including freshwater, brackish water, and marine environments (10). In Iraq, the first gyrodactylid species was known principally from early work by in which they reported *Gyrodactylus elegans* on the gills of *Cyprinus carpio* and *Planiliza abu* (reported as *Liza abu*) (11). The parasite *Gyrodactylus* has the ability to pose a hazard to its host by inducing damage to the epithelial cells via the process of attachment. The primary source of injury arises from the introduction of marginal hooks and median hooks into the epidermis, in addition to the feeding behaviors shown by the worm. Furthermore, it is possible for the host to develop secondary bacterial infections as a result of these activities (12). The *Dactylogyridae* family consists of highly specialized monogenean ectoparasites that exhibit a strong preference for certain hosts (13). Monogenean parasites *Dactylogyrus* are ectoparasites living on the gills, present the largest group of fish parasites and major importance in the pathology of fishes (14). This research aims to identify and confirmed infection on ectoparasites parasitizing *C. zillii* and *C. carpio* fishes from Euphrates, and Razzaza Lake, Iraq.

## 2. Materials and Methods

### 2.1. Study Area and Sampling

The majority of the Euphrates basin is situated within the territories of Türkiye, Syria, and Iraq. To begin with, it is noteworthy that the Euphrates River receives contributions from three distinct tributaries, namely the Khabur, the Balikh, and the Sajur Upon its entry into Iraq, the Euphrates River flows towards the southern region of the country, ultimately leading to the Gulf. The Euphrates River spans a distance of about 3,000 kilometers, extending from the Murat River's source to its confluence with the Tigris River. This location may be identified between the geographical coordinates of 31° to 18° north latitude and 47° to 26° east longitude.

The study material consisted of a total of 320 fish, including 200 *C. zillii* from the Euphrates and 120 *C. carpio* from Razzaza Lake using the gill net collection technique. Fish specimens were gathered over the period spanning from December 2022 to the conclusion of April 2023. Fish were immediately transported alive to the laboratory and then subjected to examination, Figure 1 .



**Figure 1.** A map of Iraq has the sites of the study. The pointer site of study.

After the macroscopic examination of the fish samples was carried out in the laboratory, the wet part of the fins, skin, gills and eyes were used for microscopic examination. (6). Each organ was separated using a scissor and put it in Petridis with distal water. Then examine each organ and confirmed infection if found. Then take scrap from different sites of skin. The eyes were examined after separation from fish and opened by a small scissor and checked under the microscope. The calculation of infection prevalence was proved by (4). The evaluation of ectoparasites may be conducted using a

light compound microscope with a magnification range of 4-10X.

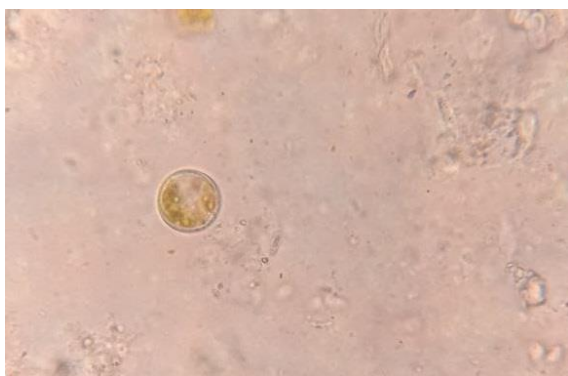
Prevalence (%) = (number of infected fish/total number of examined fish) × 100 (12).

### 3. Results

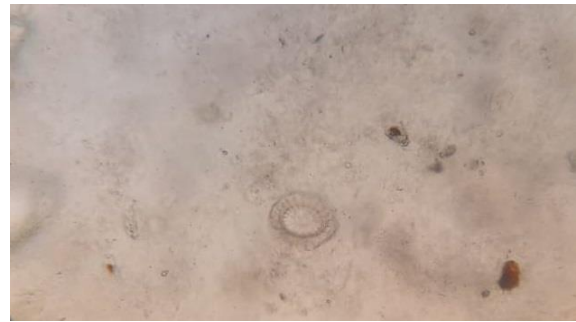
#### 3.1. Parasite Diversity and Prevalence

After examining 320 individual fish, several parasites were identified. We identified *Ichthyophthirius* spp., *Trichodina* spp., *Dactylogyrus* spp., *Gyrodactylus* spp. The infected number of *C. zillii* was 120 of 200, and *C. carpio* was 120 of 120. *C. zillii* in the Euphrates River were infected with four parasites *Ichthyophthirius* spp., *Trichodina* spp., *Dactylogyrus* spp., *Gyrodactylus* spp. in comparison with *C. carpio* in Razzaza Lake were infected only *I. multifiliis* and *Gyrodactylus* spp.

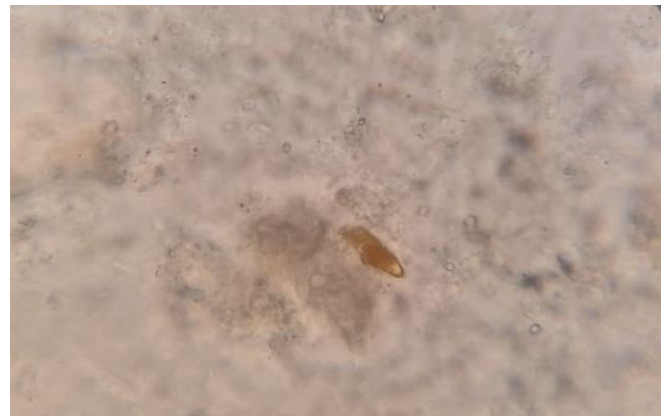The seroprevalence rate of 65.6%. The prevalence in Common carp was 100%, while in *C. zillii* was 30%. The study of the many infected fishes yielded findings indicating the manifestation of multiple clinical symptoms in both species. The total 200 of *C. zillii* from the Euphrates river and 120 *C. carpio* from Razzaza Lake. The number of parasites in *C. zillii* are (*Ichthyophthirius* spp. (70) and *Trichodina* spp., (10) in skin); while *Dactylogyrus* spp., (30) *Gyrodactylus* spp. (10) in gills. *C. carpio* was confirmed only two parasites (*Ichthyophthirius* spp. (90), and *Gyrodactylus* spp., (10) in skin); while *Ichthyophthirius* spp., (10) *Gyrodactylus* spp. (10) in fins and *Ichthyophthirius* spp. (10) in gills. The presence of necrotic regions, ulcerations, and haemorrhage on the gills was noted. Protozoan and monogenean parasites were discovered in various areas of the host's body. Fig 1, 2,3,4 and 5.



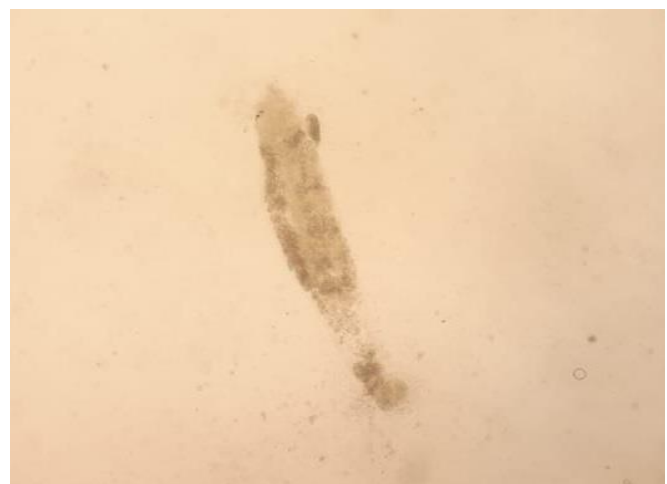**Figure 2.** Tomont stage of *I. multifiliis* in *C. carpio* skin X40



**Figure 3.** *Trichodina* spp. in *C. zillii* skin X100



**Figure 4.** *Dactylogyrus* spp. in *C. zillii* gills X40.



**Figure 5.** *Gyrodactylus* spp. in *Cyprinus carpio* fins X40.

#### 3.2. Clinical signs

Accordingly, the infected fish had symptoms of anorexia, lethargy, and respiratory distress. Moribund fish revealed hemorrhagic patches on the external body surfaces, ascites, redness below the opercula, and at the bases fins. Dermal ulcers were noticed on the external body surfaces of some fish.

**Table 1.** Prevalence type of hosts with type of infections

Type of host	No	Prevalence%			Total infection%
		Single infection%	Dual infection %	triple infection%	
<i>C. zillii</i>	200	30(15%)	0(0%)	90(45%)	60
<i>C. carpio</i>	120	30(25%)	40(33%)	50(42%)	100

**Table 2.** The relation among weight, length, and fish type.

	Fish type	Mean	Std. Deviation	P value
Weight	<i>Coptodon zillii</i>	75.2	15.2	0.000*
	<i>Cyprinus carpio</i>	17.4	3.0	
Length	<i>Coptodon zillii</i>	15.9	0.8	0.000*
	<i>Cyprinus carpio</i>	62.0	11.8	

Factors have been significant signed at the level  $P \leq 0.05$ .

**Table 3.** The relation among weight, length, and fish gender *C. zillii*.

	Gender/type 1( <i>C. zillii</i> )	Mean	Std. Deviation	P value
Weight	male	72.0	12.7	0.105
	female	84.7	19.5	
Length	male	15.8	0.9	0.415
	female	16.2	0.6	

Non-significant signed at the level  $P \geq 0.05$ .

**Table 4.** The relation among weight, length, and fish gender *C. carpio*.

	Gender/type2( <i>C. carpio</i> )	Mean	Std. Deviation	P value
Weight	male	19.3	1.6	0.056
	female	16.0	3.1	
Length	male	64.0	14.9	0.635
	female	60.5	10.0	

Non-significant signed at the level  $P \geq 0.05$ .

**Table 5.** Distribution of parasites in fish types with site of infection.

Type of fish	<i>Ichthyophthirius</i> spp.	<i>Trichodina</i> spp.	Site of infection	of <i>Dactylogyrus</i> spp.,	<i>Gyrodactylus</i> sp	Site of infection
<i>C. zillii</i>	70	10	skin	30	10	gills
<i>C. carpio</i>	90	-	skin	-	10	skin
	10	-	fins	-	10	fins
	10	-	gills	-	-	-

### 3.3. Statistical Analysis

The SPSS (version 24.0.0) program using Chi square was used to calculate the prevalence, mean intensity of the parasites. The total number of fish examined were examined the prevalence of infected fish, the mean intensity, the number of parasites per fish and the total number of infected fish, within each sample.

### 4. Discussion and Conclusion

Fish parasites serve as valuable biological indicators for assessing environmental quality due to their ability to respond to changes in water parameters and the presence of contaminants, leading to fluctuations in their population (3). Tilapia, a kind of fish, has been widely distributed worldwide. Currently, tilapia is being actively cultivated in more than 124 nations (15). Among numerous species of fishes, carps belong to the *Cyprinidae* family which is the biggest family of freshwater fishes, spreading widely around the world (16).

The current study demonstrates the ectoparasites in both types at different environments with a seroprevalence rate of 65.6%. The prevalence in Common carp was 100%, while in *C. zillii* was 60%. There are many studies have been conducted on ectoparasites globally. The study data with the closest proximity to other studies showed a seroprevalence of (*C. carp*) was 35.67% in Macedonia (9), and 100% from Indonesia (4). The worldwide reports show variability based on characteristics such as host type, environmental conditions, specimen size, biological and non-biological influences, host size, length, and weight.

Currently, in accordance with previously documented information, the Euphrates River in Al-Musaib city, located in the Babylon province of central Iraq, has been found to have ectoparasites and endoparasites in *T. zillii* (Gervais, 1848). There are five parasites identified in the text, including three ciliated protozoans (*I. multifiliis*, *Trichodina cottidarum*, and *Trichodina domerguei*), glochidia of the freshwater mussel *Unio pictorum*, and nematode larvae of *Contracaecum* spp. found in fish gills (17). Other study in the

Razzaza Lake, Karbala Province, Iraq, were reported *Contracaecum* L3 (only in all fish) in Planiliza abu (18).

Co-infections are prevalent in nature and arise when hosts are simultaneously or sequentially infected by several distinct diseases, resulting in the presence of two or more active infectious agents inside the same host. The sensitivity of fish to various pathogens may be altered during mixed infections, resulting in the occurrence of abrupt fish outbreaks (19). Consequently, fish that are unwell are more susceptible to contracting illnesses and spreading them to nearby species. Nevertheless, the impact and function of parasitic co-infections in cultivated tilapia have not been well examined and need more research (20). Abnormal mortalities were observed in farmed common carp (*C. carpio*) due to a simultaneous co-infection of *Dactylogyrus extensus* and *Pseudomonas fluorescens*. The monogenetic trematode *D. extensus* was found only in the gills of 70 *C. carpio* were collected from a private farm located in Kafrelsheikh governorate, Egypt, in wet mounts from the gills of all the examined fish samples 100% (13). Single infections in *C. zillii* and *C. carpio* were found to be 15% and 25% in the present research, dual infections to be 0% and 33%, and triple infections to be 45% and 42%.

In the present study, the presence of necrotic regions, ulcerations, and haemorrhage on the gills was noted. Protozoan and monogenean parasites were discovered on various areas of the host's body. The number of parasites in *C. zillii* are (*Ichthyophthirius* spp. (70) and *Trichodina* spp., (10) in skin); while *Dactylogyrus* spp., (30) *Gyrodactylus* spp. (10) in gills. *C. carpio* was confirmed only two parasites (*Ichthyophthirius* spp. (90), and *Gyrodactylus* spp., (10) in skin); while *Ichthyophthirius* spp., (10) *Gyrodactylus* spp. (10) in fins and *Ichthyophthirius* spp. (10) in gills. Abnormal mortalities were observed in farmed common carp (*C. carpio*) due to a simultaneous infection of *D. extensus* and *P. fluorescens*. The dying fish exhibited symptoms of reduced appetite, difficulty breathing, skin sores, and septicemia (13). Another study recorded (200) of fish *C. zillii* are collected from the Sarragy River in the Abu Alkhasiib region in Basra province, Iraq through two seasons of dissection and ablation

the gills for studied the histopathological change that appeared on it, that included change of the form of some secondary lamellae, adherence in other secondary lamella, cellular hyperplasia, hypertrophy, swelling in the epithelial layer of secondary lamellae, epithelial lifting, and hyperplasia in cartilage skeletal of primary filaments (21). Accordingly, the infected fish had symptoms of anorexia, lethargy, and respiratory distress. Moribund fish revealed hemorrhagic patches on the external body surfaces, ascites, redness below the opercula, and at the base fins. Dermal ulcers were noticed on the external body surfaces of some fish. The relationships between parasites, gut microbiota, and host by (22) who conducted research on ectoparasites *Dactylogyrus lamellatus* on the gills of the grass caused a change in the gut microbiota, as well as histological alterations and immunological responses. Carp ectoparasite-microbiota-host interactions suggest that fish ectoparasites likely possess distant

communication capabilities with the intestinal microorganisms of their hosts.

In conclusion, the study referred to distributing the ectoparasites in two environments. The difference was recorded between the two types of fish. A visual inspection should be made of the fish industry before sale in markets. Checking all fish species about internal and ectoparasites. Many of studies should be made to evaluate the ranges of parasitic infections in other fish species.

### Additional information

Related the manuscript: The abstract only participated in the conference, Third International Congress on Biological and Health Sciences. (Dates of the Congress: April 14-15-16, 2023. <https://www.biohealthcongress.com/>)

### References

- Dezfuli BS, Scholz T. Fish parasites. *Parasitology* 2022;149(14):1811-4.
- Yusni E, Rambe N. Identification of ectoparasites in fry Tilapia (*Oreochromis niloticus*) in aquaculture pond. In IOP Conference Series: Earth and Environmental Science 2019 May 1 (Vol. 260, No. 1, p. 012110). IOP Publishing.
- Jerônimo GT, da Cruz MG, Bertaglia ED, Furtado WE, Martins ML. Fish parasites can reflect environmental quality in fish farms. *Reviews in Aquaculture* 2022;14(3):1558-71.
- Indahsari M, Ulkhaq MF. Prevalence and Intensity of ectoparasites of tilapia (*Oreochromis niloticus*) in ponds with low, medium and high stocking density. In IOP Conference Series: Earth and Environmental Science 2019 Feb 1 (Vol. 236, No. 1, p. 012108). IOP Publishing.
- Li WJ, Lyu XM, Nie P, Liu Y. Morphological, histopathological and molecular characterization of parasitic ciliate *Ichthyophthirius multifiliis* infecting an indigenous and endangered fish, *Schizothorax macropogon* (Cyprinidae: Schizothoracinae) in high plateau, Tibet, China. *Aquaculture Reports* 2022;25:101192.
- Abu-Elala NM, Attia MM, Abd-Elsalam RM, Gamal A, Younis NA. Peracetic acid treatment of *Ichthyophthirius multifiliis* (Ciliophora: Ichthyophthiriidae) and *Trichodina* spp. reduces the infection by *Aeromonas hydrophila* and improves survival in Nile tilapia (*Oreochromis niloticus*). *Aquaculture* 2021;538:736591.
- Trujillo-González A, Becker JA, Hutson KS. Parasite dispersal from the ornamental goldfish trade. *Advances in Parasitology* 2018;100:239-81.
- Khalifa KA, Al-Khayat KM, Al-Rijab FH. Ichthyophthiriasis in farmed fishes in Iraq. *Journal of Wildlife Diseases* 1983;19(2):145.
- Blazhekovicj-Dimovska D, Stojanovski S. Ectoparasitic species of the genus *Trichodina* (Ciliophora: Peritrichida) parasitizing Macedonian freshwater fish. *Acta Biologica* 2020;27:11-20. <https://eprints.uklo.edu.mk/id/eprint/7537/>
- Wang Z, Bourland WA, Zhou T, Yang H, Zhang C, Gu Z. Morphological and molecular characterization of two *Trichodina* (Ciliophora, Peritrichia) species from freshwater fishes in China. *European Journal of Protistology* 2020;72:125647.
- Ali MD, Shaaban F. Some species of parasites of freshwater fish raised in ponds and in Tigris-Al-Tharthar canal region. Seventh Sci. In Conf. Iraqi Vet. Med. Assoc., Mosul 1984 Oct 23 (Vol. 23, No. 25, pp. 44-46).
- Abdullah YS. *Gyrodactylus angorae* (Monogenea: Gyrodactylidae): First Occurrence on the Body of Two Nemachilid Fishes from Iraq. *Zanco Journal of Pure and Applied Sciences* 2021;33(5).
- Attia MM, Abdelsalam M, Elgendy MY, Sherif AH. *Dactylogyrus extensus* and *Pseudomonas fluorescens* dual infection in farmed common carp (*Cyprinus carpio*). *Microbial Pathogenesis* 2022;173:105867.
- Abdullah SM. Additional records of *Dactylogyrus* (Monogenea) from some cyprinid fishes from Darbandikhan Lake, Iraq. *Jordan Journal of Biological Sciences* 2009;2(4):145-50.
- Shinn AP, Avenant-Oldewage A, Bondad-Reantaso MG, Cruz-Laufer AJ, García-Vásquez A, Hernández-Orts JS, Kuchta R, Longshaw M, Metselaar M, Pariselle A, Pérez-Ponce de León G. A global review of problematic and pathogenic parasites of farmed tilapia. *Reviews in Aquaculture* 2023;15:92-153.
- Al-Marjan KS, Abdullah SM. Some ectoparasites of the common carp (*Cyprinus carpio*) in Ainkawa fish hatchery, Erbil province. In Second Kurdistan conference on biological science. *Journal of Dohok University* 2009 (Vol. 12, No. 1, pp. 102-107).
- Al-Sa'adi BA, Mhaisen FT, Al-Rubae AL. The first parasitological report on the redbelly Tilapia *Tilapia zillii* (Gervais, 1848) in Iraq. In Proceedings of the Scientific Symposium of Natural History Research Center and Museum, Univ. Baghdad, Baghdad 2012 Jun 20 (Vol. 20, pp. 1-6).
- Jawad M, Ridha ZM, Alali F, Saeed EL, Alhesnawi AS. Distribution and Identification of the Parasitic Nematode *Contraecum* spp. in Planiliza Abu (Heckel, 1843: Mugiliformes, Mugilidae) From Razzaza Lake, Karbala Province, Iraq. *Bozok Veterinary Sciences* 2022;3(2):40-6. <https://dergipark.org.tr/en/pub/bozokvetsci/issue/74442/1170184>
- Kotob MH, Menanteau-Ledouble S, Kumar G, Abdelzaher M, El-Matbouli M. The impact of co-infections on fish: a review. *Veterinary Research* 2017;47(1):1-2.
- Islam SI, Rodkhum C, Taweethavonswat P. An overview of parasitic co-infections in tilapia culture. *Aquaculture International* 2023; 6:1-29.
- Samad KA, Ali AA. Study of Histopathological change in gills of *Coptodon zillii* as a bioindicator of pollution in Sarragy River In Abu Alkhasiib region. *Iraqi Journal of Aquaculture* 2014;11(2):141-52.
- Wang L, Zhang D, Xie J, Chang O, Wang Q, Shi C, Zhao F, Gong H, Ren Y, Musa N, Lee KL. Do ectoparasites on fish gills “talk” with gut microbiota far away?. *Aquaculture* 2023;562:738880.