

Case Report

Treatment of a Large Odontogenic Keratocyst: Case Report With 5-Year Follow-Up

Büyük Boyutlu Odontojenik Keratokist Olgusunun Tedavisi ve 5 yıllık Takibi

Gülin Acar¹ , Selen Adiloğlu² , Alper Aktaş³ 

ABSTRACT

Introduction: The Odontogenic Keratocyst (OKC) presents a unique challenge in the dentistry and oral pathology area. This locally aggressive lesion has been a matter of discussion in the literature, with debates revolving around its classification as either a cyst or a tumor. Its prominence as the third most common cyst in the jaw bones has captured the attention of clinicians and researchers alike. Given its aggressive clinical behavior and high recurrence rate, various treatment methods have been proposed to address OKC and mitigate the risk of recurrence, yet the ideal treatment approach and surgical margins remain elusive.

Case Report: This case report highlights the management of a large circumscribed OKC and underscores the importance of long-term patient follow-up. The patient has undergone five years of vigilant monitoring without any signs of recurrence. Ultimately, this case highlights the significance of adopting a personalized treatment approach that considers the patient's specific needs and lesion characteristics.

Conclusion: By prioritizing patient-centered and lesion-oriented decision-making, this case offers valuable insights for clinicians and serves as a reference for future similar cases.

Keywords: Keratocysts; Oral pathology; Surgical pathology

ÖZET

Giriş: Odontojenik Keratokist (OKK), literatürde kist veya tümör olup olmadığı tartışmaları devam etse de, günümüzde odontojenik kist sınıflamasında olan lokal agresif bir kisttir. Çene kemiklerinde en sık görülen 3. kist olduğu için klinik davranışı ve histolojik karakteri hem klinisyenlerin hem de araştırmacıların ilgisini çekmektedir. Agresif klinik davranışı ve yüksek nüks oranı nedenleri ile OKK'nin tedavisi ve nüks riskini azaltmak için bir çok yöntem önerilmiştir, ancak optimal tedavi yöntemi ve cerrahi sınırlar hala net değildir.

Olgu Sunumu: Bu olgu raporu, geniş sınırlı bir OKK'nin yönetimini ele alarak hastanın uzun vadeli izlemine vurgu yapmaktadır. Hastanın takip süreci, beş yıl boyunca nüks belirtileri olmaksızın devam etmektedir. Sonuç olarak, hastanın özel gereksinimlerine ve lezyon özelliklerine uygun olarak kişiselleştirilmiş bir tedavi yaklaşımı benimsenmiştir.

Sonuç: Bu olgu, hastaya odaklı ve lezyon-odaklı tedavi kararının doğruluğunu vurgulayarak klinisyenlere kılavuzluk etmek ve gelecekteki benzer olgular için referans oluşturmak amacıyla sunulmaktadır.

Anahtar Kelimeler: Cerrahi patoloji; Keratokistler; Oral patoloji

Makale gönderiliş tarihi: 24.10.2023; Yayına kabul tarihi: 02.12.2023

İletişim: Uzm. Dt. Gülin Acar

Hacettepe Üniversitesi Diş Hekimliği Fakültesi Ağız Diş ve Çene Cerrahisi ABD

E-Posta: gulinacar@hotmail.com

¹ Specialist, Hacettepe University, Faculty of Dentistry, Department of Oral and Maxillofacial Surgery, Ankara, Türkiye

² Asst. Prof., Hacettepe University, Faculty of Dentistry, Department of Oral and Maxillofacial Surgery, Ankara, Türkiye

³ Prof., Hacettepe University, Faculty of Dentistry, Department of Oral and Maxillofacial Surgery, Ankara, Türkiye

INTRODUCTION

The term 'odontogenic keratocyst (OKC)' was first used in 1956 to describe an odontogenic cyst lined with keratinized stratified squamous epithelium. In 1992, the World Health Organization (WHO) introduced the term 'odontogenic keratocyst'. This term was synonymous with 'primordial cyst', and was used to denote benign cysts of odontogenic origin with a specific histological appearance. However, in 2005, due to a high risk of recurrence, an aggressive clinical course, mutations in the tumor suppressor gene, the occurrence of satellite cysts, and its association with the Gorlin–Goltz syndrome, the WHO reclassified this pathology as a benign keratocystic odontogenic tumor (KCOT).^{1,2} Treatment response to marsupialization,³ a method typically ineffective against tumors, along with the identification of gene mutations in other cystic formations,⁴ cast uncertainty on whether this pathological lesion truly qualified as a tumor. In 2017, the WHO released the 4th edition of its classification for head and neck tumors.⁵ According to this updated classification, OKC is defined as an odontogenic cyst characterized by a thin, regular lining of parakeratinized stratified squamous epithelium with palisading hyperchromatic basal cells. OKCs account for 10-20% of odontogenic cysts, making them the third most common cysts affecting the jaws. They manifest across a wide age range, peaking in incidence during the second to third decades of life and showing a secondary, albeit smaller, peak among individuals aged 50-70 years. Most studies indicate a slight predilection for males.⁵

Histologically, OKC is typified by several key features. Its lining comprises a thin parakeratinized stratified squamous epithelium, measuring approximately 5 to 8 cells thick. This epithelium is topped with a thin corrugated layer of parakeratin, displaying a characteristic palisaded pattern with uniform nuclei observed in the basal cell layer. A notable characteristic of OKCs is the presence of daughter cysts, which form by budding from the basal cell layer into the surrounding connective tissue. The fibrous cyst wall is typically relatively thin and tends to lack inflammatory cell infiltration.⁶

OKC is considered a developmental cyst originating from remnants of the dental lamina.⁶ An association exists with mutations or inactivation of the PTCH1

gene, which activates the Sonic Hedgehog signaling pathway, resulting in abnormal cell proliferation in the OKC epithelium.⁴ The OKC is potentially a locally aggressive lesion. One of the reasons thought to contribute to its local aggressiveness is the high mitotic index of the epithelial cyst lining as compared to regular odontogenic cysts. However, a mutation or inactivation of p53 impairs its function, leading to uncontrollable cell proliferation, including tumor cells.^{4,6} This concept meets the principles regarding the local aggressiveness of OKC's and would explain the high recurrence rate after incomplete enucleation when fragments of the cyst wall have been left behind. Treatment is most often by enucleation, or by surgical resection for large lesions.^{4,6} Recurrences were more frequent in the past, but meticulous treatment has dramatically reduced them. A systematic review found an overall recurrence rate of about 25%.⁷ Recurrence after resection treatment, especially recommended for large lesions, is rare.⁷ However, the optimal treatment method for OKC has not yet been determined within definite limits in the literature.

Given the elevated recurrence rate, extended, long-term follow-up is highly advisable, particularly in cases involving sizable pathologies. In this case report, we delve into the management of a large odontogenic keratocyst without clinical symptoms and the underscore the significance of comprehensive, long-term follow-up.

CASE REPORT

In 2018, a 29-year-old female patient sought dental care due to pain stemming from caries affecting her right upper molar tooth. During a routine panoramic and clinical examination, a substantial radiolucent lesion was unexpectedly identified in the left mandibular region (Figure 1). Consequently, the patient was referred to the Department of Dentistry, Oral and Maxillofacial Surgery at Hacettepe University.

The initial examination did not reveal any clinical findings such as paresthesia, pain, swelling, or pus discharge. According to a detailed medical history, which was taken from the patient, it was revealed that the patient had her lower left third molar extracted roughly a decade ago. Following the extraction, the patient was informed that a lesion was discovered in the same area during the procedure and that this lesion had been curettaged. However, no

pathological examination of the lesion had been conducted at that time. Informed consent was obtained from the patient for all planned procedures, and the treatment planning process was initiated.

Following the initial clinical assessment, the patient underwent Cone Beam Computed Tomography

(CBCT) imaging. This imaging revealed a 60 mm X 43 mm lesion characterized by a smooth radiopaque border (Figure 2.). The lesion started from the mesial aspect of tooth number 34 and extended to encompass the coronoid process and condyle neck, involving the mandibular corpus, angulus, and ramus.

Surgical excision and curettage treatment was planned under general anaesthesia with the pre-di-

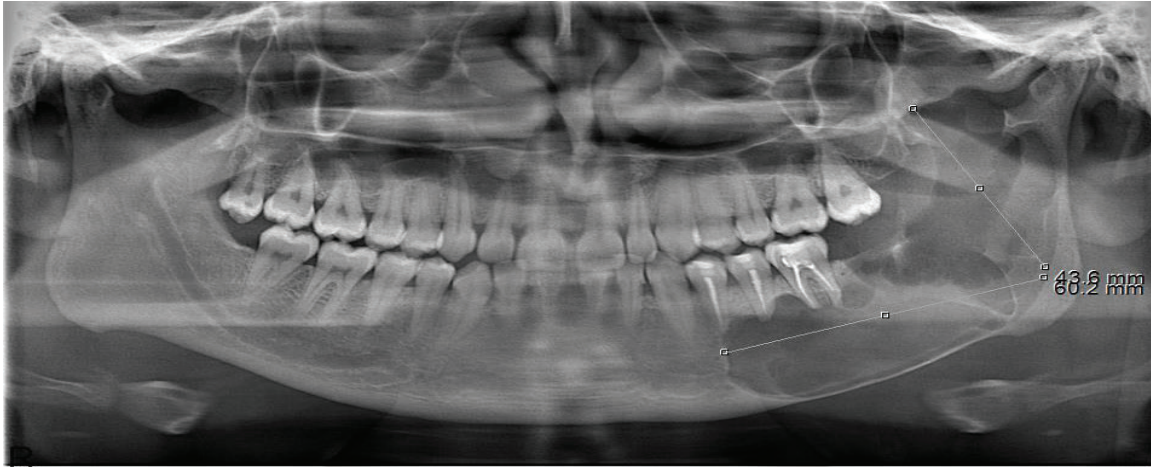


Figure 1. Initial Panoramic Radiograph of the Patient at Presentation

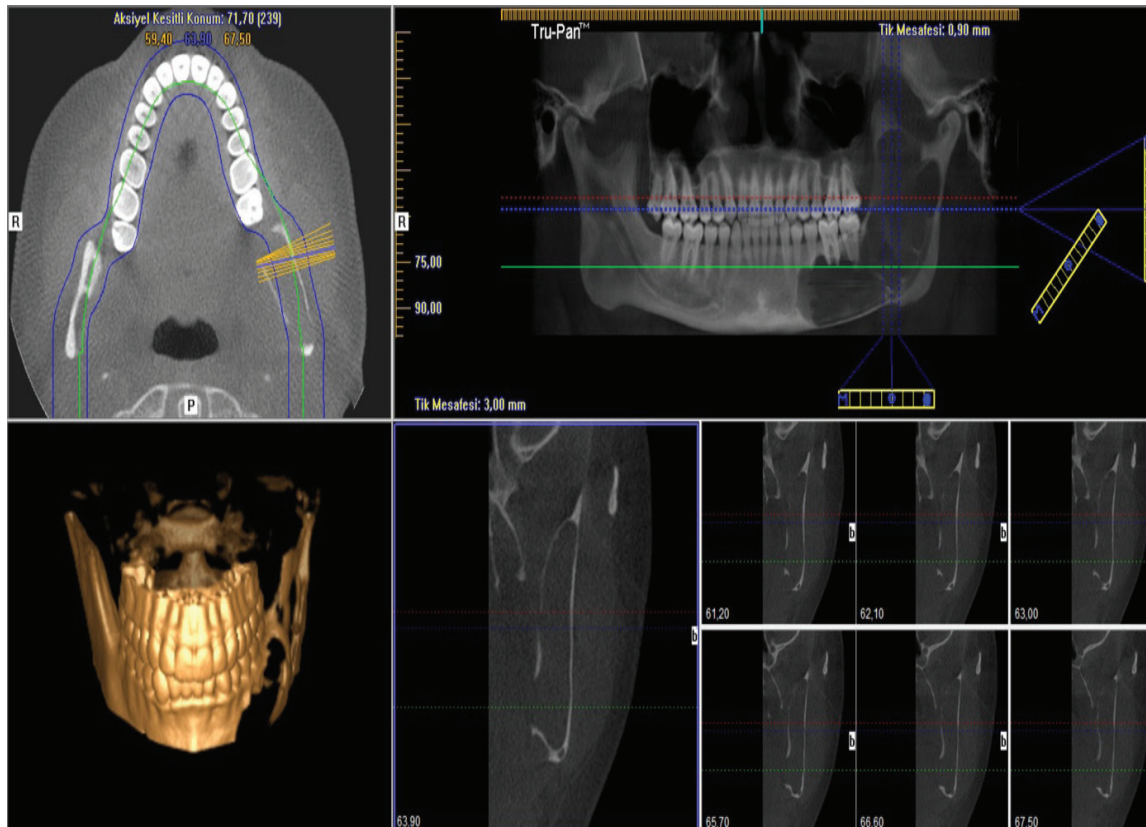


Figure 2. CBCT Images of the Patient at Admission Demonstrating Intact Buccal and Lingual Bone Walls.

agnoses of odontogenic keratocyst and ameloblastoma. To minimize the risk of recurrence, before the surgical intervention, root canal treatment and apical resection of the affected teeth were carried out.

Following the surgical procedure, a definitive diagnosis of odontogenic keratocyst was established upon examination of the pathological specimen. In light of this diagnosis, a meticulous long-term follow-up plan

was initiated. The patient's follow-up appointments were initially scheduled at 3-month intervals during the first year, with a transition to 6-month intervals in the second year (Figure 3). As of the present, the patient has reached the 5th year of follow-up, and notably, no signs of recurrence have been detected (Figure 4).

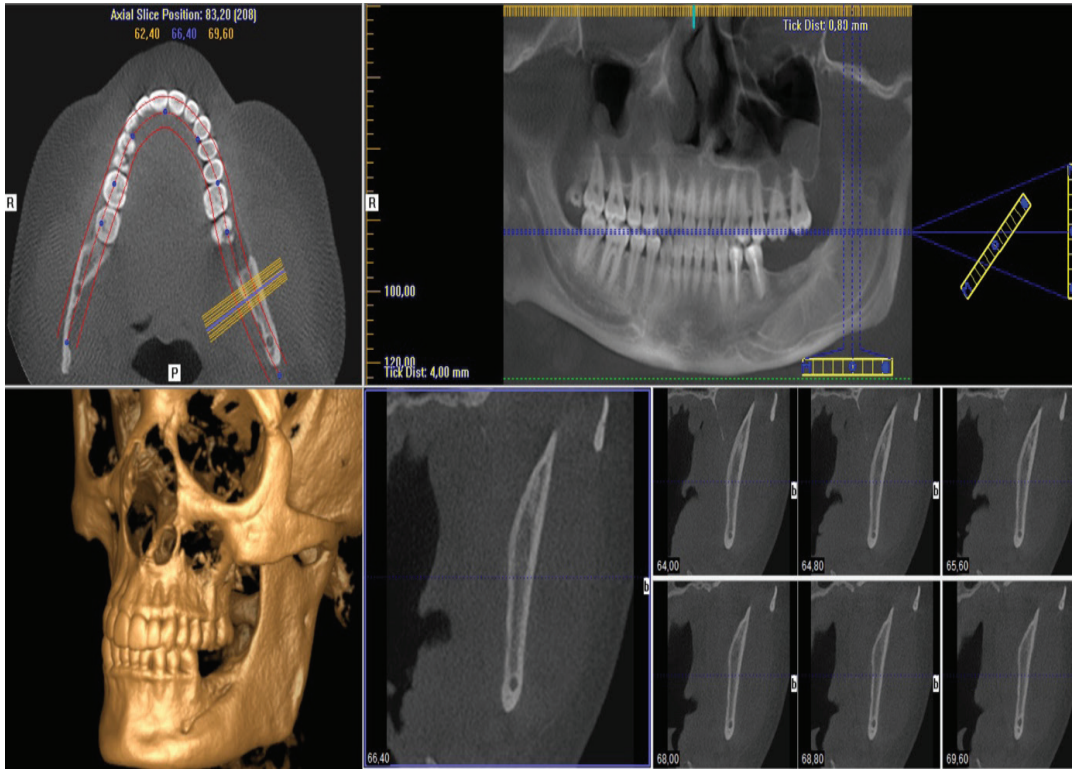


Figure 3. Five-Year Follow-Up: CBCT Images Indicating Healing and Bone Fill in the Cavity Initially Formed by the Keratocyst Lesion.

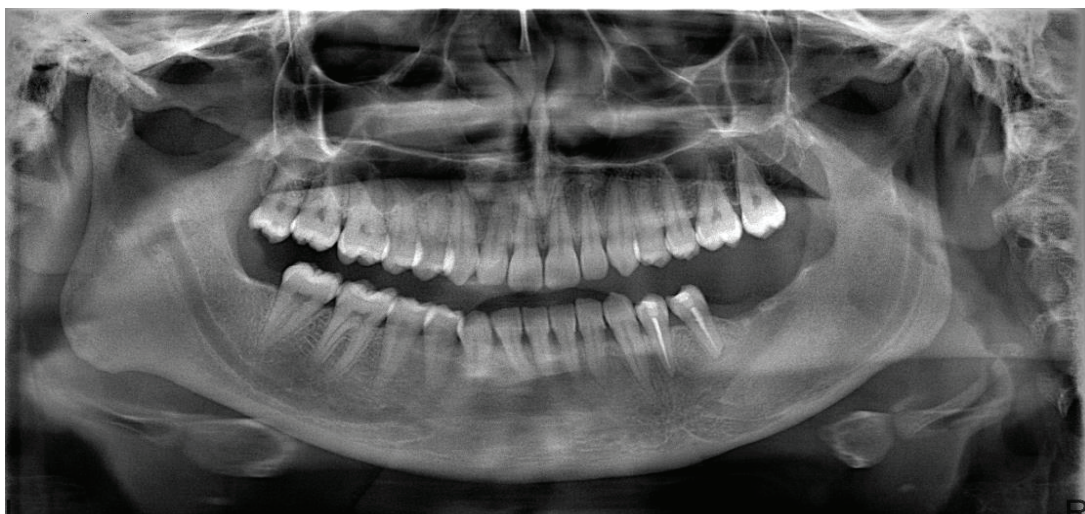

Figure 4. Final panoramic radiograph: The patient is radiographically asymptomatic.

DISCUSSION

To effectively reduce or prevent the recurrence of odontogenic keratocyst (OKC), several treatment modalities have been suggested. These options include enucleation, which involves the surgical removal of the cyst while preserving surrounding tissue. Another option is the excision of overlying mucosa followed by the application of Carnoy's solution⁸ to aid in preventing recurrence; marsupialization or decompression followed by complete cystectomy⁹, which is a staged approach to reduce cyst size before complete removal; and, in more extensive cases, mandibular resection¹⁰ may be considered as a treatment option. The choice of modality depends on the specific characteristics and extent of the OKC, with the ultimate goal of effectively managing the condition and minimizing the risk of recurrence.

In the case at hand, resective treatment options were deliberately avoided, taking into account several factors including the patient's young age, the extensive area that would require resection, the absence of a history of recurrence, and the patient's expressed preferences. Instead, a less invasive treatment approach was chosen. The patient was duly informed that resective treatment options would be considered should any signs of recurrence manifest in the future.

While several studies have a notably low recurrence rate following radical resection^{7,11}, it is important to recognize that this approach comes with significant morbidity. Consequently, it is rarely the initial treatment choice for benign lesions such as OKC. Typically, radical resection is reserved for cases where lesions have recurred following multiple conservative surgeries, or when OKCs have expanded beyond the confines of the bone. In clinical practice, this situation is most commonly encountered when there is perforation of the bony cortex, invasion into adjacent soft tissues, or the involvement of vital structures like the orbit or skull base. This approach is typically the treatment of choice in cases of multiple recurrences (two or more occurrences), large lesions exceeding 5 cm, and aggressive presentations.¹²

Notably, soft tissue perforations are frequently observed in the context of large odontogenic keratocysts (OKCs) in the mandible. These perforations

often result in the formation of mucosal epithelial islands, which have been reported as a potential factor contributing to recurrence, as demonstrated in the study by Stoelinga *et al.*¹³ Consequently, it is recommended to excise the affected mucosa in cases involving soft tissue perforations to reduce the risk of recurrence⁷. However, in the presented case, no evidence of mucosal perforation was identified, thus obviating the need for soft tissue excision. It is surmised that the absence of soft tissue perforation in this case represents a pivotal factor in the absence of recurrence. This underscores the importance of tailoring treatment options to individual patient needs and circumstances.

Another viable treatment option that could be considered in the presented case involves lesion excision following a decompression phase. Presently, decompression therapy is followed by conventional enucleation and curettage procedures, especially for extensive lesions or those situated in anatomically challenging locations. Decompression therapy is particularly well-suited when dealing with substantial cystic lesions in proximity to critical anatomical structures.⁹ This method involves the drainage of cystic fluid through an aperture during the decompression phase, leading to a reduction in intra-cystic pressure and the subsequent development of bone along the cystic wall.¹⁰ Consequently, it can be argued that the combination of decompression and second-stage enucleation holds advantages in terms of mitigating adverse consequences such as nerve injury and pathologic fracture.^{9, 14} Literature reports^{3,15} have suggested that keratocysts, specifically, can exhibit a notable swifter and more predictable response to marsupialization in comparison to other forms of odontogenic cysts, particularly when the decompression protocol is applied. Additionally, studies have indicated that the growth of these lesions tends to become less aggressive during the decompression process¹⁶. However, in the presented case, this treatment approach was deliberately set aside. This decision was influenced by the patient's residence at a considerable distance from the treatment center, raising concerns about the feasibility of adhering to a lengthy treatment protocol that marsupialization entails.

CONCLUSION

In summary, the treatment approach in the case presented was meticulously tailored to account for various patient and lesion-specific factors. These considerations encompassed the patient's age, their expectations, and the degree of compliance with the chosen treatment, in addition to the extent and boundaries of the lesion. Equally significant was the absence of soft tissue perforations. This patient-centered approach ensured that the chosen course of treatment was both appropriate and in alignment with the unique characteristics of the case. The noteworthy absence of any recurrence evidence during the 5-year follow-up period, even in the case of a considerably large OKC, underscores the precision and appropriateness of the patient-centered and lesion-oriented treatment decision.

REFERENCES

- Kaczmarzyk T, Stypułkowska J, Tomaszewska R. Update of the WHO classification of odontogenic and maxillofacial bone tumours. *J. Stomatol* 2017;70:484-506.
- Suluk-Tekkesin M, Wright JM. The World Health Organization Classification of Odontogenic Lesions: A Summary of the Changes of the 2022 (5th) Edition. *Turk Patoloji Derg* 2022;38:168-84.
- Pogrel MA, Jordan R. Marsupialization as a definitive treatment for the odontogenic keratocyst. *J Oral Maxillofac Surg* 2004;62:651-5.
- Bhargava D, Deshpande A, Pogrel MA. Keratocystic odontogenic tumour (KCOT)—a cyst to a tumour. *Oral Maxillofac Surg* 2012;16:163-70.
- El-Naggar AK, Chan JKC, Grandis JR, Takata T, Slootweg PJ. WHO Classification of Head and Neck Tumours: IARC ; 2017.
- Kolář Z, Geierová M, Bouchal J, Pazdera J, Zbořil V, Tvrđý P. Immunohistochemical analysis of the biological potential of odontogenic keratocysts. *J Oral Pathol Med* 2006;35:75-80.
- Al-Moraissi EA, Dahan AA, Alwadeai MS, Oginni FO, Al-Jamali JM, Alkhatari AS, *et al.* What surgical treatment has the lowest recurrence rate following the management of keratocystic odontogenic tumor?: A large systematic review and meta-analysis. *J Craniomaxillofac Surg* 2017;45:131-44.
- Voorsmit RA, Stoelting PJ, van Haelst UJ. The management of keratocysts. *J Maxillofac Surg* 1981;9:228-36.
- Esmael W, Aly L, El Kammar H, Magdy A, Taher S, Abo Zekry A. Optimum time of enucleation following marsupialization as a treatment strategy for large odontogenic keratocyst.(Radiologic and histopathologic study). *Egypt Dent J* 2023;69:949-56.
- Mohanty S, Dabas J, Verma A, Gupta S, Urs A, Hemavathy S. Surgical management of the odontogenic keratocyst: A 20-year experience. *Int J Oral Maxillofac Surg* 2021;50:1168-76.
- Titinchi F. Protocol for management of odontogenic keratocysts considering recurrence according to treatment methods. *J Korean Assoc Oral Maxillofac Surg* 2020;46:358-60.
- Blanas N, Freund B, Schwartz M, Furst IM. Systematic review of the treatment and prognosis of the odontogenic keratocyst. *Oral Surg Oral Med Oral Pathol Oral Radiol Endod* 2000;90:553-8.
- Stoelting PJ. Long-term follow-up on keratocysts treated according to a defined protocol. *Int J Oral Maxillofac Surg* 2001;30:14-25.
- Yu L, Xie Z, Yu L, Xu D, Yao N, Zhang Z. Efficacy and duration of odontogenic keratocyst treated with decompression: A systematic review and meta-analysis. *J Oral Maxillofac Surg Med Pathol* 2022;34:673-8.
- Brøndum N, Jensen VJ. Recurrence of keratocysts and decompression treatment: a long-term follow-up of forty-four cases. *Oral Surg Oral Med Oral Pathol* 1991;72:265-9.
- Telles DC, Castro WH, Gomez RS, Souto GR, Mesquita RA. Morphometric evaluation of keratocystic odontogenic tumor before and after marsupialization. *Braz Oral Res* 2013;27:496-502.