

## Evaluation of The Relationship Between the Selected Particle Size and Procedure Success and Complications in Bronchial Artery Embolisation

### Bronşiyal Arter Embolizasyonunda Kullanılan Partikül Boyutu ile İşlem Başarısı ve Komplikasyonlar Arasındaki İlişkinin Değerlendirilmesi

<sup>1</sup>Mustafa ÖZDEMİR, <sup>2</sup>Ayşe Şule ATEŞ, <sup>1</sup>Mehmet Halil ÖZTÜRK

<sup>1</sup>Sakarya University, Faculty of Medicine, Department of Radiology, Sakarya, Türkiye

<sup>2</sup>Sakarya Training and Research Hospital, Department of Chest Diseases, Sakarya, Türkiye

Mustafa Özdemir: <https://orcid.org/0000-0002-1934-5346>

Ayşe Şule Ateş: <https://orcid.org/0000-0002-8612-6899>

Mehmet Halil Öztürk: <https://orcid.org/0000-0002-4530-7167>

#### ABSTRACT

**Objective:** Hemoptysis refers to the discharge of blood, which originates from the lungs or bronchial system through the mouth. This study aimed to examine the importance of the particle size used in patients undergoing bronchial artery embolisation (BAE) regarding procedure success and complications.

**Materials and Methods:** Data from patients who underwent BAE using polyvinyl alcohol (PVA) particles were collected retrospectively. Hemoptysis etiology and localisation, lesion type, the size of the embolising agent used, and postoperative complications were recorded. Thirty-day follow-up results were evaluated.

**Results:** Fifty-six patients were included in the study. The size of the PVA particles used was 300-500 microns in 30 patients (53.6%) and 500-700 microns in 26 patients (46.4%). Bleeding completely stopped in 92.9% of the cases within 30 days after the procedure. Procedure success or complications did not significantly differ between the patient groups in which 300-500 micron and 500-700 micron particles were used during BAE.

**Conclusions:** BAE is a safe, effective, and minimally invasive method that can be performed repeatedly to treat hemoptysis. This study showed that regardless of size, PVA particles were effective and safe agents that could be used during this procedure.

**Keywords:** Embolization, hemoptysis, particular agent

#### ÖZ

**Amaç:** Hemoptizi pulmoner veya bronşiyal vasküler sistemden kaynaklanan kanın ağızdan gelmesidir. Bu çalışmanın amacı bronşiyal arter embolizasyonu (BAE) yapılan hastalarda kullanılan partikül boyutunun işlem başarısı ve komplikasyonlar açısından önemini incelemektir.

**Materyal ve Metot:** Polivinil alkol partikülleri (PVA) kullanılarak BAE yapılan hastaların verileri retrospektif olarak toplanmıştır. Hemoptizi etiyolojisi, lokalizasyonu ve lezyon tipi, kullanılan embolize edici ajan boyutu ve postoperatif komplikasyonlar kaydedildi. 30 günlük takip sonuçları değerlendirildi.

**Bulgular:** Çalışmaya 56 hasta dahil edildi. 30 hastada (%53,6) 300-500 mikron, 26 hastada (%46,4) ise 500-700 mikron boyutlu partiküller ajanlar kullanıldı. İşlem sonrası hastaların %92,9'unda kanama durdu ve 30 gün içerisinde tekrarlamadı. 300-500 mikron ile 500-700 mikron boyutlu partikül kullanılan hastalar karşılaştırıldığında başarısı ve komplikasyonlar açısından anlamlı farklılık saptanmadı.

**Sonuç:** BAE, hemoptizi tedavisi için tekrar tekrar yapılabilen güvenli, etkili ve minimal invaziv bir yöntemdir. PVA partiküllerinin BAE'nda kullanılabilir etkin ve güvenli bir ajan olduğu gösterildi.

**Anahtar Kelimeler:** Embolizasyon, hemoptizi, partiküler ajan

#### Sorumlu Yazar / Corresponding Author:

Mustafa Ozdemir  
Sakarya University, Faculty of Medicine, Department of Radiology,  
Sakarya, Türkiye  
Tel: +90 264888 4000  
E-mail: drmsfrd@gmail.com

#### Yayın Bilgisi / Article Info:

Gönderi Tarihi/ Received: 23/12/2023  
Kabul Tarihi/ Accepted: 01/02/2024  
Online Yayın Tarihi/ Published: 11/03/2024

**Atf / Cited:** Özdemir M and et al. Have Evaluation of The Relationship Between the Selected Particle Size and Procedure Success and Complications in Bronchial Artery Embolisation. *Online Türk Sağlık Bilimleri Dergisi* 2024;9(1):84-88. doi: 10.26453/otjhs.1408872

## INTRODUCTION

Hemoptysis refers to the expectoration of blood from the respiratory system due to pulmonary or tracheobronchial disorders, such as bronchiectasis, respiratory tract infections, asthma, chronic obstructive pulmonary disease (COPD), and malignancy.<sup>1</sup> Hemoptysis is classified as mild, moderate, and massive based on the quantity of expectorated blood. It is considered mild if 24-hour bleeding is less than 100 ml, moderate if 100-600 ml, and massive if greater than 600 ml.<sup>2</sup> Bleeding often stops spontaneously with supportive treatment. However, especially in patients with massive bleeding, the escape of blood elements into the respiratory tract may require urgent intervention since it can cause asphyxia and death.<sup>3</sup>

This study aimed to compare different particle sizes utilised in bronchial artery embolisation (BAE) regarding their efficacy and potential complications.

## MATERIALS AND METHODS

**Ethics Committee Approval:** The study was approved by the Ethics Committee of the Sakarya University Faculty of Medicine (Date: 02.02.2022, decision no: 102126\_23) and performed by the Helsinki Declaration.

**Subjects:** Fifty-six patients who underwent BAE at our clinic due to hemoptysis from January 2019 to January 2022 were included in the study. Patient data were retrospectively screened from the hospital's electronic system. Causes of hemoptysis, bleeding sites, pathological vascular findings on digital subtraction angiography, embolising agents used, and postoperative complications were recorded. The procedure was assumed to be technically successful if pathological vascular findings disappeared after embolisation. No recurrence of bleeding during the 30-day follow-up was considered clinical success. During the embolisation process, the arteries from which the bleeding was thought to originate were catheterised using 5-Fr Cobra 2 or Simmons 1 diagnostic catheters (Terumo, Tokyo, Japan). Bronchial arteries were carefully examined to detect possible

branches and critical collateral circulations. A 3-Fr microcatheter (Renegade, Boston Scientific, USA) was used to reach and embolise the more distal portion. Polyvinyl alcohol (PVA) particles (Contour; Boston Scientific, Cork, Ireland) were used as embolising agents in all patients. Possible bleeding etiologies and enlargement of bronchial arteries were considered when determining the particle size planned to be used. While small-sized particles were preferred to ensure more distal penetration in patients bleeding due to malignant lesions, large-sized particles were preferred in patients with tortuous bronchial arteries. Upon the disappearance of the pathological vascularisation and findings, the procedure was deemed successful and subsequently terminated.

**Statistical Analysis:** MedCalc (version 12, Ostend, Belgium) was used for statistical analyses. Descriptive statistics are presented as median (minimum-maximum) and mean  $\pm$  standard deviation values. Categorical variables were expressed as frequencies and percentages. The Fisher, Pearson chi-square, and Yates' corrected Pearson chi-square tests were used to compare categorical variables. The independent-sample t-test was used to compare continuous variables with a normal distribution according to the Kolmogorov-Smirnov test. In contrast, the Mann-Whitney U test was used for data that did not comply with a normal distribution. A p-value of  $<0.05$  was considered statistically significant.

## RESULTS

A total of 56 patients were included in the study. Forty-four patients were male (78.6%), and 12 (21.4%) were female. The mean hemoglobin value was  $11.4 \pm 1.8$  g/dL. The mean platelet count was  $271 \pm 81$  K/uL. The mean international normalised ratio (INR) was  $1.2 \pm 0.12$ . The etiology of bleeding was evaluated as malignancy in 18 patients (32.1%), COPD in 14 (25%), tuberculosis in 12 patients (21.4%), bronchiectasis in eight patients (14.3%), and COVID-19 pneumonia in four (7.2%) (Table 1).

**Table 1.** Bleeding etiologies.

Etiology	n (%)
Malignancy	18 (32.1)
COPD	14 (25)
Tuberculosis	12 (21.4)
Bronchiectasis	8 (14.3)
COVID-19 pneumonia	4 (7.2)

COPD: chronic obstructive pulmonary disease; COVID-19: Coronavirus disease 19.

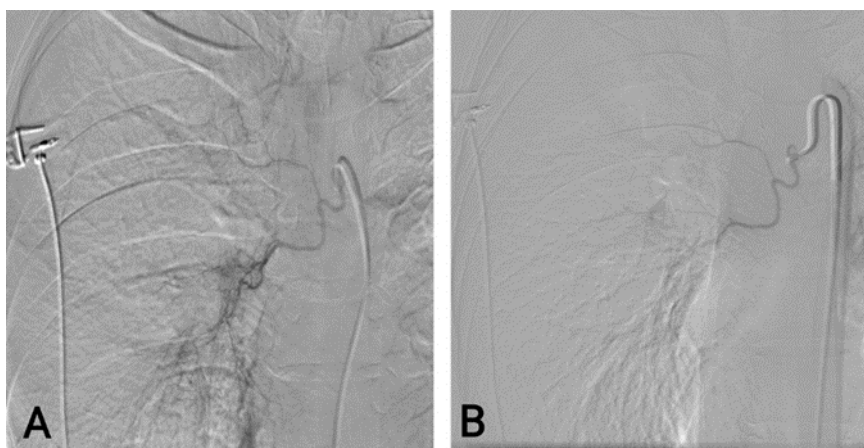
The right bronchial artery was embolised in 26 patients (46.4%), the left bronchial artery in 24 patients (42.9%), and both bronchial arteries in six patients (10.7%). The PVA particles used as an embolising agent were 300-500 or 500-700 microns in size (Contour; Boston Scientific, Cork, Ireland). PVA particles of 300-500 microns in size were used in 30 patients (53.6%), and 500-700 micron PVA particles were employed in 26 patients (46.4%). The success criterion of the procedure was accepted as the absence of hemoptysis recurrence.

The procedure successfully stopped bleeding in 52 (92.9%) patients (Figure 1). Hemoptysis persisted following embolisation in the remaining four (7.1%) patients. Patients whose bleeding did not stop or recurred within 24 hours were defined as recurrent bleeding. Embolisation was repeated in three of

these patients, and it was observed that the bleeding was from a different artery. The bleeding stopped after the second embolisation. One patient died due to systemic reasons, while the second procedure was being planned.

The most common complication after the procedure was chest pain, which developed in nine (16%) patients. This complication was relieved with supportive medical treatment. No significant difference was detected between the 300-500 micron and 500-700 micron PVA particle groups regarding pain development.

There were no significant differences between the 300-500 micron and 500-700 micron PVA particle groups concerning age, gender, hemoglobin value, platelet count, INR, procedure success, or complications (Table 2).



**Figure 1.** Increased vascularity originates from the right bronchial artery due to the tumor (A). Increased vascularity disappeared after a successful embolisation (B).

**Table 2.** Comparison of 300-500 micron and 500-700 micron particle groups.

	300-500 micron	500-700 micron	p
Age	61.4	60.7	0.847
Gender, (M/F)	23/7	21/5	0.752
Hemoglobin, (g/dL)	11.6	11.2	0.705
Platelet count, (K/uL)	277	264	0.574
INR	1.29	1.23	0.935
Procedure success	93.3%	92.3%	0.644

M: male; F: female; INR: International normalised ratio.

## DISCUSSION AND CONCLUSION

Hemoptysis is the expectoration of blood originating from the pulmonary or bronchial vascular system.<sup>4,5</sup> Malignancies and COPD were prominent in the bleeding etiology of the patients included in our study.

Transarterial embolisation plays a crucial role in intervening in bleeding that does not stop with supportive treatment. Despite several variations, there are generally two main bronchial arteries, one on the right and two on the left.<sup>6,7</sup>

Various agents can be used for embolisation, with the most commonly utilised materials being PVA particles, shaped microspheric particles, absorbable gelatin sponges, N-Butyl 2-Cyanoacrylate (Glue), liquid embolising agents, and coils. The choice of material depends on the clinician's experience and the etiology of the bleeding.<sup>8-10</sup> As shown in the studies, there is no relationship between the selected embolisation material and the procedure's success. Unlike PVA, shaped microspheric particles are smaller in diameter and tend to accumulate less in

the catheter due to their uniform structure. Therefore, for safe embolisation, microspheric particles that are larger should be selected compared to PVA particles.<sup>11</sup>

In our study, we aimed to evaluate whether there is a relationship between the selected particle sizes and procedure success and complications. In the study conducted by Nilpatrewar et al.,<sup>12</sup> the overall success rate of the procedure was 88%. In the study conducted by Soylu et al.,<sup>13</sup> bleeding stopped entirely in 94.2% of the cases in the first 30 days after the procedures. Our study determined that bleeding stopped after embolisation in 52 of 56 patients (92.8%), which is compatible with the literature. Furthermore, when evaluating the procedure outcomes, we detected no significant difference in procedure success between the cases where BAE was performed using 300-500 micron and 500-700 micron PVA particles. The most common complications of BAE are groin hematoma, chest pain, and focal neurological deficits. The study by Panda et al.<sup>14</sup> shows us a rate of major complications remained negligible and stable over time with a median incidence of 0.1% (0%-6.6%), and the other study conducted by Tom et al.<sup>15</sup> shows us major complications less than 1%. In our study, there were no major complications. Nine (16%) patients developed chest pain, which was relieved with short-term analgesic support, and these patients were discharged without any symptoms. There was no difference in the rate of patients with chest pain according to the PVA particle size.

In conclusion, BAE stands out as a very effective treatment method with low complications and high clinical success rates in the treatment of hemoptysis. This study showed that regardless of size, PVA particles were effective agents for embolisation. However, the lack of long-term follow-up results can be considered a study limitation.

**Ethics Committee Approval:** Our study was approved by the Sakarya University Ethics Committee (Date: 02.02.2022, decision no: 102126\_23). This study was conducted following the principles of the Declaration of Helsinki.

**Conflict of Interest:** No conflict of interest was declared by the authors.

**Author Contributions:** Concept –MÖ, MHÖ; Supervision – AŞA; Materials – MÖ, MHÖ; Data Collection and/or Processing – MÖ, AŞA; Analysis and/or Interpretation – MÖ, AŞA; Writing – MÖ.

**Peer-review:** Externally peer-reviewed.

## REFERENCES

1. Fu Z, Li X, Cai F, et al. Microspheres present comparable efficacy and safety profiles compared with polyvinyl alcohol for bronchial artery embolization treatment in hemoptysis patients. *J Transl*

*Med.* 2021;19(1):422. doi:10.1186/s12967-021-02947-7

2. Dumanlı A, Aydın S. Evaluation of patients presenting with the complaint of hemoptysis. *KTD.* 2022;23(3):344-349. doi:10.18229/kocatepetip.977399
3. Çolak M, Aslaner MA. Etiological evaluation in patients presenting with hemoptysis. *Sakarya Tıp Dergisi.* 2019;9(4):626-631. doi:10.31832/smj.563499
4. Xu HD, Yang L, Hu SB. Embosphere microspheres size for bronchial artery embolization in patients with hemoptysis caused by bronchiectasis: A retrospective comparative analysis of 500-750 versus 700-900 µm microspheres. *BMC Pulm Med.* 2023. doi:10.21203/rs.3.rs-3392654/v1
5. Fidan A, Ozdoğan S, Oruç O, Salepci B, Ocal Z, Çağlayan B. Hemoptysis: A retrospective analysis of 108 cases. *Respir Med.* 2002;96(9):677-680. doi:10.1053/rmed.2002.1359
6. Atchinson PRA, Hatton CJ, Roginski MA, Backer ED, Long B, Lentz SA. The emergency department evaluation and management of massive hemoptysis. *Am J Emerg Med.* 2021;50:148-155. doi:10.1016/j.ajem.2021.07.041
7. Yoon W, Kim JK, Kim YH, Chung TW, Kang HK. Bronchial and nonbronchial systemic artery embolization for life-threatening hemoptysis: A comprehensive review. *Radiographics.* 2002;22(6):1395-1409. doi:10.1148/rg.226015180
8. Piacentino F, Fontana F, Curti M, Coppola A, Venturini M. Bronchial artery embolization with an ethylene vinyl alcohol copolymer agent (Squid) and polyvinyl alcohol particles for treatment of hemoptysis. *Diagn Interv Radiol.* 2021;27(6):786-788. doi:10.5152/dir.2021.20601
9. Oğuz Ş. Endovascular treatment in the management of hemoptysis: Single center experience and early stage clinical results. *SDÜ Tıp Fak Derg.* 2020;27(1):17-22. doi:10.17343/sdutfd.542696
10. Dorji K, Hongsakul K, Jutidamrongphan W, Oofuvong M, Geater S. Bronchial artery embolization in life-threatening hemoptysis: Outcome and predictive factors. *J Belg Soc Radiol.* 2021; 105(1):5. doi:10.5334/jbsr.2310
11. Lee JH, Yoon CJ, Jung YS, Choi WS, Lee CH, Lee GM. Comparison of n-butyl-2-cyanoacrylate and polyvinyl alcohol particles for bronchial artery embolisation in primary lung cancer: A retrospective cohort study. *Respir Res.* 2022;23(1):257. doi:10.1186/s12931-022-02183-7
12. Nilpatrewar G, Ramraje N, Pujari V, Mohan S, Meshram P. A longitudinal study evaluating indications, efficacy and complications of bronchial artery embolisation. *J Clin Diagn Res.* 2022;16(9):34-37. doi:10.7860/JCDR/2022/58109.16954
13. Idil Soylu A, Uzunkaya F, Belet Ü, Akan H. Se-

- lective transarterial embolization of acute renal hemorrhage: A retrospective study. *Minim Invasive Ther Allied Technol.* 2020;29(6):326-333. doi:10.1080/13645706.2019.1655063
14. Panda A, Bhalla AS, Goyal A. Bronchial artery embolization in hemoptysis: A systematic review. *Diagn Interv Radiol.* 2017;23(4):307-317. doi:10.5152/dir.2017.16454
15. Tom LM, Palevsky HI, Holsclaw DS, et al. Recurrent bleeding, survival, and longitudinal pulmonary function following bronchial artery embolization for hemoptysis in a U.S. adult population. *J Vasc Interv Radiol.* 2015;26(12):1806-1813.e1. doi:10.1016/j.jvir.2015.08.019