


# Dental Treatment Approach in an Adolescent Patient With Coffin-Siris Syndrome

## Coffin-Siris Sendromlu Çocuk Hastada Dental Tedavi Yaklaşımı

Nur Irmak ERAKMAN YEL\*<sup>1</sup>   
[dt.irmakerakman@gmail.com](mailto:dt.irmakerakman@gmail.com)

Cafer ATAŞ<sup>2</sup>   
[cafer.atas@sbu.edu.tr](mailto:cafer.atas@sbu.edu.tr)

Günseli GÜVEN POLAT<sup>3</sup>   
[gunseli.guvenpolat@sbu.edu.tr](mailto:gunseli.guvenpolat@sbu.edu.tr)

### ABSTRACT

Coffin-Siris Syndrome (CSS) is a rare genetic disease with delayed growth, congenital anomalies, abnormal facial features, and mental retardation. Hypoplasia of the 5th fingers or nail agenesis, hirsutism, coarse facial appearance, thick eyebrows, wide lips and nose, dento-facial anomalies, and delayed eruption of teeth are clinically distinctive features. Specific findings and multidisciplinary approaches are important for dental treatments. This case report includes the clinical, oral findings, and dental treatments of the patient with CSS. A 15.5-year-old female patient consulted our clinic with the complaint of tooth sensitivity and missing teeth. The patient's family was informed that the patient has CSS. In clinical examination, coarse face, mental retardation, hypoplastic 5th fingers, wide mouth, and lips, sparse hair, and hirsutism, in the oral examination, poor oral hygiene, dental caries, delayed dentition, lack of upper permanent first incisor, gingival hyperplasia, gingivitis, and hypoplasia were seen. Panoramic radiography and tomography revealed that the upper permanent incisor and supernumerary canine teeth were impacted. Under general anesthesia, dental scaling, fillings were made, impacted permanent incisors, canine, and lower left third molars were extracted. After general anesthesia, fluoride application and a fiber-supported Maryland bridge designed from the patient's teeth were applied to the anterior region. Regular controls of the patient continue. After the growth and development, the oral surgery department will be consulted for implant application. In dentistry, preventive applications, oral hygiene motivation, pharmacological and non-pharmacological treatments are important for CSS patients. After consultation with relevant departments, multidisciplinary approaches and appropriate treatments increase the quality of life.

**Keywords:** Coffin-Siris syndrome, Fifth digit syndrome, Hypoplasia, Mental retardation

**Received:** 20.07.2023

**Accepted:** 12.12.2023

**Published:** 26.12.2023

### ABSTRACT

Coffin Siris Sendromu (CSS), büyüme ve gelişim geriliği, çoklu konjenital anomaliler, anormal yüz özellikleri, mental retardasyonla karakterize nadir görülen genetik bir hastalıktır. 5. parmakların hipoplazisi veya tırnak agenezi, hirsutizm, kaba yüz görünümü, kalın kaş, geniş dudak ve burun, dentofasiyal anomaliler, dişlerde sürme gecikmeleri klinik olarak ayırt edici özellikler arasındadır. Bu hastalarda spesifik klinik bulguların bilinmesi, multidisipliner yaklaşım, dental tedaviler açısından önemlidir. Bu vaka raporu, CSS'li hastanın klinik bulguları, ağız bulguları ve dental tedavilerini içermektedir. 15,5 yaşında kız hasta, kliniğimize dışında hassasiyet ve diş eksikliği şikayetiyle başvurdu. Ailesinden alınan anamnezde hastanın CSS'ye sahip olduğu bildirildi. Klinik muayenede CSS bulgularını destekler nitelikte kaba yüz görünümü, mental retardasyon, 5. parmaklarda hipoplazi, geniş ağız ve dudaklar, seyrek saçlar ve hirsutizm, ağız içi muayenede ise kötü ağız hijyeni, diş çürükleri, geç dişlenme, üst sağ daimi 1. keser diş eksikliği, gingival hiperplazi, gingivitis ve hipoplaziler görüldü. Panoramik radyografi ve tomografiden üst daimi keser ve supernümerer kanin dişin gömülü olduğu tespit edildi. Genel anestezi altında diş taşı temizliği, çürük dişlerin dolgusu, gömülü olan daimi keser, kanin ve alt sol 3. molar dişin cerrahi çekimi yapıldı. Genel anestezi sonrasında flor uygulaması ve ön bölge için hastanın kendi dişinden tasarlanan fiber destekli Maryland köprü uygulaması yapıldı. Hastanın düzenli kontrolleri devam etmektedir. Büyüme ve gelişim tamamlandıktan sonra implant uygulaması için cerrahi bölümüyle konsültasyon yapılacaktır. Diş hekimliğinde CSS gibi sendromlu hastalarda koruyucu uygulamalar, oral hijyen motivasyonu, farmakolojik ve non-farmakolojik yöntemlerle tedaviler önemlidir. Multidisipliner yaklaşım ve ilgili bölümlerle konsültasyon sonrasında yapılan uygun tedavilerle hastaların yaşam kalitesini arttırmak mümkündür.

**Anahtar Kelimeler:** Beşinci parmak sendromu, Coffin-Siris sendromu, Hipoplazi, Mental retardasyon

**Geliş:** 20.07.2023

**Kabul:** 12.12.2023

**Yayın:** 26.12.2023

**Atf/ Citation:** Erakman Yel N. I., Taş C., Güven Polat G., Dental Treatment Approach in an Adolescent Patient With Coffin-Siris Syndrome, NEU Dent J. 2023;5: 232-9.

\* Sorumlu Yazar/Corresponding Author

1. PhD Candidate, University of Health Sciences, Faculty of Dentistry, Department of Pediatric Dentistry, İstanbul, Türkiye
2. Assistant Professor, University of Health Sciences, Faculty of Dentistry, Department of Pediatric Dentistry, İstanbul, Türkiye
3. Professor, University of Health Sciences, Faculty of Dentistry, Department of Pediatric Dentistry, İstanbul, Türkiye



"This article is licensed under a Creative Commons Attribution-NonCommercial 4.0 International License. (CC BY-NC 4.0)"

## INTRODUCTION

Coffin-Siris syndrome (CSS; OMIM: # 135900) is a syndrome first described by Coffin G. and Siris E. <sup>1</sup> (1970) in a case report of 3 girls with common malformations. In the literature, it has also been defined as Dwarfism-Onychodysplasia, Fifth Finger and Nail Hypoplasia with Mental Retardation, Short Length-Onychodysplasia, and most commonly the Fifth Finger Syndrome.<sup>1-3</sup> CSS is also a rare multisystem genetic disease characterized by abnormal facial features, organ anomalies, mental retardation, and multiple malformations.<sup>4,5</sup> To date, approximately 200 individuals with CSS supported by molecular tests have been reported in the literature.<sup>6</sup> It is more common in women than men.<sup>3</sup>

Growth is typically ordinary in the prenatal period, and individuals with CSS may not show any specific signs or symptoms at birth. In these individuals, the first symptoms appear, usually during infancy. Delayed growth-development patterns, walking, feeding, and sucking problems are exhibited in infancy.<sup>5,7</sup> Aplasia or hypoplasia of the distal phalanx or nails of the fifth and other fingers, mental retardation, speech difficulties, delayed growth-development, hypotonia, joint laxity, short stature, epilepsy, ophthalmologic, cardiac and genitourinary system problems, hearing impairment, craniofacial problems (microcephaly, coarse facial features, wide mouth and nose, macroglossia, flat nasal bridge, cleft lip, and palate) ectodermal problems (hirsutism, hypertrichosis, sparse hair, dental anomalies) are among the characteristic features associated with the CSS.<sup>3,8-10</sup>

The molecular etiology of CSS was first described in 2012.<sup>6</sup> CSS is a disease associated with mutations in genes encoding subunits of the BRG1/BRM-associated factor (BAF) chromatin-remodeling complex.<sup>11</sup> This gene group includes ARID1A, ARID1B, SMARCA4, SMARCB1, SMARCE1, SOX11, PHF6, and DPF2, and heterozygous pathogenic variants in genes have been reported to cause CSS.<sup>9</sup> These genes also play a role in Nicolaides Baraitser syndrome and non-syndromic intellectual disability, which overlaps with CSS in terms of clinical features.<sup>2</sup> It has been reported that deletions in the ARID1B gene mostly cause the formation of CSS.<sup>9,12,13</sup> There is no evidence of X-linked

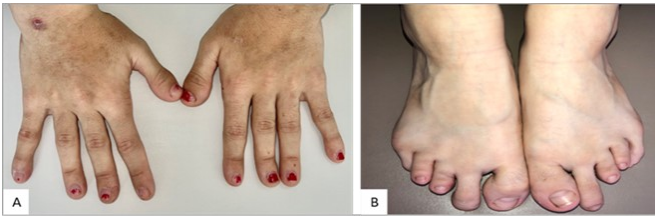
dominant, sex-related, or mitochondrial inheritance. It is inherited as autosomal dominant or recessive.<sup>14</sup>

Pediatric dentistry is responsible for the oral health of not only pediatric patients but also patients with syndromes and disabilities that require special care. There are not enough studies in the literature related to the specific oral findings, dental approach, and treatment management of patients with CSS. Preventive applications and dental treatments are substantial in patients with CSS due to the prevalence of systemic diseases such as cardiovascular diseases and the drugs used by these patients. Knowing the specific clinical findings seen in CSS, directing the patient to the relevant departments, and a multidisciplinary approach are crucial in terms of improving the health and quality of life of such patients. This case report includes the clinical and oral findings and dental treatments of the patient with CSS.

## CASE REPORT

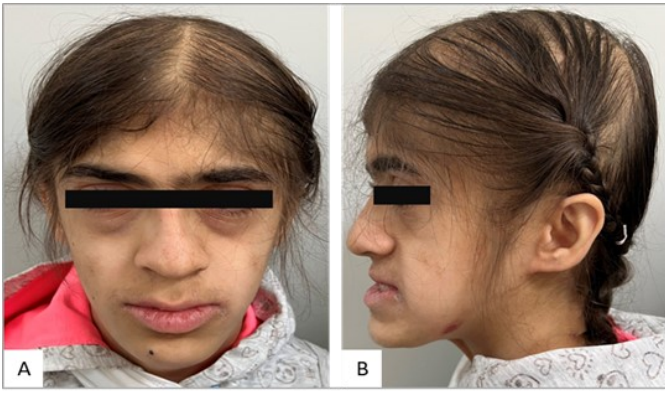A 15-year-old female patient applied to the Health Sciences University Department of Pediatric Dentistry, with complaints of missing upper right first incisor and sensitivity in the lower left first molar tooth. In the anamnesis taken by the family, it was stated that the patient had CSS. The patient was born with a low birth weight (2kg). She was referred to a genetic counseling center due to postnatal developmental delay as a result of receiving medical support as she could not walk or talk until the age of 2.5 years. As a result of genetic counseling, the patient was diagnosed with CSS at the age of 2.5. It was learned that there was no individual with a similar syndrome in the family, and the mother gave birth to the patient at the age of 40. The patient has multisystemic diseases such as epilepsy, recurrent seizures, upper respiratory tract infection, Fallot tetralogy, central serous retinopathy, hypotonia, eczema, and moderate mental retardation. The patient is under the control of the departments of internal medicine, neurology, ophthalmology, dermatology, orthopedics, and cardiology. The patient does not use any medication. On physical clinical examination, hypoplasia of the fingers and toes, which is the most prominent feature of CSS syndrome, and nail aplasia of the fifth toe was observed (Figure 1).

**Figure 1:** Hypoplasia of the fingers and toes; A) Hypoplasia of the fingers; B) Hypoplasia of the toes, and nail aplasia of the fifth toe

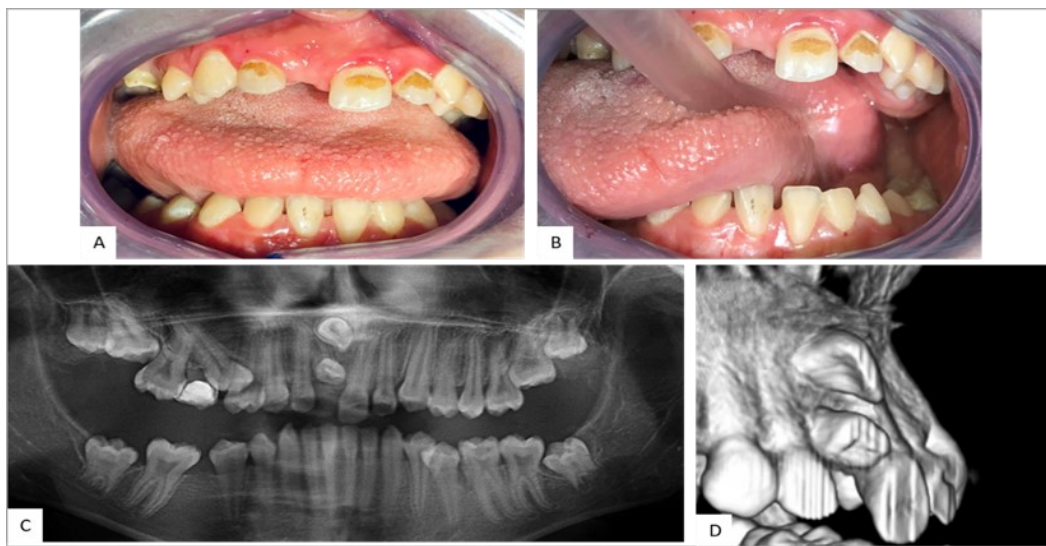

Craniofacial examination revealed she has brachycephaly, sparse hair, thick eyebrows and prominent eyelashes, broad nose, wide philtrum and mouth, flat nasal arch, coarse facial appearance, and skeletal class 3 closure (Figure 2).

**Figure 2:** Craniofacial appearance; A) Coarse facial appearance; B) Sparse hair, skeletal class 3 malocclusion



**Figure 3:** Intraoral and radiographic findings; A) Macroglossia, gingivitis, caries; B) Hyperplasia in the maxillary molar region; C) Initial panoramic image; D) CT image



As a result of the consultation with the orthodontics and oral surgery department, a treatment plan was devised. According to the treatment plan; restoration of decayed teeth was planned to alleviate the patient's pain, prevent sensitivity, and inhibit the progression of cavities. To prevent potential cystic

In the intraoral examination, gingival hyperplasia in the maxillary posterior molar region, poor oral hygiene, calculus, and plaque accumulation, gingivitis, macroglossia, delayed eruption in permanent second molars, the persistent primary second molar, white spot lesions in upper and lower anterior incisors, missing upper right first incisor tooth and caries of the upper left second incisor, lower left first molar, second premolar, lower right second molar and third molar, hypomineralization of upper right first molar and upper left second molar was detected (Figure 3 A, B). Panoramic radiography showed two radiopaque formations impacted in the upper right first incisor region, dentin caries in the lower left first molar and second premolar teeth, and enamel caries in the other teeth (Figure 3 C). As a result of computerized tomography (CT) from the maxilla to detect radiopaque formations and clarify their localization, it was determined that the radiopaque formations in the upper right first incisor region were supernumerary teeth and permanent first incisor (Figure 3 D).

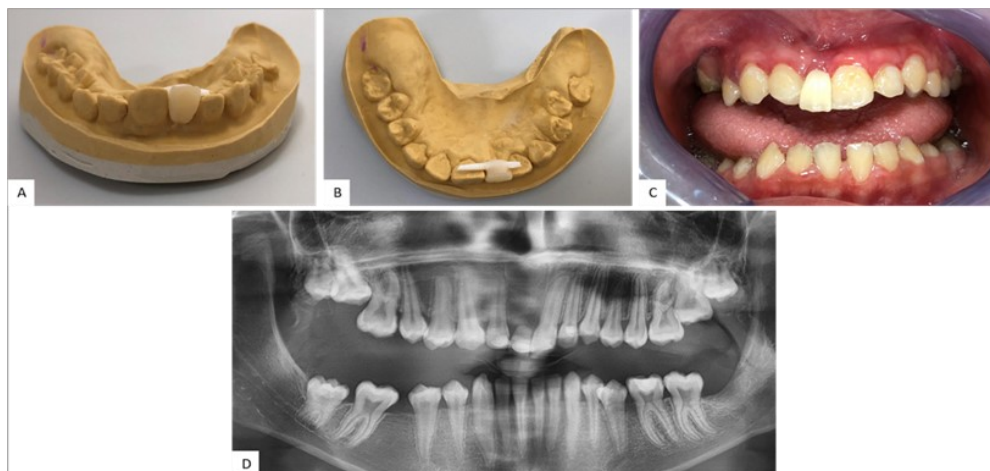
formations in the frontal region and mitigate the risk of impacted supernumerary and impacted permanent first incisor penetrating from the buccal side to the intraoral region, decisions were made to extract them. The extraction of the persistent primary second molar was determined due to its hindrance of the



eruption of the underlying premolar tooth. Additionally, the extraction of the lower left third molar was decided due to its eruptive position leading to the risk of resorption of the second molar and the potential for cavity formation. For the following appointments, a temporary Maryland bridge application to the upper right permanent first incisor region was planned to restore the patient's aesthetic appearance due to missing teeth. Furthermore, fluoride application was scheduled for the general remineralization of hypoplastic teeth, white spots, and to prevent dental caries. Then informed consent was obtained from the family. Since the patient was non-cooperative, treatment under general anesthesia was considered. As a treatment, after scaling and polishing (IMICRYL® Imprint Capsule Polishing Paste, Turkey), the lower left second premolar and first molar teeth with dentine caries were removed and restored with the glass ionomer liner (VOCO® Ionofil Molar, Germany) and composite filling (3M® Filtek Ultimate Universal Restorative, USA). Additionally, the composite filling was applied to the upper left second incisor, the lower right second molar, and third molar teeth, and glass ionomer liner was applied to the hypomineralized upper right first molar and upper left second molar teeth to prevent sensitivity and provide remineralization. After cleaning the perioral area with 10% povidone-iodine before the extraction procedures, local anesthesia was applied to the extraction areas with mepivacaine (SAFECAINE®, Turkey). The extraction of the upper right persistent primary second molar, impacted supernumerary teeth, and the lower left third molar was surgically performed.

After general anesthesia, maxillary teeth impression was taken for the Maryland bridge and fluoride varnish (IMICRYL® Polimo Fluoride Varnish, Turkey) was applied for white spot lesions. Oral hygiene education was given to the family and the patient. A 0.12% chlorhexidine mouthwash (KLOROBEN®, Turkey) was prescribed for home application. The Maryland bridge was designed using the patient's impacted permanent incisor. The root and crown part of the tooth was separated with an aerator and firstly shaped on the plaster model so as to adaptation of the crown part to the missing area and to provide ideal contact with the adjacent teeth (Figure 4 A). Since the patient will use the Maryland bridge temporarily, no reduction in the size of the adjacent teeth was made and no sockets were opened for the adjacent teeth to support the bridge. The shaped incisor crown was designed to receive support from adjacent teeth with a horizontally adapted fiber post (3M® Relyx Fiber Post, USA) to its palatal side (Fig. 4 B). The following appointment, acid-bond were applied to adjacent teeth and fiber post, the connection between the teeth and the post was provided with the flowable composite (3M® Filtek Ultimate Flowable, USA). After checking the occlusal contact, the Maryland bridge application was completed, and a panoramic x-ray was taken after the treatment (Figure 4 C, D). The patient is still being followed up. The patient will use a Maryland bridge until osseous and dental growth development is completed, and then an evaluation for implant application will be made with the oral surgery department.

**Figure 4:** Post-treatment Maryland bridge application; A) Maryland bridge application; B) Palatal view of the Maryland bridge; C) Intraoral view; D) Post-operative panoramic image



## DISCUSSION

CSS is a rare, autosomal inherited, multisystemic disease caused by mutations in genes encoding components of the BRG-1-related factor (BAF) complex.<sup>6</sup> It is a clinically difficult syndrome to diagnose because there is a great deal of phenotype variability in CSS and most of the features seen in patients are not specific to the syndrome. Criteria specific to this syndrome have been proposed to help clarify the clinical diagnosis.<sup>14</sup> Growth and developmental delay, hirsutism, coarse facial appearance, fifth finger hypoplasia, or nail agenesis are the most common findings.<sup>15</sup> Our patient also had the findings mentioned above in the hand and face region.

CSS is classified into types A and B based on various clinical findings that vary with the type of gene in which the mutation occurs.<sup>12,14</sup> Schrier's classification based on clinical findings, Type A and B distinction is made according to eyebrow and lip thickness, thick eyebrows and lips are classified as type A/classic CSS and thin eyebrows and lips are classified as type B/variant CSS.<sup>14</sup> In our case, our patient has Type A CSS because she has thick eyebrows and lips.

Cardiac defects (ventricular septal defects, atrial septal defects), genital anomalies (cryptorchidism, hypospadias, and absence of uterus), renal anomalies (fused or small kidneys), and multisystemic problems such as inguinal or umbilical hernias, recurrent infections are seen in patients with CSS.<sup>15,16</sup> The most common organ-related problems are congenital heart defects (46%).<sup>2</sup> In such patients, consultation with the relevant departments and, if necessary, antibiotic prophylaxis before treatment depending on the type of procedure is recommended to reduce the risk of bacteremia.<sup>17,18</sup> Since our patient had epilepsy and Fallot tetralogy, consultation was obtained with the relevant departments. Especially, due to the presence of Fallot tetralogy in our patient, following consultation with the cardiology department, it has been deemed appropriate to administer antibiotic prophylaxis before general anesthesia and to use a local anesthetic solution without vasoconstrictor/adrenaline for tooth extractions. Therefore, mepivacaine has been preferred as the local anesthetic solution.

Being aware of the facial and oral findings of patients with CSS is important for the right treatment in

terms of dentistry and referral to the relevant departments. According to the literature coarse facial appearance, sparse hair, thick eyebrows, bushy eyelashes, large-wide nose and lips, flat nasal bridge, thin vermilion in the upper lip, thick vermilion in the lower lip, cleft palate, microcephaly, abnormal ears, short/long philtrum are among the craniofacial findings of patients with CSS.<sup>5,8,19,20</sup> Our patient had findings other than the cleft palate, microcephaly, and abnormal ear. The cases which evaluate the intraoral findings of CSS are limited in the literature. There are only 2 cases in the literature, that present dental evaluation and treatment options.<sup>3,10</sup> In the literature, patients with CSS have an intraorally deep palate, bifid uvula, macroglossia, dental anomalies, abnormal gingival hyperplasia, late eruption, teeth with large diastema, irregular teeth, hypoplasia of teeth, conical tooth roots, poor oral hygiene, and periodontal problems.<sup>3,10,14,15,21</sup> In our case, in line with the literature, poor oral hygiene, and calculus, plaque accumulation, gingivitis, caries, macroglossia, gingival hyperplasia in the maxillary posterior molars, missing teeth, hypomineralization, delayed eruption, and impacted permanent teeth were detected.

Dental treatments in children with syndromes or disabilities with special care can be performed with pharmacological (sedation and general anesthesia) and non-pharmacological methods (tell-show-do, positive encouragement, distraction, voice control, hypnosis, etc.).<sup>22</sup> Since CSS is a multisystemic syndrome clinically and patients have vision-hearing problems and varying degrees of mental retardation, treatments can be performed with pharmacological and non-pharmacological techniques.<sup>21,23</sup> Especially when non-pharmacological techniques will be preferred, communication with the patient, showing and explaining the procedures have great importance in point of providing cooperation. In a case report in the literature, due to the challenging patient cooperation and the urgency of treatment in a patient with Coffin-Siris syndrome protective stabilization involving active immobilization was implemented. This process included restraint by the parents and dental auxiliary. Before resorting to protective stabilization, alternative behavioral approaches were employed to reduce movement and resistance and enhance cooperation during dental care for special-needs patients. These

approaches included distraction, shaping, modeling, and reinforcement.<sup>10</sup> In our case, dental and surgical treatments were performed under general anesthesia due to the patient's high anxiety and mental retardation. However, in the following appointments, fluoride and Maryland bridge applications were performed using the tell-show-do technique.

The prevalence of dental caries and periodontal diseases is higher in children with special needs, due to reasons such as physical limitations, mental retardation, lack of cleaning habits, and attitudes of parents.<sup>3,24</sup> In the literature, there are findings of poor oral hygiene, gingivitis, multiple dental caries, and generalized gingivitis in CSS patients for similar reasons.<sup>3,10</sup> Therefore, oral hygiene education is of paramount importance in such patients. As for that, the brushing ability of the patient or if the patient is unable to brush at all, showing the family to brush teeth and using agents such as chlorhexidine with gauze, toothbrush, or rinsing method will reduce the burden on the oral microbiota.<sup>3</sup> Moreover, applying topical cream containing casein phosphopeptide amorphous calcium phosphate to the teeth to prevent caries formation and to support remineralization is among the applications that the patient and family can do at home. In the clinical setting, fluoride and sealant applications should be applied as a preventive treatment. Moreover, in case reports documented in the literature concerning patients with Coffin-Siris syndrome, it is emphasized that, particularly in this patient group, the continuity of a personalized protective program is crucial. This program focuses on monitoring the patient's nutrition, oral hygiene, and providing oral hygiene education to the child and family during each follow-up session.<sup>3,10</sup> Since our patient had poor oral hygiene, multiple caries, and gingivitis, oral hygiene education was given to the patient and the family. Since the patient was able to brush her teeth, an appropriate tooth-brushing technique was shown, and she was asked to use chlorhexidine at home. Fluoride was applied in the clinical setting for remineralization of hypoplastic teeth and white spot lesions and prevention of caries formation. It was observed that the oral hygiene motivation of the patient increased in the control appointments.

Tooth missing that occurs congenitally or because of trauma cause midline shifts and unequal spaces. This situation creates aesthetic, functional problems, and low self-confidence, especially in adolescents.<sup>25</sup> Implant application in the growth and development age is still a controversial issue.<sup>26</sup> The biggest concern in implant placement in children and young patients is tooth and skeletal development. Implant position, growth effect on the tooth, and skeletal growth impose some limitations on typical implant applications in these patients.<sup>27</sup> Therefore, removable prosthesis or resin-bonded Maryland bridges are preferred for the rehabilitation of missing teeth.<sup>26</sup> As a result of consultation with the orthodontic clinic, the orthodontic treatment option was eliminated due to the presence of mental retardation and very low foreign body tolerance in our patient. Since the typical findings of CSS such as delayed growth development and dentition were present in our patient, the Maryland bridge application, designed from the patient's teeth, was performed as a temporary treatment for both the functional and aesthetic maintenance of the anterior missing region. Additionally, in the literature on reported cases of Coffin-Siris syndrome, the presence of missing, supernumerary, or impacted teeth, as observed in our case, has not been documented.

The patient is still being followed up. When the growth-development and dentition process is completed, an evaluation will be made for the implant application with the oral surgery department.

## CONCLUSION

CSS is a rarely seen syndrome, and there are few cases of the syndrome specific to dental findings in the literature. Hence, the dental findings specific to the syndrome have not been fully clarified. Patients requiring special care such as CSS are at risk for dental problems by virtue of physical and mental limitations compared to healthy people. In these patients, it is important to know the general clinical and systemic findings of the syndrome, consult with the relevant departments, and determine the appropriate treatment method accordingly. Oral hygiene education and preventive applications constitute the key point in terms of dental health in these patients, as in every patient.

### ETHICAL COMMITTEE APPROVAL

Since sources obtained from humans or animals were not used in this study, ethics committee approval was not received.

### FINANCIAL SUPPORT

The authors declare that this study received no financial support.

### CONFLICT OF INTEREST

The authors deny any conflicts of interest related to this study.

### AUTHOR CONTRIBUTIONS

Design: NIEY, CF, Data collection and processing: NIEY, Analysis and interpretation: NIEY, CA, GGP Literature review: NIEY, Writing: NIEY, CA

### REFERENCES

1. Coffin GS, Siris E. Mental retardation with absent fifth fingernail and terminal phalanx. *Am J Dis Child.* 1970;119:433-9.
2. Vergano SS, Deardorff MA. Clinical features, diagnostic criteria, and management of Coffin-Siris syndrome. *Am J Med Genet C.* 2014;166:252-6.
3. Mustafa S, Ahmed R, Goel S, Medicine O, Subharti R, Pradesh U. Coffin Siris syndrome : a rare case report. *Indian J Res.* 2016;5:558-9.
4. Vasko A, Drivas TG, Schrier Vergano SA. Genotype-phenotype correlations in 208 individuals with Coffin-Siris syndrome. *Genes (Basel).* 2021;12:937.
5. McCague EA, Lamichhane R, Holt N, Schrier Vergano SA. Growth charts for individuals with Coffin-Siris syndrome. *Am J Med Genet A.* 2020;182:2253-62.
6. Mannino EA, Miyawaki H, Santen G, Schrier Vergano SA. First data from a parent-reported registry of 81 individuals with Coffin-Siris syndrome: natural history and management recommendations. *Am J Med Genet A.* 2018;176:2250-8.
7. Kosho T, Miyake N, Carey JC. Coffin-Siris syndrome and related disorders involving components of the BAF (mSWI/SNF) complex: historical review and recent advances using next generation sequencing. *Am J Med Genet C.* 2014;166:241-51.
8. Divakar D, Ubale PV, Gujjar P. Anesthetic management of a patient with Coffin-Siris syndrome. *JRIA.* 2019;4:16-8.
9. Park H, Kim MS, Kim J, Jang JH, Choi JM, Lee SM, et al. A boy with Coffin-Siris syndrome with a novel frameshift mutation in ARID1B. *Neuro Endocrinol Lett.* 2021;41:285-9.
10. Figueira HS, Medina PO, de Jesus GP, Hanan ARA, Júnior ECS, Hanan S. Oral findings in Coffin-Siris syndrome: a case report. *Rev Port Estomatol Med Dent Cir Maxilofac.* 2021;62:42-9.
11. Curcio MR, Ferranti S, Lotti F, Grosso S. Coffin-Siris syndrome and epilepsy. *J Neurol Sci.* 2021;42:727-9.
12. Zarate YA, Bhoj E, Kaylor J, Li D, Tsurusaki Y, Miyake N, et al. SMARCE1, a rare cause of Coffin-Siris syndrome: clinical description of three additional cases. *Am J Med Genet A.* 2016;170:1963-7.
13. Boerstler T, Wend H, Krumbiegel M, Kavyanifar A, Reis A, Lie DC, et al. CRISPR/Cas9 mediated generation of human ARID1B heterozygous knockout hESC lines to model Coffin-Siris syndrome. *Stem Cell Res.* 2020;47:101889.
14. Schrier SA, Bodurtha JN, Burton B, Chudley AE, Chiong MA, D'Avanzo MG, et al. The Coffin-Siris syndrome: a proposed diagnostic approach and assessment of 15 overlapping cases. *Am J Med Genet A.* 2012;158A:1865-76.
15. Fleck BJ, Pandya A, Vanner L, Kerkerling K, Bodurtha J. Coffin-Siris syndrome: review and presentation of new cases from a questionnaire study. *Am J Med Genet.* 2001;99:1-7.
16. Ozkan AS, Akbas S, Yalin MR, Ozdemir E, Koyulu Z. Successful difficult airway management of a child with Coffin-Siris syndrome. *Clin Case Rep.* 2017;5:1312-4.
17. Rutherford SJ, Glennly AM, Roberts G, Hooper L, Worthington HV. Antibiotic prophylaxis for preventing bacterial endocarditis following dental procedures. *Cochrane Database of Syst Rev.* 2022;5:CD003813.
18. Daly CG. Antibiotic prophylaxis for dental procedures. *Aust Prescr.* 2017;40:184-8.
19. Natsume T, Takano K, Motobayashi M, Kosho T. Hepatomegaly in a boy with ARID1B-related Coffin-Siris syndrome. *Pediatr Int.* 2018;60:378-80.
20. Tsurusaki Y, Okamoto N, Ohashi H, Mizuno S, Matsumoto N, Makita Y, et al. Coffin-Siris syndrome is a SWI/SNF complex disorder. *Clin Genet.* 2014;85:548-54.
21. Fujita T, Ihara Y, Hayashi H, Ishii A, Ideguchi H, Inoue T, et al. Coffin-Siris syndrome with bilateral macular dysplasia caused by a novel exonic deletion in ARID1B. *Congenit Anom (Kyoto).* 2020;60:189-93.



22. Baakdah RA, Turkistani JM, Al-Qarni AM, Al-Abdali AN, Alharbi HA, Bafaqih JA, et al. Pediatric dental treatments with pharmacological and non-pharmacological interventions: a cross-sectional study. *BMC Oral Health*. 2021;21:186.
23. Kosho T, Okamoto N, Ohashi H, Tsurusaki Y, Imai Y, Hibi-Ko Y, et al. Clinical correlations of mutations affecting six components of the SWI/SNF complex: detailed description of 21 patients and a review of the literature. *Am J Med Genet A*. 2013;161:1221-37.
24. Sardana D, Goyal A, Gauba K, Kapur A, Manchanda S. Effect of specially designed oral health preventive programme on oral health of visually impaired children: use of audio and tactile aids. *Int Dent J*. 2019;69:98-106.
25. Arandi NZ, Mustafa S. Maxillary lateral incisor agenesis; a retrospective cross-sectional study. *Saudi Dent J*. 2018;30:155-60.
26. Hegde R, Sargod S, Baliga S, Raveendran R. Transitional dental implant in adolescent patient- a narrative review. *J Indian Soc Pedod Prev Dent*. 2021;39:347-52.
27. Moghadam MM. Implant applications for children. *Int J Contemp Den Med Rev*. 2017;7:1-7.