

Calculi migration into the left renal vein during percutaneous nephrolithotomy: a rare complication and literature review

Perkütan nefrolitotomi esnasında sol renal vene kalkül migrasyonu: nadir bir komplikasyon ve literatür taraması

Eser Ördek, Fatih Gökalp, Bilal Kulak, Ferhat Uçurmak, Sadık Görür

Posted date:06.02.2024

Acceptance date:11.03.2024

Abstract

Percutaneous nephrolithotomy (PCNL) has long been the standard treatment of choice for the management of large and complex renal calculi. PCNL is a safe and well-tolerated surgical procedure when performed systematically and correctly; however, as with any surgical intervention, although mild complications may occur in this surgery, serious complications may also occur. In this article, we report a rare case of migration of residual calculi into the renal vein during PCNL surgery and aim to present its presentation, treatment and management in a tertiary care center.

Keywords: Percutaneous nephrolithotomy, renal vein injury, thrombosis, anticoagulant therapy.

Ördek E, Gokalp F, Kulak B, Ucurmak F, Gorur S. Calculi migration into the left renal vein during percutaneous nephrolithotomy: a rare complication and literature review. Pam Med J 2024;17:796-802.

Öz

Üriner sistem taş hastalıklarının cerrahi tedavisinde perkütan nefrolitotomi (PCNL) ameliyatı, uzun yıllardır büyük hacimli ve kompleks böbrek taşlarının tedavisinde sık tercih edilen standart bir tedavi haline gelmiştir. PCNL sistematik ve doğru şekilde yapıldığında güvenilir ve iyi tolere edilebilen cerrahi bir prosedürdür; ancak herhangi bir cerrahi müdahalede olduğu gibi bu ameliyatta da basit olmakla beraber ciddi komplikasyonlar da gelişebilmektedir. Bu yazıda, PCNL ameliyatı sırasında rezidü kalkülün renal vene migrasyonu olan nadir bir olguyu sunarak bunun üçüncü basamak bir merkezde ortaya çıkışını, tedavisini ve nasıl yönetildiğini sunmayı amaçladık.

Anahtar kelimeler: Perkütan nefrolitotomi, renal ven yaralanması, trombozis, antikoagulan tedavi.

Ördek E, Gökalp F, Kulak B, Uçurmak F, Görür S. Perkütan nefrolitotomi esnasında sol renal vene kalkül migrasyonu: nadir bir komplikasyon ve literatür taraması. Pam Tıp Derg 2024;17:796-802.

Introduction

Percutaneous nephrolithotomy (PCNL) in the surgical treatment of urinary tract stone diseases was first introduced by Fernström and Johansson [1] in 1976 and has become the most preferred treatment technique for large volume and complex renal stones. PCNL is typically a safe and well-tolerated surgical procedure when performed systematically and correctly; however, as with any surgical intervention, PCNL can also develop serious complications, although they are often simple [2]. Puncturing

the renal system through the appropriate calyx and subsequent dilatation are the two most important critical steps in PCNL. The majority of complications in PCNL operations occur most frequently during these two steps.

Studies have reported complication rates for PCNL ranging from 20-83% [3]. Common complications are minor, and the Clavien grade I, II, III, IV and V complication rates in the literature are 11.1%, 5.3%, 3.6%, 0.5% and 0.03%, respectively [3]. The most common minor complications after percutaneous

Eser Ördek, Asst. Prof. Hatay Mustafa Kemal University, Faculty of Medicine, Department of Urology, Hatay, Türkiye, e-mail: dr_eserer@hotmail.com (<https://orcid.org/0000-0001-6737-4259>) (Corresponding Author)

Fatih Gökalp, Assoc. Prof. Hatay Mustafa Kemal University, Faculty of Medicine, Department of Urology, Hatay, Türkiye, e-mail: fatihgokalp85@gmail.com (<https://orcid.org/0000-0003-3099-3317>)

Bilal Kulak, Asst. Prof. Hatay Mustafa Kemal University, Faculty of Medicine, Department of Urology, Hatay, Türkiye, e-mail: balakulak@hotmail.com (<https://orcid.org/0000-0002-8630-0797>)

Ferhat Uçurmak, Asst. Prof. Hatay Mustafa Kemal University, Faculty of Medicine, Department of Urology, Hatay, Türkiye, e-mail: f.ucurmak@gmail.com (<https://orcid.org/0000-0002-0513-8944>)

Sadık Görür, Prof. Hatay Mustafa Kemal University, Faculty of Medicine, Department of Urology, Hatay, Türkiye, e-mail: sadikgorur@yahoo.com (<https://orcid.org/0000-0002-3458-5428>)

nephrolithotomy are drainage tube leakage (15%) and transient fever (10-30%) [4]. Less common but serious complications of PCNL (Clavien grades III, IV and V) are usually associated with percutaneous access to the renal collecting system and include adjacent organ injury, renal hilum injury, pleural injury, massive bleeding or urosepsis.

Bleeding that occurs during percutaneous nephrolithotomy procedures is mainly venous and usually mild. Most of the time, bleeding resolves by self-limiting or responds positively to correct and appropriate maneuvers such as placement of a large-caliber percutaneous nephrostomy drainage tube into the system [5]. In addition, although injury to the main renal vascular structures is rare with a rate of 0.5-2.4%, it is one of the complications that can be quite serious and its treatment is difficult [6].

In our literature review, calculi migration into the renal vein has not been reported before and our case will be the first reported case. In this article, we aimed to present the management of calculi migrated into the renal vein during PCNL surgery in an asymptomatic patient in the light of current literature.

Case presentation

A 45-year-old female patient with operation history for breast, ovarian, rectal cancer, thyroid cancer and chemo-radiotherapy treatments due to these comorbidities and Glanzman thrombocytopenia presented to our urology clinic with left flank pain. Investigations revealed a 2.8 cm stone extending from the lower pole of the left kidney to the renal pelvis and several millimetric calculi in the lower pole of the kidney (Figure 1). The patient was planned to be performed with PCNL. Written informed consent was obtained from the patient and the procedure was performed by experienced urologists under general anesthesia. After retrograde catheterization with a 6 Fr ureteral stent in the left ureteral orifice in the lithotomy position, a 14 Fr foley catheter was inserted and the patient was turned to the prone position. Contrast material was injected through the ureteral stent and the left renal pelvicalyceal system was visualized. Under C-arm fluoroscopy guidance, percutaneous access was made from the posterior lower pole calyx. Tract dilatation was

performed using coaxial serial Teflon-coated renal dilators under coherent scope images. Finally, a 28 Fr amplatz sheath was placed and a 26 Fr nephroscope was used for the procedure. During nephroscopic examination of the lower pole calyx and renal pelvis, intense venous bleeding was observed from the irrigation fluid drain of the nephroscope. However, no intrapelvic hemorrhage or hematuria from the foley catheter was observed. Operation was continued and bleeding was controlled by placing an amplatz sheath over the bleeding pathway. Then, using the automatic pressure irrigation device (Figure 2) in the system, the pressure was kept slightly high and the stones in the lower pole and renal pelvis were rapidly and carefully fragmented with using pneumatic lithotripter and extracted with stone forceps. Meanwhile, mucosal injury was observed in the renal pelvis, but the procedure was continued because there was no evidence of extravasation or serious bleeding. The patient had slightly low blood pressure since the beginning of the procedure and was given one unit of erythrocyte suspension intraoperatively and fluid replacement according to anesthesia recommendations. However, considering the serious comorbidities of the patient, it was decided to terminate the procedure before complete stone-free status was achieved. A 16 Fr malecot catheter was placed and used as a nephrostomy tube at the end of the procedure. Contrast material was injected through the nephrostomy tube and it was observed that the pelvicalyceal system was compact and the contrast material passed from the renal pelvis to the ureter (Figure 3). The nephrostomy tube was fixed to the skin, the valve of the tube was closed and the renal area was compressed for approximately 15 minutes.

The patient followed in the intensive care unit for 24 hours. Urine from both the urethral foley catheter and nephrostomy tube was clear and the patient was hemodynamically stable. First postoperative day, the patient was transferred to the urology service, the foley catheter was removed and mobilization was provided. The patient's hemodynamics was stable and hemoglobin was not decreased. The nephrostomy tube valve was closed before the tube withdrawn.

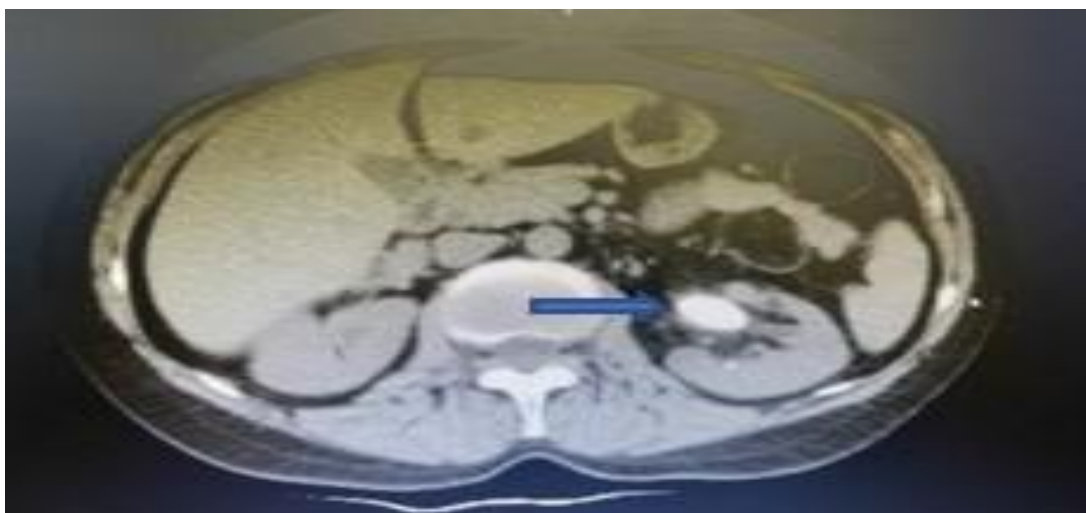


Figure 1. Stone in the renal pelvis, pre-operative CT image, (blue arrow)



Figure 2. Automatic pressure irrigation instrument

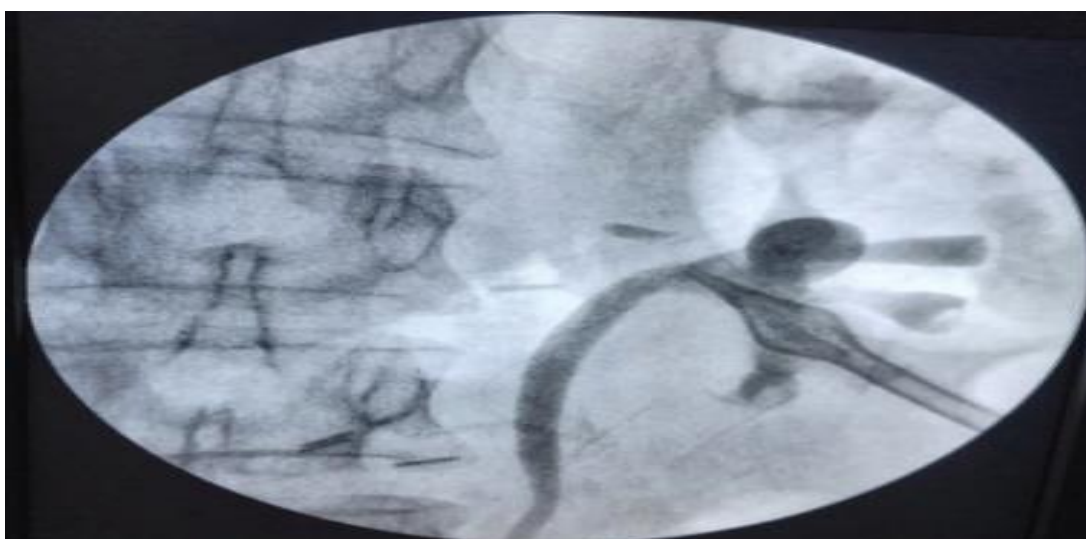


Figure 3. Percutaneous nephrostomy and antegrade pyelography image

On the second postoperative day, the patient had left renal colic and mild wetting near the tube entry site. The nephrostomy tube was opened and a non-contrast whole abdominal computed tomography (CT) was performed. CT scan showed several residual calculus near the nephrostomy tube in the renal pelvis and an opacity with a diameter of approximately 8 mm in the vascular structure thought to be the left renal vein (Figure 4). The patient was consulted with the radiology clinic. The patient was confirmed that she had Nutcracker syndrome and the presence of a stone in the dilated renal vein. Renal doppler ultrasonography was performed and renal artery-vein flow was normal. Since the patient had additional comorbidities such as malignancy, she was consulted to the specialists of Cardiovascular Surgery, Hematology and Interventional Radiology departments against

the risk of thromboembolism. The patient also had Glanzman thrombocytopenia and it was decided to start enoxaparin treatment. The stone in the renal vein was considered unlikely to pass to the vena cava due to Nutcracker syndrome and the patient was asymptomatic; so invasive angiography or open surgical stone extraction was not considered primarily. The patient was managed conservatively with anticoagulation therapy. A double j (DJ) stent was placed under fluoroscopy and contrast dye guidance, and the nephrostomy tube was extracted (Figure 5). The extravasation into the renal vein or outside of the pelvis was not observed. The patient was kept under observation for a week after surgery and parenteral antibiotics and anticoagulant treatment were given. She was discharged with recommendations due to her general condition and clinical stability.

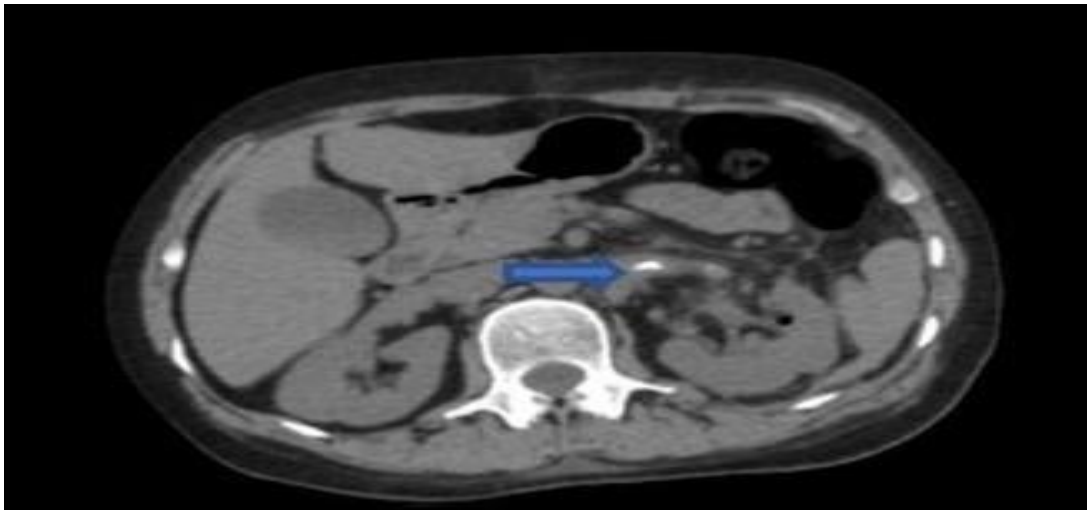


Figure 4. Calculus migrating into the renal vein, (blue arrow)

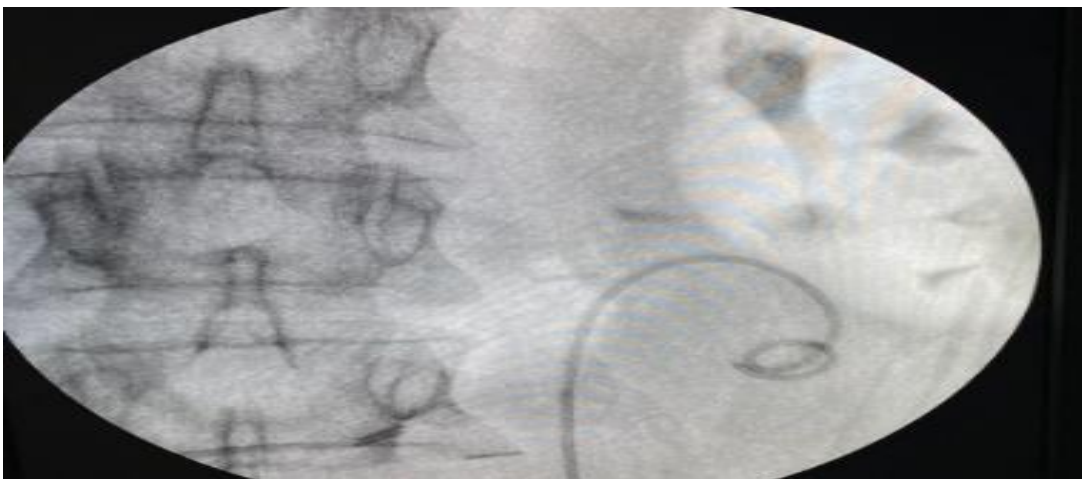


Figure 5. Removal of nephrostomy tube and insertion of DJ

The patient continued to receive anticoagulation and prophylactic antibiotics for three months after surgery. DJ was extracted in the 3rd postoperative month. During the follow-up period of approximately 4 months, the patient remained asymptomatic without developing any thrombotic events, hematuria, or signs of infection. In serial imaging, it was observed that the stone was stably positioned in the renal vein and impacted the endothelium. Additionally, anticoagulant therapy was well tolerated without any side effects.

Discussion

Percutaneous nephrolithotomy has an important place especially in renal stone surgery in our country, where the incidence of nephrolithiasis is high, and is now widely practiced. Ideally, it should be performed in centers with the support of a multidisciplinary team consisting of experienced anesthesiologists and radiologists, and with the possibility of an intensive care unit where patients can be followed up if necessary to ensure the best surgical success. Preoperative multidetector CT imaging helps in surgical planning and initial access to the kidney, especially in large and complex kidney stones. It may also help to predict stone-free rates [7]. Performing appropriate puncture in the appropriate calyx and correct calyceal dilatation are the most critical steps in achieving complete stone-free by fragmenting and extracting the stones appropriately.

Sometimes the puncture needle or axial dilators may injure the renal parenchyma and move towards the renal vein or even major vascular structures such as the vena cava. In addition, the risk of injury during PCNL becomes higher when the renal vein is closer to renal pelvis and posterior calyx [8]. Our patient had a millimetric stone in the lower pole and a 2.8 cm stone in the renal pelvis. This stone, which was known to have been present for a long time, and the associated inflammation may have made the renal pelvis wall and surrounding structures weaker. In addition, the patient's history of malignancy, chemotherapy and radiotherapy treatment may have made the renal parenchyma and surrounding vascular structures more fragile.

Bleeding is one of the most common clinical complications in PCNL surgery. Massive bleeding and related complications may accelerate organ damage or lose and may lead to mortality if managed improperly [9]. Bleeding usually occurs commonly due to injury of the anterior or posterior segmental arteries; however, this complication can be prevented by performing renal puncture in the posterolateral plane along the avascular line known as the Brödel line [10].

The great vessels and the main renal vascular system injury usually occur during initial percutaneous access. One of the best ways to avoid large vessel injuries is to approach percutaneous renal access in a systematic manner and to carefully evaluate imaging of the renal parenchyma and vasculature prior to the procedure. Bleeding with initial percutaneous access and amplatz dilatation is usually venous in nature and may originate from the skin, muscle, renal capsule or renal parenchyma. Mild or moderate hemorrhages can often be controlled with tamponade and a large caliber nephrostomy tube. Nowadays, with further miniaturization of surgical equipment and novel techniques, blood transfusion rates were decreased significantly from 6.9% in the first series to less than 2% [4].

PCNL is actually an important kidney stone surgery and there is a consensus on what should be done in cases of vascular injuries that may disrupt the patient's hemodynamics. However, unfortunately, there is no clear literature information about complications such as stone migration into the vascular structure, which does not disrupt hemodynamics, as in our case example. PCNL causes controlled grade IV damage to the kidney according to the American Association for the Surgery of Trauma renal injury classification [11]. Grade IV injury also includes renal vein and artery injury. According to the trauma literature, even damage to the main vascular structures can often be treated with angioembolization without the need for open surgery. Renal vein injury during PCNL is a serious complication and should be timely diagnosed and treated correctly.

Actually, Aggarwal et al. [12] reported a patient in whom the nephrostomy tube pierced the renal parenchyma and injured the renal vein during PCNL in another center and nephrectomy was performed. Intraoperative or postoperative severe venous hemorrhage, profound hypotension or massive hematuria that disrupts vital signs should raise suspicion of possible injury to the main renal vascular structures.

Although the normal renal vein pressure is 12-15 cm H₂O, the pressure of the irrigation fluid in the renal collecting system should be kept under this value. The irrigation fluid is in an open system and flows freely both through the edge of the nephroscope and through the amplatz sheath. In our case, the fact that we used continuous irrigation fluid with automatic pressure and the patient had fragile tissue weakness due to additional comorbidities may have triggered renal vein mucosal damage. Therefore, the irrigation fluid should be adjusted minimal pressure in patients with comorbidities and especially in patients who have received chemotherapy-radiotherapy.

Patients should be given blood and fluid replacement according to the amount of bleeding, hemodynamic findings and low hemoglobin. Intravenous broad-spectrum antibiotic treatment should be given to prevent possible bacteremia or sepsis in the presence of foreign bodies such as stones or guidewire tips in the renal venous system. In our clinic, routine prophylactic and postop parenteral third-generation cephalosporin antibiotherapy is given in patients undergoing PCNL surgery. However, we did not observe any fever, hematuria, low hemoglobin or hemodynamic instability in our patient both intraoperatively and postoperatively, which ruled us out renal vascular system damage.

In our case, low, single-dose anticoagulant therapy was given in consultation with hematology and cardiovascular surgery specialists because the patient had platelet dysfunction and radiologic evidence of renal vein nutcracker syndrome. In addition, since the renal vein system is a high-flow but low-pressure system and the risk of thrombosis is relatively lower compared to other vessels, there is still no definitive literature information regarding anticoagulation treatment [13].

However, Zumrutbas et al. [14], in a case report published in 2016, stated that PCNL can be safely performed in patients with rare bleeding disorders. Additionally, surgical care of patients with congenital and rare bleeding disorders should only be performed in hospitals where a multidisciplinary team, including the surgeon and an experienced hematologist, collaborates.

As in our case, it can sometimes be difficult to recognize and diagnose renal vein injury intraoperatively. Short-term staining in vascular structures on antegrade pyelography performed by administering a contrast medium through the nephrostomy placed at the end of the operation may provide us with an idea. In addition, in a patient who is hemodynamically stable in terms of vital signs, complications such as arteriovenous fistula, aneurysm or pseudoaneurysm should come to mind in clinical situations such as persistent macroscopic hematuria or self-limited hematoma. Such complications can be successfully treated with angioembolization or other endovascular interventions along with conservative treatment and close follow-up [15].

To our knowledge, this is the first and only case of renal vein injury and stone migration to the renal vein during PCNL. In addition, despite the major vascular damage, the absence of clinical picture and the anatomical variation of the patient allowed the patient to be followed and treated with a conservative approach. The patient's multiple malignancies, platelet dysfunction, history of chemotherapy-radiotherapy and untreated renal pelvic calculi for many years made PCNL surgery high-risk. Also, the presence of radiologic Nutcracker syndrome increased the risk of possible vein damage by making the renal vein more dilated than normal, prevented the calculi migrating into the renal vein from migrating to the vena cava and impinged on the renal vein endothelium.

As a result, it is important to correctly determine the focus of bleeding and the cause of bleeding in percutaneous nephrolithotomy surgery. The presence of intraoperative venous bleeding or the absence of any serious clinical and vital sign disturbance during postoperative follow-up usually reduces the likelihood of major vascular injury. However, in suspected complicated cases and especially in patients with high comorbidities, prompt postoperative imaging, even in the absence of obvious

symptoms, will help in the early detection of possible vascular injury and complications. In addition, asymptomatic migration of the stone into the renal vein during PCNL causes diagnostic difficulties and treatment strategies require a balanced approach between surgical intervention and observation.

Conflict of interest: No conflict of interest was declared by the authors.

References

1. Fernström I, Johansson B. Percutaneous pyelolithotomy. A new extraction technique. *Scand J Urol Nephrol* 1976;10:257-259. <https://doi.org/10.1080/21681805.1976.11882084>
2. Rudnick DM, Stoller ML. Complications of percutaneous nephrostolithotomy. *Can J Urol* 1999;6:872-875.
3. de la Rosette J, Assimos D, Desai M, et al. The clinical research office of the endourological society percutaneous nephrolithotomy global study: indications, complications, and outcomes in 5803 patients. *J Endourol* 2011;25:11-17. <https://doi.org/10.1089/end.2010.0424>
4. Shin TS, Cho HJ, Hong SH, Lee JY, Kim SW, Hwang TK. Complications of percutaneous nephrolithotomy classified by the modified Clavien grading system: a single center's experience over 16 years. *Korean J Urol* 2011;52:769-775. <https://doi.org/10.4111/kju.2011.52.11.769>
5. Galek L, Darewicz B, Werel T, Darewicz J. Haemorrhagic complications of percutaneous lithotripsy: original methods of treatment. *Int Urol Nephrol* 2000;32:231-233. <https://doi.org/10.1023/a:1007126900772>
6. Poudyal S. Current insights on haemorrhagic complications in percutaneous nephrolithotomy. *Asian J Urol* 2022;9:81-93. <https://doi.org/10.1016/j.ajur.2021.05.007>
7. Klein I, Gutiérrez Aceves J. Preoperative imaging in staghorn calculi, planning and decision making in management of staghorn calculi. *Asian J Urol* 2020;7:87-93. <https://doi.org/10.1016/j.ajur.2019.07.002>
8. Sampaio FJ. The dilemma of the crossing vessel at the ureteropelvic junction: precise anatomic study. *J Endourol* 1996;10:411-415. <https://doi.org/10.1089/end.1996.10.411>
9. Zhang LW, Fei X, Song Y. The clinical efficacy of novel vacuum suction ureteroscopic lithotripsy in the treatment of upper ureteral calculi. *World J Urol* 2021;39:4261-4265. <https://doi.org/10.1007/s00345-021-03722-5>
10. Nunes TF, Tibana TK, Santos RFT, Carramanho Junior JDC, Marchiori E. Percutaneous insertion of bilateral double J stent. *Radiol Bras* 2019;52:104-105. <https://doi.org/10.1590/0100-3984.2017.0230>
11. Coccolini F, Moore EE, Kluger Y, et al. Kidney and uro-trauma: WSES-AAST guidelines. *World J Emerg Surg* 2019;14:54(e1-25). <https://doi.org/10.1186/s13017-019-0274-x>
12. Aggarwal A, Bhargava P, Bhirud DP. Renal vein injury during percutaneous nephrolithotomy: a surgical catastrophe - Management and lessons learned. *Indian J Urol* 2022;38:309-311. https://doi.org/10.4103/iju.iju_241_22
13. Ge G, Wang Z, Wang M, Li G, Xu Z, Wang Y, Wan S. Inadvertent insertion of nephrostomy tube into the renal vein following percutaneous nephrolithotomy: a case report and literature review. *Asian J Urol* 2020;7:64-67. <https://doi.org/10.1016/j.ajur.2018.06.003>
14. Zumrutbas AE, Toktas C, Baser A, Tuncay OL. Percutaneous nephrolithotomy in rare bleeding disorders: a case report and review of the literature. *J Endourol Case Rep* 2016;2:198-203. <https://doi.org/10.1089/cren.2016.0105>
15. Martin X, Murat FJ, Feitosa LC, et al. Severe bleeding after nephrolithotomy: results of hyperselective embolization. *Eur Urol* 2000;37:136-139. <https://doi.org/10.1159/000020129>

Informed consent: Written informed consent was obtained from the patient.

Authors' contributions to the article

E.O. and F.G. have constructed the main idea and hypothesis of the study. They developed the theory and arranged/edited the material and method section, have done the evaluation of the data in the Results section. Discussion section of the article was written by E.O., B.K. and F.U., S.G. reviewed, corrected and approved. In addition, all authors discussed the entire study and approved the final version.