

# HALLUKS VALGUS DEFORMİTESİNİN DÜZELTİLMESİ İÇİN UYGULANAN DİSTAL OBLİK METATARSAL OSTEOTOMİSİNİN KLİNİK SONUÇLARI

## Clinical Outcome of Distal Oblique Metatarsal Osteotomy for Correction of Hallux Valgus Deformity

Murat CALBIYIK

### ÖZET

**Amaç:** Bu çalışmada halluks valgus deformitesinin düzeltilmesi için uygulanan distal oblik metatarsal osteotomisi (Wilson osteotomisi) ile elde edilen klinik sonuçların sunulması amaçlanmıştır.

**Gereç ve Yöntem:** Kliniğimizde 2001-2010 yılları arasında hafif halluks valgus deformitesinin düzeltilmesi için Wilson osteotomisi uygulanan 48 hastaya (36 kadın, 12 erkek; ortalama yaş, 41±13.6 yıl) ait 48 ayak retrospektif olarak değerlendirilmiştir. Osteotominin klinik sonucunu değerlendirmek için halluks valgus açısı (HVA), intermetatarsal açısı (IMA), Amerikan Ortopedik Ayak ve Bilek Derneği (AOFAS) skoru, sesamoid pozisyonu, ilk metatarsofalanjeal eklem hareket aralığı ve ağrı için görsel analog skor (VAS) kullanıldı.

**Bulgular:** Hastalar cerrahi sonrası 28.5±10.6 ay izlenmiştir. Preoperatif 26.6±6.8° olan HVA, cerrahiden üç hafta sonra 7.3±0.1°'ye düşmüştür (p<0.001). Benzer olarak IMA osteotomi sonrası anlamlı düşüş göstermiştir (12.7±2.2°'den 6.4±2.4°'e, p<0.001). HVA ve IMA'da kaydedilen düşüş son değerlendirmede de devam etmiştir. Osteotomi sonrası AOFAS skoru 56±13'den 87±12'ye çıkmıştır (p<0.001). Sesamoid pozisyonu normal sınırlara gelmiştir (3.0±1.7'den 1.1±0.5'e, p=0.008). İlk metatarsofalanjeal eklem hareket aralığı dorsifleksiyonda artarken (40°±9.0°'dan 50°±12.0°'ye, p<0.001) plantar fleksiyonda azalmıştır (35.0°±11.0°'den 45°±9.0°'a, p<0.001). Preoperatif 5.7±3.1 olan VAS ağrı skoru, osteotomi sonrası 1.35±0.8'e düşmüştür.

**Sonuç:** Wilson osteotomisi hafif halluks valgus deformitesinin düzeltilmesinde radyolojik ve klinik olarak etkilidir ve cerrahi teknik olarak tercih edilmelidir.

**Anahtar Sözcükler:** *Halluks valgus; Metatarsus; Osteotomi; Wilson's osteotomisi*

### ABSTRACT

**Objective:** The aim of the study was to present the clinical results distal oblique metatarsal osteotomy (Wilson's osteotomy) for correction of hallux valgus deformity.

**Material and Methods:** The clinical data of 48 feet of 48 patients (36 females, 12 males; mean age, 41±13.6 years) who underwent Wilson's osteotomy for correction of mild hallux valgus deformity between 2001-2010 in our clinic were retrospectively reviewed. The clinical outcome of the osteotomy was evaluated by hallux valgus angle (HVA), intermetatarsal angle (IMA), the American Orthopaedic Foot and Ankle Society (AOFAS) score, sesamoid position, range of first metatarsophalangeal joint motion, and visual analogue scale (VAS) score.

**Results:** Patients were followed for 28.5±10.6 months after the surgery. HVA decreased significantly from preoperative 26.6±6.8° to 7.3±0.1° at three weeks after the operation (p<0.001). IMA also showed significant decrease with osteotomy (from 12.7±2.2° to 6.4±2.4°, p<0.001). The decrease in both HVA and IMA was persistent to the last evaluation. AOFAS score significantly improved from 56±13 to 87±17 with osteotomy (p<0.001). Sesamoid position become within normal limits after the operation (from 3.0±6.7 to 1.1±0.5, p=0.008). Range of motion of first metatarsophalangeal joint increased at dorsiflexion (from 38.0°±9.0° to 47.0°±12.0°, p<0.001) and decreased at plantar flexion (from 35.0°±11.0° to 29.0°±9.0°, p<0.001). VAS pain score decreased significantly from preoperative 7.72±3.1 points to 1.35±0.8 points at the last evaluation.

**Conclusion:** Wilson's osteotomy provides effective correction of mild hallux valgus deformity both radiologically and clinically, thus should be considered as an optimal surgical technique.

**Keywords:** *Hallux valgus; Metatarsus; osteotomy; Wilson's osteotomy*

Department of Orthopedics and Traumatology, Hitit University Faculty of Medicine, Corum

Murat CALBIYIK, MD

### İletişim:

Murat CALBIYIK, Ulukavak Mahallesi, Çiftlik Çayırı Cd. 45A, 19040 Corum, Turkey  
Tel: +90 532 769 8962  
e-mail: drmuratcalbiyik@hotmail.com

Geliş tarihi/Received:30.08.2017  
Kabul tarihi/Accepted: 2.11.2017

Bozok Tıp Derg 2017;7(4):54-60  
Bozok Med J 2017;7(4):54-60

## INTRODUCTION

Hallux valgus deformity is characterized by malpositioning in the first metatarsophalangeal joint, lateral deviation of the hallux, and medial deviation of the first metatarsal bone (1). It is one of the most common deformities of the foot and caused mainly by inappropriate footwear (2,3). Hallux valgus is associated with chronic pain, physical deformity, and biomechanical dysfunction of the forefoot. It is corrected only by metatarsal osteotomies (4).

Various surgical techniques have been described for the correction of hallux valgus deformity based on distal osteotomy of the first metatarsal (5,6). In general, distal metatarsal osteotomies have been implied for correction of mild to moderated hallux valgus deformities where hallux valgus angle (HVA)  $<40^\circ$ , intermetatarsal angle (IMA)  $<20^\circ$  (7-9). Wilson's osteotomy, which is a variation of distal metatarsal osteotomy, is an oblique osteotomy of the first metatarsal with lateral transposition of the distal bony fragment, correcting the deformity and shortening the first metatarsal. It was first described by Wilson in 1963 (10), after which many authors modified the technique in order to increase stability of the foot (11-15). Wilson's osteotomy has the advantages of being a simple surgical technique for displacing the metatarsal head and is associated with reduced risk of nonunion and avascular necrosis by providing broad osteotomy surfaces and the large metatarsal head fragment (14). Previous studies indicated that an oblique metatarsal osteotomy yielded better clinical and radiological outcomes compared to straight osteotomy (16).

The aim of this study was to present the clinical results with distal oblique metatarsal osteotomy (Wilson's osteotomy) for correction of hallux valgus deformity.

## MATERIALS AND METHODS

### Study design and population

In this retrospective study, the clinical data of 48 feet of 48 patients (36 females, 12 males; mean age,  $41\pm 13.6$  years) who underwent distal oblique metatarsal osteotomy (Wilson's osteotomy) for

correction of hallux valgus deformity between 2001-2010 in our clinic (Table 1) were analyzed. Patients aged between 18 and 65 years who had a HVA  $<40^\circ$ , IMA  $<15^\circ$ , no radiographic evidence of degenerative metatarsophalangeal arthritis, persistent symptoms under conservative therapy, and follow-up for at least 12 months after the operation were included in the study. Exclusion criteria were previous operation on the affected foot, diabetes mellitus, peripheral vascular disease, peripheral neuropathy, rheumatoid arthritis, and other inflammatory diseases.

The study was conducted according to the Helsinki Declaration and approved by the institutional ethics committee. The requirement for the informed consent of patients was waived for the retrospective design of the study.

**Table 1.** Demographic and clinical characteristics of patients

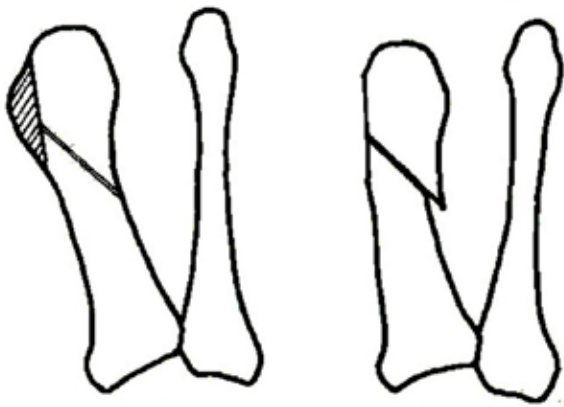
Parameter	Result (n=48)
Age (years)	41 $\pm$ 13.6 (18-64)
Gender	
Male	12 (75.0%)
Female	36 (25.0%)
Hallux valgus side	
Right	25 (52.1%)
Left	23 (47.9%)
Hospitalization duration (days)	2.1 $\pm$ 0.6 (1-4)
Follow-up duration (months)	28.5 $\pm$ 10.6 (15-49)

Data are presented as mean $\pm$ standard deviation (min-max) or n (%).

### Surgical technique

All of the patients were operated by the same surgeon under general or regional anesthesia using a pneumatic high-thigh tourniquet. In order to correct the hallux valgus deformity and shortening of the first metatarsal, an oblique osteotomy of the first metatarsal with lateral transpositional displacement of the distal bony fragment was applied as described in literature (10,12). Osteotomy was performed through a 5 cm dorsomedial skin incision centered over the

first metatarsophalangeal joint. Following a Y-shaped capsular incision and exostectomy, an oblique osteotomy angled at 45° starting at the proximal end of the base of the exostectomy was carried out with an oscillating saw. The distal fragment was then displaced laterally and the osteotomy site was temporarily stabilised with pointing forceps and internally fixed with one or two 3.5-mm cortical screws perpendicular to the osteotomy (Figure 1).



the first metatarsal with lateral transpositional displacement of the distal bony fragment for correction of hallux valgus deformity

The screws were placed proximal to the osteotomy site in order to avoid spintering of the medial cortex. The projecting bony spike of the proximal fragment was subsequently trimmed out with a bone rongeur. A medial Y-V capsulorrhaphy was performed, and skin was closed with interrupted non-absorbable sutures. Dressings were applied and the foot was bandaged and kept elevated for 48 hours, before heel weight-bearing was allowed.

On postoperative period, the foot was immobilised in a brace for 3 weeks, and full weight-bearing was allowed after 6 weeks.

#### Clinical outcome parameters

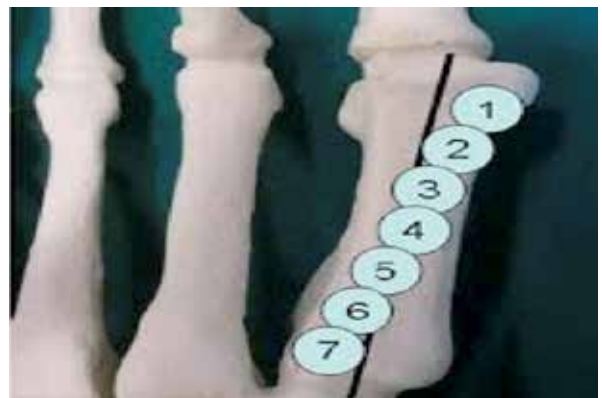The load bearing radiographs of the patients were obtained preoperatively, three weeks after the

operation, and at the last follow-up. The clinical outcome of the osteotomy was evaluated by HVA, IMA, the American Orthopaedic Foot and Ankle Society (AOFAS) score, sesamoid position, range of first metatarsophalangeal joint motion, and pain level.

The HVA and IMA were calculated using the method of Mitchell et al. (17). Range of first metatarsophalangeal joint motion was measured on dorsiflexion and plantar flexion, and given in degrees.

The AOFAS scoring system scores, ranging from 0 to 100 points, was also calculated to assess the outcome of osteotomy. The scoring system includes both subjective and objective factors such as pain, functional capacity, and hallux alignment (18).

Sesamoid position was determined on anteroposterior radiograph in the standing position according to the relationship between the axis of the first metatarsal and the sesamoids (Figure 2): 1, Normal situation: the axis of the first metatarsal is between the two sesamoids; 2, The lateral part of the medial sesamoid is already in contact with the axis of the first metatarsal; 3, The axis of the first metatarsal halves the medial sesamoid; 4, The medial part of the medial sesamoid is still in contact with the axis of the first metatarsal; 5-7, The medial sesamoid is laterally beyond the axis of the first metatarsal (19).



radiograph in the standing position. Shortening in the first metatarsal length and in

distance from the first to second metatarsal were given in millimeters. The first metatarsal length was defined as the distance from a line from the most distal part of the first and third metatarsal heads crossing to the most distal part of the second metatarsal head (20). For measurement of first metatarsal length and distance from the first to second metatarsal, a dorsoplantar weight-bearing radiograph was taken for each individual, with both feet together, with the tube inclined 15° to the vertical and at a tube-to-object distance of 1 m. A digital image of each radiograph was made using a scanner, allowing the exploration of images on positive film. The radiographic measurements were made using K-PACS software (K-PACS 2008-IMAGE Information Systems Ltd., London, United Kingdom). Level of pain was quantified on a 10-point visual analogue scale (VAS) by patients, which marks 'No pain' on 0 point and 'Unbearable pain' on 10 point.

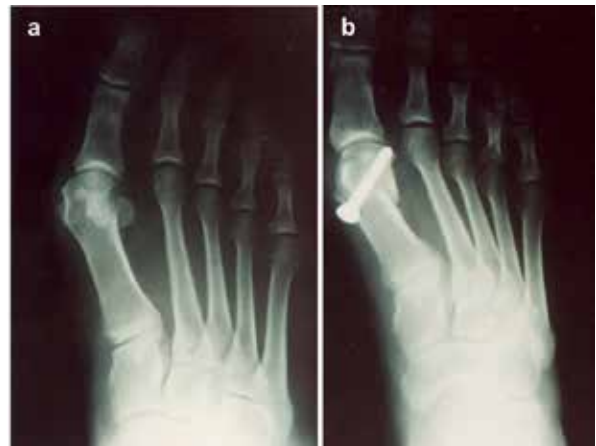### Statistical analysis

Study data were summarized using descriptive statistics (e.g., mean, standard deviation, range, frequency and percentage). In order to evaluate the significance of change in continuous variables over time, paired t test or repeated measures of analysis of variance (ANOVA) was used for two or more than two measurements, respectively. A paired-samples t-test was applied for the post-hoc analysis of significant results of ANOVA. Statistical level of significance was set to  $p < 0.05$ .

## RESULTS

Forty-eight study patients were hospitalized for  $2.1 \pm 0.6$  days for distal oblique metatarsal osteotomy and followed for  $28.5 \pm 10.6$  months after the surgery (Table 1).

HVA decreased significantly from preoperative  $26.6^\circ \pm 6.8^\circ$  to  $7.3^\circ \pm 0.1^\circ$  at three weeks after the operation ( $p < 0.001$ ). IMA also showed significant decrease with osteotomy (from  $12.7^\circ \pm 2.2^\circ$  to  $6.4^\circ \pm 2.4^\circ$ ,  $p < 0.001$ ) (Figure 3). The decrease in both HVA and IMA was persistent to last evaluation (Table 2).



**Figure 3.** Anteroposterior radiograph in the standing position of a patient with hallux valgus deformity before (a) and after (b) the Wilson's osteotomy.

AOFAS score significantly improved from  $56 \pm 13$  to  $87 \pm 12$  with distal oblique metatarsal osteotomy ( $p < 0.001$ ). Sesamoid position changed significantly and become within normal limits after the operation (from  $3.0 \pm 1.7$  to  $1.1 \pm 0.5$ ,  $p = 0.008$ ). Range of motion of first metatarsophalangeal joint increased at dorsiflexion (from  $40^\circ \pm 9.0^\circ$  to  $50^\circ \pm 12.0^\circ$ ,  $p < 0.001$ ) and decreased at plantar flexion (from  $35.0^\circ \pm 11.0^\circ$  to  $45^\circ \pm 9.0^\circ$ ,  $p < 0.001$ ). The pain of patient as evaluated by VAS pain score decreased significantly from preoperative  $5.7 \pm 3.1$  points to  $1.35 \pm 0.8$  points at the last evaluation. The distal oblique metatarsal osteotomy did not produce significant shortening on either metatarsal length or distance from the first to second metatarsal ( $p > 0.05$ ) (Table 2).

## DISCUSSION

Although more than 200 surgical techniques have been defined for the correction of hallux valgus deformity, there is still no consensus among surgeons on the best technique. However, in general, minor and moderate deformities may be treated by distal osteotomies, while more severe deformities are best treated by proximal metatarsal osteotomies (21). In the present report, Wilson's osteotomy was applied on 48 patients

**Table 2.** Clinical outcome of patients after distal oblique metatarsal osteotomy

	Preoperative	Postoperative 3rd week	Last follow-up	P
Hallux valgus angle, °	26.6±6.8 (20-38)	7.3±0.1 (2-11)	9.7±9.8 (5-15)	<0.001a
Intermetatarsal angle, °	12.7±2.2 (8-15)	6.4±2.4 (5-12)	6.8±1.7 (5-13)	<0.001b
AOFAS score (0–100)	56±13 (23-76)		87±12 (65-99)	<0.001
Sesamoid position	3.0±1.7 (1-5)		1.1±0.5 (1-2)	0.008
First metatarsophalangeal joint ROM, °				
Dorsiflexion	40±9.0 (15-60)		50±12.0 (34-90)	<0.001
Plantar flexion	35.0±11.0 (15-60)		45±9.0 (10-75)	<0.001
Shortening in metatarsal length (mm)	53.2±4.5 (51-73)		51.5±4.2 (49-67)	0.575
Shortening in distance from the first to second metatarsal (mm)	6.10±2.6 (4-8.5)		6.39±2.8 (4-9)	0.487
VAS pain score	5.7±3.1 (5-8)		1.35±0.8 (1-2)	<0.001

AOFAS, American Orthopaedic Foot and Ankle Society; ROM, range of motion; VAS, visual analogue scale.

Data are presented as mean±standard deviation (min-max).

a p<0.001 for Preop vs. Postop 3rd week; p<0.001 for Preop vs. Last follow-up; p<0.119 for Postop 3rd week vs. Last follow-up.

b p<0.001 for Preop vs. Postop 3rd week; p<0.001 for Preop vs. Last follow-up; p<0.698 for Postop 3rd week vs. Last follow-up.

with mild hallux valgus, and both radiological and clinical outcome of surgery was good over two-year postoperative follow-up without any significant complication or recurrence.

Wilson's osteotomy is one of the most common surgical techniques applied for the management of hallux valgus, in both its original and modified forms (10-15,22). Clinical studies showed that Wilson's first metatarsal osteotomy for hallux valgus is straight-forward and produces excellent outcome in patients with hallux valgus (13,23). It is basically an oblique osteotomy of the first metatarsal with lateral transpositional displacement of the distal bony fragment (10). I applied the technique in its original form.

Wilson's osteotomy has been shown to have comparable outcomes with Chevron osteotomy for correction of mild to moderated hallux valgus deformity. In a recent clinical study on 61 patients with hallux valgus deformity, Guler et al. (24) reported that the Chevron and Wilson's osteotomies both provided significant improvement in the first IMA, HVA, distal metatarsal

articular angle, range of first metatarsophalangeal joint motion, AOFAS score, and sesamoid position without any significant differences. Scharer et al. (25) also confirmed that the distal oblique osteotomy is simple and reliable surgical technique and shows radiographic correction and patient satisfaction equivalent to those in the Chevron osteotomy. According to HVA and IMA, which was <40° and <15°, respectively, the study population comprised of patients with mild hallux valgus deformity. In the present series, Wilson's osteotomy provided decrease in both HVA and IMA, improvement in sesamoid position, range of motion of first metatarsophalangeal joint, AOFAS score and VAS pain score, which lasted to the last evaluation. VAS is the most commonly used and best pain score in clinical practice and studies of hallux valgus (26), thus VAS was utilized as a primary variable to evaluated the clinical outcome of patients. Since outcome of the surgery was good, I suggest that Wilson's osteotomy can be effectively and safely applied without any modification for correction of mild hallux valgus deformity.

Metatarsalgia is the most common complication of Wilson's osteotomy, which occurs as a result of

shortening of the first metatarsal (27). Recurrence, avascular necrosis, hallux varus, nonunion, malunion, infection and long-term fever are other rarer complications of Wilson's osteotomy (28). I have not encountered any complication in my series after Wilson's osteotomy. In order to decrease the risk of complications, to increase patients' satisfaction, and to choose the best surgical technique, a careful preoperative assessment should be conducted (29,30). The main limitations of the present study were its retrospective design and small sample size, which precludes us from reaching to a definitive conclusion on the clinical efficacy and safety of Wilson's osteotomy for correction of hallux valgus deformity. Nevertheless, the present study is valuable for providing evidence on the clinical outcome of distal oblique metatarsal osteotomy in daily clinical settings, thus would guide surgeons to choose most appropriate osteotomy technique for correction of hallux valgus deformity. In conclusion, Wilson's osteotomy, which is distal oblique metatarsal osteotomy provides effective correction of mild hallux valgus deformity both radiologically and clinically without causing any significant complications during two-year postoperative follow-up. Furthermore, this osteotomy technique is easy to perform and straight forward with minimum requirement of hospitalization. Therefore, Wilson's osteotomy should be considered as optimal surgical technique for correction of mild hallux valgus deformity.

## REFERENCES

1. Fraissler L, Konrads C, Hoberg M, Rudert M, Walcher M. Treatment of hallux valgus deformity. *EFORT Open Rev.* 2016;1(8):295-302.
2. Mann R, Coughlin M. Hallux valgus-etiology, anatomy, treatment and surgical considerations. *Clin Orthop.* 1981;157:31-41.
3. Nix SE, Vicenzino BT, Collins NJ, Smith MD. Characteristics of foot structure and footwear associated with hallux valgus: a systematic review. *Osteoarthritis Cartilage.* 2012;20(10):1059-74.
4. Hecht PJ, Lin TJ. Hallux valgus. *Med Clin North Am.* 2014;98(2):227-32.
5. Coughlin MJ. Hallux valgus. *J Bone Joint Surg.* 1996;78(6):932-66.
6. Castaneda DA, Myerson MS, Neufeld SK. The Ludloff osteotomy: a review of current concepts. *International Orthopaedics (SICOT).* 2013;37(9):1661-8.
7. Monreal R, Faedo E, Monreal E. Distal metatarsal osteotomy for correction of hallux valgus. *Ortho & Rheum Open Access.* 2017;5(4):555668.
8. Oh IS, Kim MK, Lim KY, Bae JH. Modified technique of distal metatarsal osteotomy for hallux valgus. *Foot Ankle Int.* 2007;28(4):527-8.
9. Robinson AHN, Limbers JP. Modern concepts in the treatment of hallux valgus. *J Bone Joint Surg.* 2005;87(8):1038-45.
10. Wilson JN. Oblique displacement osteotomy for hallux valgus. *J Bone Joint Surg.* 1963;45-B:552-6.
11. Geldwert JJ, McGrath M, Rock GC, Mancuso JE. Wilson bunionectomy with internal fixation: a ten-year experience. *J Foot Surg.* 1991;30(6):574-9.
12. Givissis P, Karataglis D, Christodoulou A, Terzidis I, Pournaras J. Wilson osteotomy stabilised by means of internal fixation for the treatment of hallux valgus. *Acta Orthop Belg.* 2004;70(1):57-63.
13. Schemitsch E, Horne G. Wilson's osteotomy for the treatment of hallux valgus. *Clin Orthop.* 1989;240:221-5.
14. Xarchas KC, Mavrolias D, Kyriakopoulos G. Modified Wilson's osteotomy for hallux valgus deformity. A new approach. *Open Orthop J.* 2014;8:361-7.
15. Kolundžić R, Mađarević M, Trkulja V, Crnković T, Šmigovec I, Matek D. Croatian rotatory oblique three-dimensional osteotomy (CROTO)--a modified Wilson's osteotomy for adult hallux valgus intended to prevent dorsal displacement of the distal fragment and to reduce shortening of the first metatarsal bone. *Med Glas (Zenica).* 2017;14(2):250-6.
16. Han SH, Park EH, Jo J, Koh YG, Lee JW, Choi WJ, et al. First metatarsal proximal opening wedge osteotomy for correction of hallux valgus deformity: comparison of straight versus obliques osteotomy. *Yonsei Med J.* 2015;56(3):744-52.
17. Mitchell CL, Fleming JL, Allen R, Glenney C, Sanford GA. Osteotomy-bunionectomy for hallux valgus. *J Bone Joint Surg.* 1958;40-A(1):41-60.
18. Kitaoka HB, Alexander IJ, Adelaar RS, Nunley JA, Myerson MS, Sanders M. Clinical rating systems for the ankle hindfoot, midfoot, hallux, and lesser toes. *Foot Ankle Int.* 1994;15(7):349-53.
19. Tóth K, Huszanyik I, Kellermann P, Boda K, Róde L. The effect of first ray shortening in the development of metatarsalgia in the second through fourth rays after metatarsal osteotomy. *Foot Ankle Int.* 2007;28(1):61-3.
20. Day T, Charlton TP, Thordarson DB. First metatarsal length change after basilar closing wedge osteotomy for hallux valgus. *Foot Ankle Int.* 2011;32(5):S513-18.
21. Trnka HJ, Krenn S, Schuh R. Minimally invasive hallux valgus surgery: a critical review of the evidence. *Int Orthop.* 2013;37(9):1731-5.
22. Keogh P, Jaishanker JS, O'Connell RJ, White M. The modified Wilson osteotomy for hallux valgus. *Clin Orthop Relat Res.* 1990;255:263-7.
23. Tibrewal S, Foss M. Day care surgery for the correction of hallux valgus. *Health Trends.* 1991;23(3):117-9.

24. Guler O, Yilmaz B, Mutlu S, Cerci MH, Heybeli N. Distal oblique metatarsal osteotomy for hallux valgus deformity: a clinical analysis. *J Foot Ankle Surg.* 2017;56(3):497-504.
25. Scharer BM, DeVries JG. Comparison of chevron and distal oblique osteotomy for bunion correction. *J Foot Ankle Surg.* 2016;55(4):738-42.
26. Schrier JC, Palmen LN, Verheyen CC, Jansen J, Koëter S. Patient-reported outcome measures in hallux valgus surgery. A review of literature. *Foot Ankle Surg.* 2015;21(1):11-5.
27. Singh D, Dudkiewicz I. Lengthening of the shortened first metatarsal after Wilson's osteotomy for hallux valgus. *J Bone Joint Surg Br.* 2009;91(12):1583-6.
28. Wang LF, Wu J, Zheng C, Li SL, Huang RR, Zhang JK. Long-term fever after hallux valgus surgery secondary to titanium allergy: a case report and review of the literature. *J Foot Ankle Surg.* 2016;55(6):1282-6.
29. Lee KT, Park YU, Jegal H, Lee TH. Deceptions in hallux valgus: what to look for to limit failures. *Foot Ankle Clin.* 2014;19(3):361-70.
30. Gao P, Gui JC, Hong JJ, Hong JS, Hu Y, Jiang BG, et al. Consensus on surgical management of hallux valgus from China. *Foot and Ankle Working Committee; Chinese Association of Orthopaedic Surgeons Orthopaedic Branch; Chinese Association of Orthopaedic Surgeons.* *Orthop Surg.* 2015;7(4):291-6.