

## Efficiency of Eprinomectin for the Treatment of Naturally Infested with *Sarcoptes scabiei* in Rabbits (*Oryctolagus cuniculus*)<sup>#</sup>

Mustafa ESER<sup>\*1</sup>, Durmus Fatih BASER<sup>2</sup>, Cenker Cagri CINGI<sup>3</sup>, Hatice CİCEK<sup>4</sup>

<sup>1</sup>Anadolu University, Faculty of Open Education, Health Programs, 26470 Eskişehir

<sup>2,3</sup>Department of Internal Medicine, Faculty of Veterinary Medicine, University of Afyon Kocatepe, Afyonkarahisar

<sup>4</sup>Department of Parasitology Faculty of Veterinary Medicine, University of Afyon Kocatepe, Afyonkarahisar

\*Corresponding author e-mail: meser961@anadolu.edu.tr

# This case report was presented as an oral presentation at the 18th National Parasitology Congress.

### ABSTRACT

This study was carried out on twelve white New Zealand rabbits (*Oryctolagus cuniculus*) which brought with itchy wounds symptoms around eye, nose, mouth and feet to Afyon Kocatepe University, Veterinary Faculty, Animal Hospital. The skin scrapings that taken from the lesion areas of rabbits with a scalpel, were examined in the light microscope then crushed with 10% KOH and it was determined the rabbits infested with *Sarcoptes scabiei*. At treatment, Eprinomectin was administered 0.2 mg/kg subcutaneously twice with 14 days interval. The efficacy of eprinomectin was assessed either clinically or parasitologically examination by the absence of *Sarcoptes scabiei* mites due to skin scraping. The results of the present study determine that eprinomectin is effective against naturally infestations of *S. scabiei* in rabbits.

**Key Words:** Afyonkarahisar, *Sarcoptes scabiei*, Rabbit, Eprinomectin, *Oryctolagus cuniculus*.

## *Sarcoptes scabiei* ile Doğal Enfeste olan Tavşanlarda (*Oryctolagus cuniculus*) Eprinomectin Tedavisinin Etkinliği

### ÖZ

Bu çalışma, Afyon Kocatepe Üniversitesi Veteriner Fakültesi Hayvan Hastanesine göz, burun, ağız etrafında ve ayaklarda kaşıntılı yara şikâyetleri ile getirilen on iki beyaz Yeni Zelanda tavşanı (*Oryctolagus cuniculus*) üzerinde yürütüldü. Tavşanların lezyonlu bölgelerinden bisturi yardımıyla alınan deri kazıntıları %10'luk KOH ile ezildikten sonra ışık mikroskopunda incelendi ve tavşanların *Sarcoptes scabiei* ile infeste oldukları belirlendi. Tedavide eprinomectin 0.2 mg/kg ve deri altı yolla 14 gün arayla iki kez uygulandı. Eprinomectinin etkinliği; deri kazıntısının parazitolojik muayenesinde *Sarcoptes scabiei* akarlarının varlığı ve/veya klinik belirtilerin devam edip etmediği durumuna göre değerlendirildi. Sonuçta eprinomectinin tavşanlarda *S. scabiei*'nin doğal enfestasyonlarına karşı etkili olduğu belirlenmiştir.

**Anahtar Kelimeler:** Afyonkarahisar, *Sarcoptes scabiei*, Tavşan, Eprinomectin, *Oryctolagus cuniculus*.

To cite this article: Eser M. Baser DM. Cingi CC. Cicek H. Efficiency of Eprinomectin for the Treatment of Naturally Infested with *Sarcoptes scabiei* in Rabbits (*Oryctolagus cuniculus*). *Kocatepe Vet J. 2017; 10(1): 40-43*.

## INTRODUCTION

*Sarcoptes scabiei* is a mite causing mange in many mammals such as horses, cattle, sheep, goats, dogs, and rabbits (Kettle 1995). Zoonotic agents exist in living beings as obligatory parasites (Bornstein et al. 2001, Baker et al. 2014). The agents in infested rabbits dwell in the regions like face, ears and legs (Schoeb et al. 2007). Although the infection is widely observed in rabbits, it is rather difficult to eradicate the agent ultimately (Meredith 2008). Female agents dig tunnels through the epidermis and lay their eggs there (Baker 1998).

The first clinical symptom of the infection is itching (Soulsby 1982). The lesions, occurring on the skin due to excessive itching, lead to pyoderma and hair loss by creating a disposition to secondary infections. Lesions around the mouth and nose result in anorexia, weight loss, cachexia and death (Soulsby 1982, Baker et al. 2014). As biochemical changes in the blood serum occur in severe infestations, anemia and leukopenia are the most common symptoms (Baker et al. 2014).

There have been numerous studies to determine the effect of the drug against various parasites in pets and farm animals (Shoop et al. 1996, Shoop et al. 2001, Cringoli et al. 2003, Aguirre et al. 2005, Rehbein et al. 2005, Habela et al. 2006, Geurden and Vercruyse 2007, Kozan et al. 2008, Bilgin et al. 2010, Visser et al. 2013). Eprinomectin was applied topically in cats to determine its efficacy against *Dirofilaria immitis* (Baker 1998). There have also been several studies on lab animals for which eprinomectin was applied orally (Sevimli et al. 2009), topically (Ulutas et al. 2005, Rambozzi et al. 2014) and in an injectable way (Baoliang et al. 2006).

This study aimed to determine the efficiency of eprinomectin in the treatment of 12 New Zealand rabbits naturally infested with *Sarcoptes scabiei*.

## MATERIAL AND METHOD

12 New Zealand rabbits were brought to Afyon Kocatepe University Animal Hospital with itchy sores around the eye, nose, mouth and legs constituted the material for this study. After having being crushed with 10% of KOH, the rabbit skin scrapings obtained from the areas with lesions were examined under a light microscope (Nikon Eclipse 80i - DS-5M-L1 imaging system). The patients identified with *Sarcoptes scabiei* in the microscopic examination were subcutaneously administered 0.2 mg/kg of eprinomectin twice with an interval of 14 days.

## RESULTS

In the microscopic examination of the skin scrapings derived from rabbits with lesions around eyes, mouth, nose and legs revealed mature *Sarcoptes scabiei* mites (Image 1) and eggs (Image 2). Apart from skin

lesions, severely impaired general condition was detected in the patients (Image 3, Image 4).

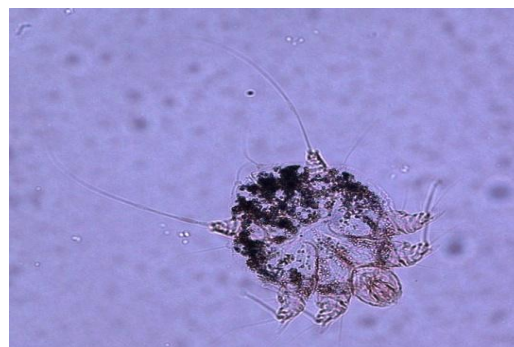

Image 1. Adult of *Sarcoptes scabiei* (x10)

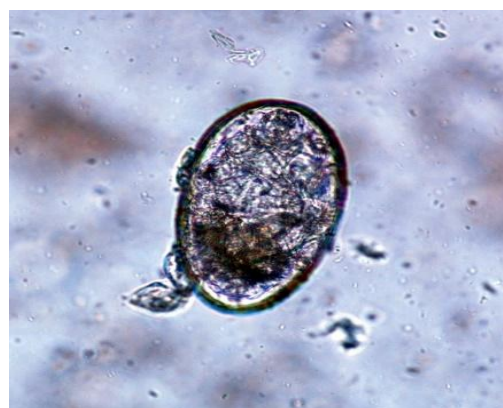


Image 2. Egg of *Sarcoptes scabiei* (x40)

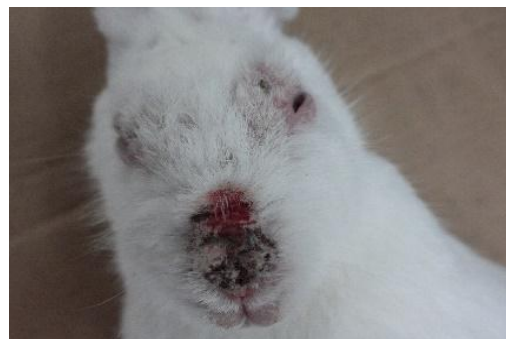


Image 3. Mouth, nose and eyes injuries of the infected rabbit

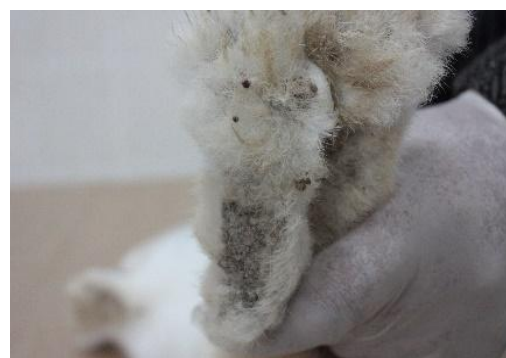
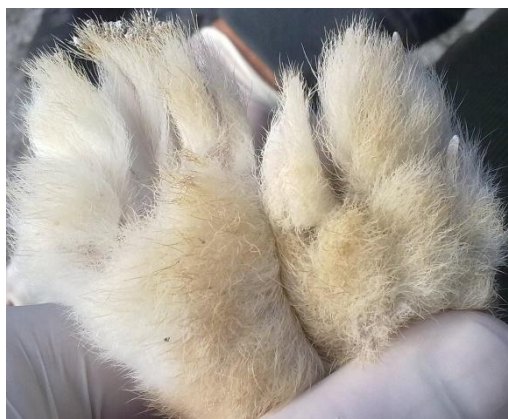
Image 4. Foot injury of the infected rabbit

Following the eprinomectin administration, clinical recovery of the rabbits started; no agent was detected in the skin scrapings derived on the 7<sup>th</sup> and 14<sup>th</sup> days (Image 5, Image 6).



**Image 5.** View of the head region post-clinical improvement



**Image 6.** View of the foot post-clinical improvement

## DISCUSSION

Sarcoptic mange in rabbits primarily starts around the mouth and then lesions spread all around the face and eyes (Schoeb et al. 2007). Ivermectin group of antiparasitic drugs are used topically, orally and through parenteral routes for mange treatment (Bornstein et al. 2001). Ulutas et al., (2005) administered eprinomectin topically to rabbits naturally infested with *Psoroptes cuniculi* as two doses with an interval of 14 days, and recorded a clinical recovery starting from the third day following the first application. It was reported in another study that one dose of 200-300 µg/kg of eprinomectin administered subcutaneously sufficed for the treatment of the rabbits infested with *Psoroptes cuniculi*; 100µg/kg of the drug did not cure the infestation (Baoliang et al. 2006). Rambozzi et al., (2014) topically administered a dose of 5 mg/kg of eprinomectin to rats infested with *Myocoptes musculinus* and achieved an efficient cure. In a study aimed to determine the effectiveness of doramectin,

eprinomectin and selamectin against *Syphacia muris* in rats, Sevimli et al., (2009) reported that on the second day following the administration eprinomectin was 100% effective; doramectin and selamectin were effective at the rates of 99.32% and 98.72%, respectively. However, this impact occurred on the sixth day. Kurtdede et al., (2007) reported that a dose of topical selamectin was effective in the treatment of New Zealand rabbits naturally infested with *Psoroptes cuniculi* (6-18 mg/kg) and Angora rabbits naturally infested with *Sarcoptes scabiei* (10-12 mg/kg). Although various antiparasitic drugs against Sarcoptic mange in rabbits were administered via various administration techniques, there is not a single study on subcutaneous administration of eprinomectin. Medication started right away on the day of mange diagnosis and followingly clinical recovery was observed.

As a consequence, it was observed that sarcoptic mange in rabbits could be successfully cured with 0.2 mg/kg of subcutaneous eprinomectin administration.

## REFERENCES

- Aguirre DH, Gaido AB, Cafrune MM, Castelli ME, Mangold AJ, Guglielmo AA.** Eprinomectin pour-on for control of *Boophilus microplus* (Canestrini) ticks (*Acari: Ixodidae*) on cattle. *Vet Parasitol*, 2005; 127: 157-163.
- Baker CF, Tielemans E, Pollmeier MG, McCall JW, McCall SD, Irwin J, Chester ST, Carithers DS, Rosentel JK.** Efficacy of a singledose of a novel topical combination product containing eprinomectin to prevent heart worm infection in cats. *Vet Parasitol*, 2014; 202:49-53.
- Baker DG.** Natural Pathogens of Laboratory Mice, Rats, and Rabbits and Their Effects on Research. *Clin Microbiol Rev*, 1998; 231-266.
- Baoliang P, Wang M, Xu F, Wang Y, Dong Y, Pan Z.** Efficacy of an injectable formulation of eprinomectin against *Psoroptes cuniculi*, the ear mange mite in rabbits. *Vet Parasitol*, 2006; 137: 386-390.
- Bilgin Z, Öter K, Tınar R, Tüzer E.** Effectiveness of eprinomectin 0.5% pour-on against gastrointestinal nematodes in naturally infected cattle. *Turk J Vet Anim Sci*, 2010; 34 (6): 541-545.
- Bornstein S, Mörner T, Samuel WM.** *Sarcoptes scabiei* And Sarcoptik Mange. In, Samuel WM, Pybus MJ, Kocan AA (Eds): *Parasitic*

- Diseases of Wild Mammals. 2<sup>nd</sup> Ed., Iowa State University Press, USA, 2001; 107-120.
- Cringoli G, Rinaldi L, Veneziano V, Capelli G.** Efficacy of eprinomectin pour-on against gastrointestinal nematode infections in sheep. *Vet Parasitol*, 2003; 112: 203-209.
- Geurden T, Vercruyse J.** Field efficacy of eprinomectin against a natural *Muellerius capillaris* infection in dairy goats. *Vet Parasitol*, 2007; 147: 190-193.
- Habela M, Moreno A, Gragera-Slikker A, Gomez JM, Montes G, Rodriguez P, Alvinerie M.** Efficacy of eprinomectin pour-on in naturally Oestrus ovis infested merino sheep in Extremadura, South-West Spain. *Parasitol Res*, 2006; 99: 275-280.
- Kettle DS.** Medical and Veterinary Entomology. 2<sup>nd</sup> Ed., C.A.B International Press, UK, 1995; 440-458.
- Kozan E, Sevimli FK, Birdane FM, Adanır R.** Efficacy of eprinomectin against *Toxocara canis* in dogs. *Parasitol Res*, 2008; 102: 397-400.
- Kurtdede A, Karaer Z, Acar A, Güzel M, Cingi CC, Ural K, İça A.** Use of selamectin for the treatment of psoroptic and sarcoptic mite infestation in rabbits. *Vet Dermatol*. 2007; 18: 18-22.
- Meredith AL.** Dermatological conditions of rodents and rabbits. Proceedings of the 33<sup>rd</sup> World Small Animal Veterinary Congress, Dublin-Ireland, 2008; 250-252.
- Rambozzi L, Rossi L, MolinarMin AR, Osella L, Bellardi S, Marchetti R, Pollicino P.** Efficacy and safety of topical eprinomectin to control *Myocoptes musculinus* infestation in mice. *Braz J Vet Parasitol*, 2014; 23(1): 244-247.
- Rehbein S, Winter R, Visser M, Maciel AE, Marley SE.** Chorioptic mange in dairycattle: treatment with eprinomectin pour-on. *Parasitol Res*, 2005; 98: 21-25.
- Schoeb TR, Cartner SC, Baker RA, Gerrity LW.** Parasites of Rabbits. In, Baker DG (Ed) Flynn's Parasites of Laboratory Animals. 2<sup>nd</sup> Ed., Blackwell Publishing, Iowa. USA, 2007; 479-480.
- Sevimli FK, Kozan E, Sevimli A, Doğan N, Bulbul A.** The acute effects of single-dose orally administered doramectin, eprinomectin and selamectin on natural infections of *Syphacia muris* in rats. *Exp Parasitol*, 2009; 122: 177-181.
- Shoop W, Michael B, Egerton J, Mrozik H, Fisher M.** Titration of Subcutaneously Administered Eprinomectin against Mature and Immature Nematodes in Cattle. *J Parasitol*, 2001; 87(6): 1466-1469.
- Shoop WL, Egerton JR, Eary CH, Haines HW, Michael BF, Mrozik H, Eskola P, Fisher MH, Slayton L, Ostlind DA, Skelly BJ, Fulton RK, Barth D, Costa D, Gregory LM, Campbell WC, Seward RL, Turner MJ.** Eprinomectin: A Novel Avermectin for Use as a Topical Endectocide for Cattle. *Int J Parasitol*, 1996; 26(11):1237-1242.
- Soulsby EJJ:** Helminths, Arthropods and Protozoa of Domesticated Animals. 8<sup>th</sup> Ed., Baillere Tindall, London, 1982, 452-475.
- Ulutas B, Voyvoda H, Bayramlı G, Karagenc T.** Efficacy of topical administration of eprinomectin for treatment of ear mite infestation in six rabbits. *Vet Dermatol*, 2005; 16:334-337.
- Visser M, Lowenstein M, Yoon S, Rehbein S.** The treatment of bovine sarcoptic mange (*Sarcoptes scabiei var. bovis*) using eprinomectin extended-release injection. *Vet Parasitol*, 2013; 192: 359-364.