

PALİZATLANAN KAPSÜLLÜ NÖROMA (PEN); BİR OLGU SUNUMU VE
LİTERATÜRÜN GÖZDEN GEÇİRİLMESİ

Selim SÖZEN , 0000-0003-2006-9198

Geliş Tarihi/Received

22.05.2024

Kabul Tarihi/Accepted

31.08.2024

Yayın Tarihi/Published

03.09.2024

Correspondence: Selim SÖZEN, Sözen Surgery Clinic, Genel Cerrahi Kliniği, İstanbul, Turkey, email: selimsozen63@yahoo.com

ÖZET

Palizatlanan kapsüllü nöroma (PEN), küçük, sert, pigmente olmayan nodüller veya papüllerle karakterize edilen, kendine özgü iyi huylu bir nöral tümördür. En sık olarak yüzü etkileyerek tek başına, ten renginde, kubbe şeklinde bir nodül olarak ortaya çıkar. Yüzünde palizadlanan kapsüllü nöroma ile başvuran erkek hastanın klinik ve patolojik bulgularını tanımlıyoruz.

Anahtar Kelimeler: Nöroma, palizadlanan kapsüllü nöroma, nörofibroma, schwannoma, nörojenik tümörler, cerrahi

PALISADED ENCAPSULATED NEUROMA; REPORT OF A CASE AND REVIEW OF THE LITERATURE

ABSTRACT

Palisaded encapsulated neuroma (PEN) is a distinctive benign neural tumor, which is characterized by small, firm, non-pigmented nodules or papules. It most commonly presents as a solitary, flesh-colored, dome-shaped nodule affecting the face. We describe the clinical and pathologic findings of a male patient who presented with a palisaded encapsulated neuroma on his face.

Keywords: Neuroma, palisaded encapsulated neuroma, neurofibroma, schwannoma, neurogenic tumors, surgery

1. INTRODUCTION

Palisading encapsulated neuroma (PEN) was first described by Reed et al. (1) in 1972. Palisading encapsulated neuroma (PEN) is a rare benign cutaneous condition. They categorized benign neurogenic tumors into three types; schwannomas, neurofibromas, and neuromas. PEN is usually diagnosed in patients between the ages of 40 and 60 and with equal incidence in both sexes. The size of the lesion typically ranges between 2 mm and 6 mm. Rarely, it can present with multiple lesions(2). PEN has no association with neurofibromatosis or multiple endocrine neoplasia syndrome type 2B (MEN 2B)(3).

Here, we present a rare case of cutaneous PEN in a dermatomal distribution on the face not associated with neurofibromatosis or MEN 2B.

2. CASE REPORT

A 50-year-old male patient applied to the surgical clinic with a complaint of painful lesions in the facial area. A nodular lesion with a history of local trauma, approximately 4 x 3 millimeters in size, the same color as the normal skin, was detected on the left lower lip edge. A diagnosis of fibroma was made and an excisional biopsy was performed. The surgical sample was directed to the pathology service. Microscopic examination of the tissue sample revealed a benign neoplasm of neural differentiation. There were benign-looking spindle cell bundles and palisade in their nuclei. There were also clefts between the cells and the stroma surrounding them (Figure 1,2). Immunohistochemical analysis revealed strong positive staining for S-100 protein, negative staining for GFAP protein, and focal positive staining for alpha-smooth muscle actin (α -SMA) confined to the wall of small blood vessels. The diagnosis was PEN. The patient is under follow-up two years after surgery without any signs of recurrence.

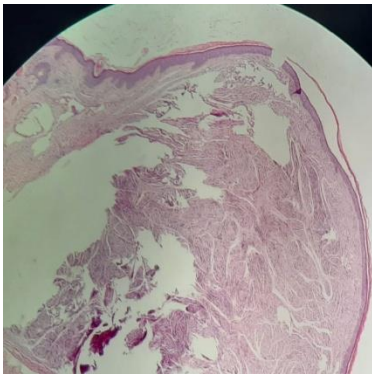


Figure 1: Partially encapsulated intradermal nodule composed of interdigitating spindle cells grouped in distinct fascicles (H and E, $\times 100$)

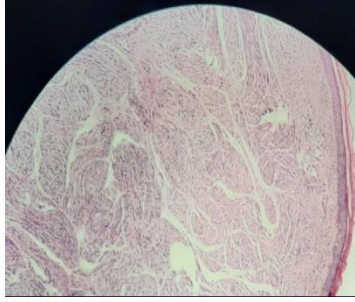


Figure 2: Spindle cells arranged in distinct fascicles. Individual cells are poorly delineated with eosinophilic cytoplasm, and pointed, wavy basophilic nuclei(H and E, ×200)

3. DISCUSSION

The neuroma is the proliferation of axonal components of nerve tissue and Schwann cells. Palisade capsule neuroma is a hamartomatous proliferation of nerve tissue(4).

Palisaded encapsulated neuroma (PEN) is a distinctive benign neural tumor, which is characterized by small, firm, non-pigmented nodules or papules(1). It most commonly presents as a solitary, flesh-colored, dome-shaped nodule affecting the face. The lesions have also been found on the trunk, shoulder, arm, oral mucosa, eyelid, and glans penis(1,2). Some researchers have suggested calling it "solitary limited neuroma" due to similar lesions due to unclear palisade alignment(5). In the 2013 and 2020 World Health Organization (WHO) classification of tumors of soft tissue and bone, solitary circumscribed neuroma is described as a formal name, and PEN is described as a synonym. However, even after the WHO classification was published, these terms have been used interchangeably(6,7).

The pathogenesis of PEN is still controversial. Although PEN has been suggested to be a part of multiple endocrine neoplasia syndrome type 2 (1), it has been observed that it exhibits histological features different from those seen in tumors associated with multiple endocrine neoplasia type 2B syndrome (5). Additionally, multiple endocrine neoplasia is frequently seen in individuals without a history of type 2B syndrome (5)PEN is not associated with neurofibromatosis or multiple endocrine neoplasia type 2 B(8). q

Most of these tumours clinically mimic a benign fibroma or pyogenic granuloma (PG) and are often painless, superficially situated, solitary, firm and non-pigmented nodules(9). The lesion must be differentiated histologically from the neurofibroma, schwannoma, Traumatic neuroma, and leiomyoma(1,2,10-13).

They are composed of a partially encapsulated mass of Schwann cells arranged in interlacing fascicles separated by small clefts, interspersed with a variable amount of tiny axons(14). Immunohistochemical examination shows that the capsule is partially positive for epithelial membrane antigen, suggesting that it is derived from peripheral nerves, and the cells in the nodule are positive for S-100 proteins (12). The neurofibroma that may be associated with Von-Recklinghausen disease, it contains the basic substance mucopolysaccharide. It also has fewer axons with myelin sheath and no capsule. Schwannoma contains Antoni type A and B tissue with Verocay bodies and lacks axons. In traumatic neuroma, there is scar and inflammatory cells as well as axonal and Schwann cell proliferation. Leiomyoma is a spindle cell lesion that consists of muscle cells and can be easily distinguished with immunohistochemical stains (1,2,10-13).

4. CONCLUSION

PEN was suggested to be a hamartomatous growth of Schwann cells which outgrow the axons with no atypical features(10). The only definitive treatment for palisading encapsulated neuroma is surgery. With adequate surgical excision, which is the treatment of choice, no recurrences have been reported so far(15).

REFERENCES

1. Reed RJ, Fine RM, Meltzer HD. Palisaded, encapsulated neuromas of the skin. *Arch Dermatol* 1972;106:865–70.
2. Magnusson B. Palisaded encapsulated neuroma (solitary circumscribed neuroma) of the oral mucosa. *Oral Surg Oral Med Oral Pathol Oral Radiol Endod* 1996;82:302-4.
3. Batra J, Ramesh V, Molpariya A, Maan KK. Palisaded Encapsulated Neuroma: An Unusual Presentation. *Indian Dermatol Online J.* 2018 Jul-Aug;9(4):262-264. doi: 10.4103/idoj.IDOJ_354_17. PMID: 30050817; PMCID: PMC6042183.
4. Cardoso TA, dos Santos KR, Franzotti AM, et al. Traumatic neuroma of the penis after circumcision—case report. *An Bras Dermatol* 2015;90:397-399.

-
5. Fletcher CD. Solitary circumscribed neuroma of the skin (so-called palisaded, encapsulated neuroma): a clinicopathologic and immunohistochemical study. *Am J Surg Pathol* 1989;13:574–80.
 6. Scolyer RA, Ferguson PM. Solitary circumscribed neuroma. In: The WHO Classification of Tumours Editorial Board, editor. WHO classification of tumours. Soft tissue and bone tumours. 5th ed. Lyon: IARC Press; 2020. p. 245-6.
 7. Kutzner H. Solitary circumscribed neuroma. In: Fletcher CD, Bridge JA, Hogendoorn PCW, Mertens F, editors. WHO classification of tumours of soft tissue and bone. 4th ed. Lyon: IARC Press; 2013. p. 181-2.
 8. Neville BW, Damm DD, Allen CM, Chi AC. Soft tissue tumors. In: Neville BW, Damm DD, Allen CM, Chi AC, eds. Oral and maxillofacial pathology, 4th ed. St. Louis: Elsevier, 2016:491e5.
 9. Mortazavi N, Gholami A, Amini Shakib P, Hosseinkazemi H. Palisaded Encapsulated Neuroma of the Tongue Clinically Mimicking a Pyogenic Granuloma: A Case Report and Review of Literature. *J Dent (Tehran)*. 2015; 12(7): 537-41.
 10. Dover JS, From L, Lewis A. Palisaded encapsulated neuromas. *Arch Dermatol* 1989;125:386–9.
 11. Argenyi ZB. Newly recognized neural neoplasms relevant to the dermatopathologist. *Dermatol Clin* 1992;10:219–34.
 12. Megahed M. Palisaded encapsulated neuroma (solitary circumscribed neuroma). A clinicopathologic and immunohistochemical study. *Am J Dermatopath* 1994;16:120–5.
 13. Mayorga M, Acebo E, Val-Bernal JF. Palisaded encapsulated neuroma of the nasal fossa. *Otolaryngol Head Neck Surg* 1998;119:141–3.
 14. Dubovy SR, Clark BJ. Palisaded encapsulated neuroma (solitary circumscribed neuroma of skin) of the eyelid: Report of two cases and review of the literature. *Br J Ophthalmol* 2001;85:949-51.
 15. Hall LD, Ferringer T. Palisaded encapsulated neuroma. *Cutis*. 2013; 92: 167, 177-8.
