

Comparison of the Distance of the Erector Spinae Muscle from the Skin at Different Thoracal Levels and Different Positions Under Ultrasonography

Ultrasonografi Eşliğinde Erektör Spina Kasının Farklı Torakal Seviyelerde ve Farklı Pozisyonlarda Cilde Olan Uzaklığının Karşılaştırılması

Muhammed Halit SATICI¹ , Orhan BİNİCİ² 

¹Department of Anesthesiology and Reanimation, Health Sciences University, Konya City Hospital, Konya, TURKIYE

²Department of Anesthesiology and Reanimation, Harran University Faculty of Medicine, Sanliurfa, TURKIYE

Abstract

Background: The erector spinae plane block can be executed at various thoracic levels and in different positions. Our study aimed to determine the optimal distance of the erector spinae muscle from the skin and to identify the best ultrasonography imaging quality across different thoracic levels and positions.

Materials and Methods: The erector spinae muscle was located using a high-frequency 10-15 MHz linear ultrasound probe at distinct thoracic levels (T1-T2, T5-T6, T11-T12) and in various positions (lateral, sitting, and prone).

Results: The proximity of the erector spinae muscle to the skin was found to be significantly closer at the T5-T6 level compared to the T1-T2 and T11-T12 levels ($p = 0.001$; $p < 0.01$). In the prone position, the distance of the erector spinae muscle to the skin was significantly lower than in the lateral and sitting positions ($p = 0.001$; $p < 0.01$).

Conclusions: In an ESPB to be applied at the T5-T6 thoracal level and in the prone position, the erector spinae muscle is closer to the skin, and the ultrasound image is better.

Key Words: Erector spinae plane block, peripheral nerve block, ultrasonography

Öz

Amaç: Erektör spina düzlem bloğu çeşitli torasik seviyelerde ve farklı pozisyonlarda gerçekleştirilebilir. Çalışmamız, Erektör spina kasının deriden optimal mesafesini belirlemeyi ve farklı torakal seviye ve pozisyonlarda en iyi ultrasonografi görüntüleme kalitesini belirlemeyi amaçladı.

Materyal ve Metod: Erektör spina kası, yüksek frekanslı 10-15 MHz doğrusal ultrason probu kullanılarak farklı torakal seviyelerde (T1-T2, T5-T6, T11-T12) ve çeşitli pozisyonlarda (yan, oturma ve yüzüstü) konumlandırıldı.

Bulgular: Erektör spina kasının cilde yakınlığının T1-T2 ve T11-T12 seviyelerine göre T5-T6 seviyesinde anlamlı olarak daha yakın olduğu görüldü ($p=0.001$; $p<0.01$). Yüzüstü pozisyonda erektör spina kasının cilde mesafesi yan ve oturma pozisyonlarına göre anlamlı derecede düşüktü ($p=0.001$; $p<0.01$).

Sonuç: T5-T6 torakal seviyede ve yüzüstü pozisyonda uygulanacak erektör spina plan bloğunda erektör spina kası cilde daha yakın olup ultrason görüntüsü daha iyidir.

Anahtar Kelimeler: Erektör spina düzlem bloğu, Periferik sinir bloğu, Ultrasonograf

Corresponding Author / Sorumlu Yazar

Dr. Muhammed Halit SATICI
Akabe, Adana Çevre Yolu Cd. No:135/1,
42020, Konya, TURKIYE

E-mail: halit_satici@hotmail.com

Received / Geliş tarihi: 23.05.2024

Accepted / Kabul tarihi: 07.08.2024

DOI: 10.35440/hutfd.1489020

*This study is derived from a graduate thesis.
Date: 2023 year No: 805424 (taken from the
national thesis center).*

Introduction

Interfascial plane blocks, such as the erector spinae plane block (ESPB), have become more common with the increased use of ultrasonography (USG). First used by Forero et al. in 2016 for thoracic neuropathic pain, ESPB is now applied for analgesia in thoracotomy, breast surgery, cardiac surgery, vertebral surgery, cholecystectomy, and inguinal hernia repair across cervical, lumbar, and thoracic levels (1, 2). USG-guided ESPB involves identifying the target level, visualizing the trapezius, rhomboid, erector spinae muscles, and vertebral transverse process (TP), and injecting a local anesthetic between the lower wall of the erector spinae muscle and TP (1). ESPB can be administered as a continuous infusion with a catheter or as a single shot and can be performed in various positions such as sitting, lateral, and prone (3, 4). The success of nerve blocks depends on the position and other factors, with few studies exploring different positions for ESPB. The primary objective of this study is to determine the thoracic level at which the erector spinae muscle is closest to the skin for the clearest ultrasound imaging. The secondary objective is to identify the position that provides the most favorable ultrasound imaging results for the erector spinae muscle.

Materials and Methods

Ethical Approval and Registration

Harran University Faculty of Medicine Clinical Research Ethics Committee (Decision Date: 06.09.2021, Number: 21.15.13) approved the study. Participants in the study were provided with detailed information regarding the research objectives and the methodology employed. Informed consent was secured through both oral and written agreements. Universal ethical rules and the Declaration of Helsinki conducted this study.

Inclusion and Exclusion Criteria

This study included participants aged 18 to 65 who were classified under ASA (American Society of Anesthesiologists) levels I–II and scheduled for surgeries such as cholecystectomy, mastectomy, inguinal hernia repair, or thoracic operations. The exclusion criteria encompassed individuals unwilling to participate, those for whom peripheral nerve blocks were contraindicated, uncooperative individuals, patients with disabilities that could interfere with the procedure, emergency cases, individuals with scoliosis, pregnant or breastfeeding women, those with trauma or surgical scars, and patients classified as ASA III, IV, or V.

Study Protocol

Patient demographic characteristics were documented, and participants were situated in the preoperative anesthesia room without receiving any premedication.

A high-frequency linear probe, ranging from 10 to 15 megahertz (MHz), from the ultrasound machine [Esaote My Lab 30 Gold (USA)] was positioned on the dorsal surface of the patients. The patients were firstly examined with their

hands tied around the umbilicus and their right sides in an upright sitting position, secondly with their right sides in the lateral decubitus position lying on their left sides with their hands at their sides, and thirdly with their right sides in the prone position with their hands extended to their sides and their heads turned to the left.

The C7 vertebra was counted by palpation, and T1-T2 vertebrae were determined by using the linear probe of USG immediately below it, the T4 vertebra was determined anteriorly corresponding to the nipple, and T5-T6 vertebrae were determined immediately below it, the T10 vertebra was determined anteriorly reaching to the umbilicus, and T11-T12 vertebrae were determined immediately below it. After identifying the spinous processes of the relevant vertebrae (T1-T2, T5-T6, and T11-T12) in the sitting, lateral, and prone positions, these locations were marked 3 cm laterally on the patients' backs. Subsequently, the transverse processes of these vertebrae were visualized. The high frequency 10-15 MHz linear probe of USG was placed in the sagittal position, and the subcutaneous tissue, rhomboid, trapezius, and erector spinae muscles were identified on the USG screen. After the erector spinae muscle and the process connected to the relevant vertebra were identified, the most prominent image was obtained, the USG was frozen, and the distance from the upper center point of the screen to the vertebral process was measured and recorded.

Statistical Analysis

Statistical analysis was conducted using SPSS software (version 21; SPSS Inc., Chicago, IL, USA). Descriptive statistical methods including mean, standard deviation, median, frequency, and percentage were employed to analyze the study data, which will be reported as mean \pm standard deviation, ratios, or rates. For categorical variables, the chi-square test was utilized. The normality of quantitative data was assessed using the Shapiro-Wilk test and visual methods. The Student-t test was applied to compare two groups with normally distributed quantitative variables. For non-normally distributed quantitative variables within a group, the Friedman test was used, and pairwise comparisons were conducted using the Wilcoxon signed-ranks test with a Bonferroni correction. Pearson correlation analysis was employed to examine the relationships between quantitative variables. A p-value of less than 0.05 was considered statistically significant.

Results

A total of 86 patients, comprising 43 females and 43 males, were initially assessed for eligibility in this study. However, three female patients were excluded due to refusal to give consent, and three male patients were excluded following the development of vagal stimulation during a position change. The study encompassed a total of 80 participants, with an equitable gender distribution consisting of 50% females (n=40) and 50% males (n=40). (Figure 1).

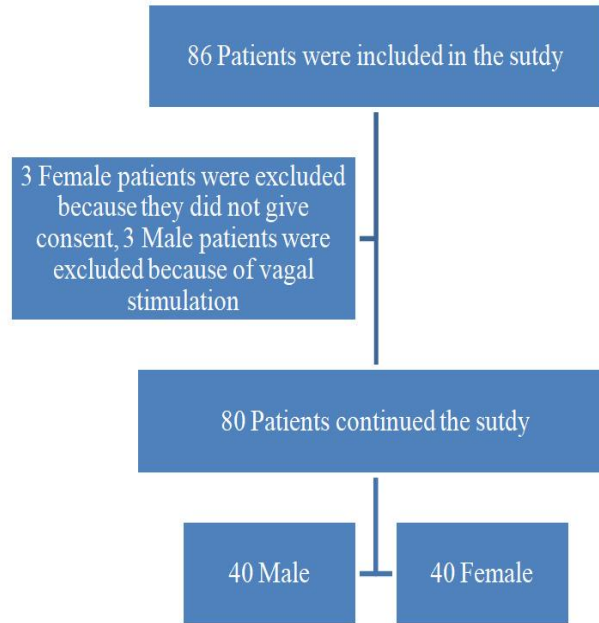


Figure 1. Consort flow diagram

As body mass index (BMI) measurements of the participants increased, there was a notable expansion in the distance from the erector spinae muscle to the skin. This was observed in various positions (sitting, lateral, and prone)

and at different thoracic levels (T1-T2, T5-T6, and T11-T12). The correlation between higher BMI and increased muscle-skin distance was found to be statistically significant ($p = 0.002$; $p < 0.01$) (Table 1).

Table 1. Distribution of Demographic Characteristics

Age	Mv \pm Sd	34.94 \pm 12.15
	Median (Min - max)	34 (18 - 65)
Gender	Female	40 (50.0)
	Male	40 (50.0)
Weight	Mv \pm Sd	71.15 \pm 13.31
	Median (Min - Max)	70.5 (44 - 95)
Height	Mv \pm Sd	168.45 \pm 8.44
	Median (Min - Max)	169 (152 - 187)
BMI	Mv \pm Sd	25.05 \pm 4.28
	Median (Min - Max)	24.9 (16.9 - 34.9)

Mv: Mean value, Sd: Standard deviation BMI: Body mass index

A statistically significant variation was observed in the distance from the skin to the thoracic levels among patients in sitting, lateral, and prone positions ($p = 0.001$; $p < 0.01$). Pairwise comparisons revealed that the distance to the skin at thoracic levels T5-T6 was significantly shorter compared

to the distances at thoracic levels T1-T2 and T11-T12 ($p = 0.001$; $p = 0.001$; $p < 0.01$; respectively). Additionally, the distance to the skin at thoracic levels T1-T2 was found to be significantly shorter than at thoracic levels T11-T12 ($p = 0.001$; $p < 0.01$) (Table 2).

Table 2. Posture Positions Evaluations According to Thoracal Level

The distance of the erector spinae muscle from the skin		Thoracal Level			p	
		T1 - T2	T5 - T6	T11 - T12		
Posture Position	Sitting	Mv \pm Sd	23.83 \pm 4.59	20.67 \pm 4.89	28.37 \pm 4.87	^b 0.001
		Median (Min - Max)	23.9 (10.7 -37.7)	20.6 (10 -36.8)	28.5 (16.8 -39.3)	
	Lateral	Mv \pm Sd	22.65 \pm 5.15	20.48 \pm 4.74	27.74 \pm 5.08	^b 0.001
		Median (Min - Max)	22.7 (12 -39.9)	20.1 (10.9 -37.8)	27.95 (15.1 -40.3)	
	Prone	Mv \pm Sd	20.45 \pm 4.90	18.23 \pm 4.59	24,12 \pm 4.79	^b 0.001
		Median (Min - Max)	19.9 (9.7 -33.5)	17.7 (8.2 -32.7)	23.9 (12.8 -40.4)	

^bFriedman Test, $p < 0.01$, Mv: Mean value, Sd: Standard deviation Min: Minimum, Max: Maximum.

Statistically significant differences were observed in the measurements at thoracic levels T1-T2, T5-T6, and T11-T12, depending on the posture of the patients ($p = 0.001$; $p < 0.01$).

Pairwise comparison results indicated that the distance from the skin in patients in a prone position was signifi-

cantly less than that in patients who were in sitting or lateral positions ($p = 0.001$; $p = 0.001$; $p < 0.01$; respectively). Likewise, the results revealed that the distance to the skin in patients positioned laterally was significantly shorter compared to those in a sitting position ($p = 0.007$; $p < 0.01$) (Table 3).

Table 3. Thoracal Level Assessments According to Posture Position

Distance of the erector spinae muscle from the skin		Posture Position			p	
		Sitting	Lateral	Prone		
Thoracal Level	T1-T2	Mv ± Sd	23.83 ± 4.59	22.65 ± 5.15	20.45 ± 4.90	^b 0.001
		Median (Min - Max)	23.9 (10.7 -37.7)	22.7 (12 -39.9)	19.9 (9.7 -33.5)	
	T5-T6	Mv ± Sd	20.67 ± 4.89	20.48 ± 4.74	18.23 ± 4.59	^b 0.001
		Median (Min - Max)	20.6 (10 -36.8)	20.1 (10.9 -37.8)	17.7 (8.2 -32.7)	
	T11-T12	Mv ± Sd	28.37 ± 4.87	27.74 ± 5.08	24.12 ± 4.79	^b 0.001
		Median (Min - Max)	28.5 (16.8 -39.3)	27.95 (15.1 -40.3)	23.9 (12.8 -40.4)	

^bFriedman Test, $p < 0.01$, Mv: Mean value, Sd: Standard deviation Min: Minumum, Max: Maximum.

In our study, if we interpret the image quality as 1 (bad), 2 (good), and 3 (perfect), we reach the best image quality in the prone position. Good image quality is achieved in the lateral position, and mediocre image quality is achieved in the sitting position (Figure 2). In our study, if we interpret the image quality as 1 (bad), 2 (good) and 3 (perfect), we reach the best image quality at the T5-T6 thoracal level. Good image quality is achieved at the T1-T2 thoracal level and mediocre image quality is achieved at the T11-T12 thoracal level (Figure 3).

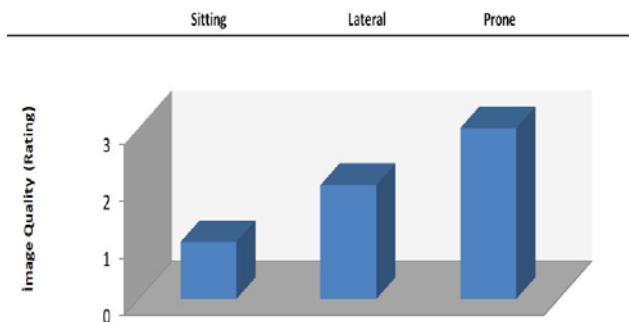


Figure 2. Distribution of Image Quality Ratings According to Posture Positions

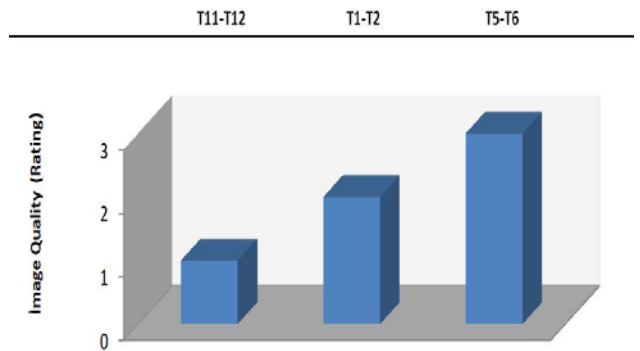


Figure 3. Distribution of Image Quality Scores According to Thoracic Levels

Discussion

Like various other peripheral nerve blocks, the ESPB can be administered at multiple thoracic levels and in different body positions. In our investigation, we assessed the proximity of the erector spinae muscle to the skin at thoracic levels T1-T2, T5-T6, and T11-T12, and in different positions (sitting, lateral, and prone) using ultrasound guidance in a cohort of 80 patients. This study aimed to determine at which thoracic level, and in which position the erector spinae muscle is closest to the skin and where the ultrasound imaging quality is most favorable.

As a result, in our research, we found that the erector spinae muscle was closer to the skin at T5-T6 thoracal levels and in the prone position, and the image quality was better on the USG screen, and we found it significant. As with other peripheral nerve blocks, the practitioners can perform ESPB at various vertebral levels according to the type of surgery, the location of the surgical incision, and the dermatomal area to be affected. It has been emphasized that ESPB provides analgesia up to C7-L2-L3, depending on the level of application (5, 6). In some studies, Dautzenberg et al. Dautzenberg et al. investigated the dermatomal distribution of local anesthesia with a block applied at the T2 and T8 levels, another study was the ESPB used by Schwartzmann et al. at the T10 level to learn the mechanism of action of ESPB, and another study was the block applied by Sharma et al. at the T5 level to reduce the pain of total mastectomy in the postop period (7-9). The superiority, advantages, and disadvantages of ESPB performed at different levels were compared in almost none of the studies.

In contrast to the studies previously discussed, our measurements focused on the distance of the erector spinae muscle to the skin at thoracic levels T1-T2, T5-T6, and T11-T12. We observed that, irrespective of the patient's position, the erector spinae muscle was nearest to the skin at the T5-T6 level. Additionally, the ultrasound imaging quality was superior at this level. As a result, it will be easier to apply an ESPB at the T5-T6 level.

ESPB may affect the quality of the block when performed from different regions and levels. Studies have shown differences in the quality of lumbar and thoracic in ESPB (10).

ESPB is usually applied in prone, lateral decubitus, and sitting positions (4). Although the practitioners generally preferred the sitting position in the early days, they also used ESPB in the prone and side-lying positions after the surgical operation was completed (11, 12). In a study, Ueshima et al. performed bilateral ESPB at the T6 level in the prone position in two pediatric patients undergoing pectus excavatum repair (13). In another study, Hernandez et al. performed an ESPB at the T6 level in a 2-month-old infant in the side-lying position (14). In these two studies, ESPB was performed in only one position, and the advantages and disadvantages of ESPB in different positions were not seen. In contrast to these two studies, we compared ESPB in different positions. We found that ESPB in the prone position is easier to perform and has a much better USG image quality than other positions.

Compared to the side-lying and sitting positions, the prone position allows the patient to be more stable without moving. It also allows the practitioner to tilt the USG probe comfortably. For these reasons, the prone position provides an advantage to the practitioner while performing the block. Of course, the prone position also has disadvantages. Especially in patients under general anesthesia, patients may be physically harmed while changing position. An intubation tube may come out; the mechanical ventilation circuit may be disconnected. Change of position may cause fractures anywhere, especially in elderly patients, and obese patients may have problems (15).

In our study, when we placed the USG probe on the bodies of the patients, we found that the USG probe remained more stable when the patients were in the prone position, our passive hand could be used more functionally, and we could see the trapezius, rhomboid major and erector spinae muscle together with the related transverse process very quickly on the USG screen and that the USG screen image could be obtained best in the prone position. We also observed that the worst position for the practitioner was the sitting position, and the worst USG screen image was obtained in the sitting position.

To obtain the ideal image in an ESPB to be performed from the lumbar region in the prone position, the patient's two arms should be suspended from the side, and the position to be given by placing a roller under the chest is thought to be the most ideal. In patients who have been given a sedative agent, the perfect position is believed to be the lateral decubitus position, with the patient lying on their side (3). In our study, when we gave prone position to the patients, we asked them to extend both arms to their sides; we did not put a pillow under the chest because we thought that it would affect our measurements incorrectly, and we performed our study this way.

In another study similar to our research but performed in the upper extremity, Ababou et al. investigated the effect of

the position given to the extremity on block success, block duration, and block onset time by giving abduction and adduction positions to the arm in axillary block (16). Another similar study is the one conducted by Zaragoza et al., which investigated the relationship between the angle of arm positioning and the quality of ultrasound imaging. They reported that the USG image quality was the best when the tip to the arm increased (90 degrees) and the worst when the arm angle was 0 degrees (17). In the limited number of studies, the evaluation of peripheral nerve blocks in different positions was generally performed for upper extremity blocks. While a linear probe improves image quality in the upper and middle thoracic regions, a convex probe improves image quality as it approaches the lumbar region (18, 19). However, we used the linear probe in all thoracic regions to ensure equal working conditions. In contrast to other limited numbers of studies, we evaluated different positions in ESPB, which is one of the trunk blocks. And in our study, we obtained the best USG image in the prone position, which shows us that it is easier to reach the erector spinae muscle in the prone position, and its applicability will be more straightforward.

Conclusion

The erector spinae muscle is closest to the skin in the prone position and at the T5-T6 thoracic level and the USG image is best at this position and level. We can quickly tell the practitioners who will perform the block that in an ESPB to be completed in the prone position and at the T5-T6 level, we hope that the block will be easier to apply because the erector spinae muscle is closer to the skin and the screen image on USG is better. More studies on this subject are needed.

Ethical Approval: This study was approved by Harran University Faculty of Medicine clinical research ethics committee (Date: 06.09.2021, Number: 21.15.13)

Author Contributions:

Concept: M.H.S., O.B.

Literature Review: M.H.S., O.B.

Design: M.H.S., O.B.

Data acquisition: M.H.S., O.B.

Analysis and interpretation: M.H.S., O.B.

Writing manuscript: M.H.S., O.B.

Critical revision of manuscript: M.H.S., O.B.

Conflict of Interest: The authors have no conflicts of interest to declare.

Financial Disclosure: Authors declared no financial support.

References

1. Forero M, Adhikary SD, Lopez H, Tsui C, Chin KJ. The Erector Spinae Plane Block: A Novel Analgesic Technique In Thoracic Neuropathic Pain. *Regional Anesthesia Pain Medicine*. 2016;41(5):621–627.
2. Tsui BCH, Fonseca A, Munshey F, McFadyen G, Caruso TJ. The erector spinae plane (ESP) block: A pooled review of 242 cases. *Journal of clinical anesthesia*. 2019;53:29-34.
3. Kot P, Rodriguez P, Granell M, Cano B, Rovira L, Morales J,

- et al. The erector spinae plane block: A narrative review. *Korean journal of Anesthesiology*. 2019;72(3):209-220.
4. Luis-Navarro JC, Seda-Guzmán M, Luis-Moreno C, Chin KJ. Erector spinae plane block in abdominal surgery: Case series. *Indian Journal of Anaesthesia*. 2018;62(7):549-54.
 5. Tulgar S, Selvi O, Kapakli MS. Erector Spinae Plane Block for Different Laparoscopic Abdominal Surgeries: Case Series. *Case Rep Anesthesiol*. 2018;18:2108:3947281.
 6. Chin KJ, Adhikary S, Sarwani N, Forero M. The analgesic efficacy of pre-operative bilateral erector spinae plane (ESP) blocks in patients having ventral hernia repair. *Anaesthesia*. 2017;72(4):452-460.
 7. Dautzenberg KHW, Zegers MJ, Bleeker CP, Tan ECT, Vissers KCP, Van Geffen GJ, et al. Unpredictable Injectate Spread of the Erector Spinae Plane Block in Human Cadavers. *Anesthesia Analgesia*. 2019;129(5):e163-e166.
 8. Schwartzmann A, Peng P, Maciel MA, Forero M. Mechanism of the erector spinae plane block: insights from a magnetic resonance imaging study. *Canadian Journal of Anaesthesia*. 2018;65(10):1165-1166.
 9. Sharma S, Arora S, Jafra A, Singh G. Efficacy of erector spinae plane block for postoperative analgesia in total mastectomy and axillary clearance: A randomized controlled trial. *Saudi Journal of Anaesthesia*. 2020;14(2):186-191.
 10. Kose HC, Kose SG, Thomas DT. Lumbar versus thoracic erector spinae plane block: Similar nomenclature, different mechanism of action. *Journal of clinical anesthesia*. 2018; 48:1.
 11. Ahiskalioglu A, Alici HA, Ari MA. Ultrasound guided low thoracic erector spinae plane block for management of acute herpes zoster. *Journal of clinical anesthesia*. 2018; 45:60-61.
 12. Chin KJ, Forero M, Adhikary SD. Reply to Dr Ueshima and Dr Murouchi. *Regional Anesthesia Pain Medicine*. 2017;42(1):124-125.
 13. Ueshima H, Otake H. Clinical experiences of ultrasound-guided erector spinae plane block for thoracic vertebra surgery. *Journal of clinical anesthesia*. 2017;38:137.
 14. Hernandez MA, Palazzi L, Lapalma J, Cravero J. Erector spinae plane block for inguinal hernia repair in preterm infants. *Paediatric Anaesthesia*. 2018;28(3):298-299.
 15. Aksu C, Gürkan Y. Aksu approach for lumbar erector spinae plane block for pediatric surgeries. *Journal of clinical anesthesia*. 2019;54:74-75.
 16. Ababou A, Marzouk N, Mosading A, Sbihi A. The effects of arm position on onset and duration of axillary brachial plexus block. *Anesthesia Analgesia*. 2007;104(4):980-1.
 17. Zaragoza-Lemus G, Hernández-Gasca V, Espinosa-Gutiérrez A. Ultrasound-guided continuous infraclavicular block for hand surgery: technical report arm position for perineural catheter placement. *Cir Cir*. 2015;83(1):15-22.
 18. Alici HA, Ahiskalioglu A, Aydin ME, Ahiskalioglu EO, Celik M. High volume single injection lumbar erector spinae plane block provides effective analgesia for lower extremity herpes zoster. *Journal of clinical anesthesia*. 2019;54:136-137.
 19. De Cassai A, Andreatta G, Bonvicini D, Boscolo A, Munari M, Navalesi P. Injectate spread in ESP block: A review of anatomical investigations. *Journal of clinical anesthesia*. 2020;61:109669.