

An Unusual Hemorrhagic Shock Caused by Spontaneous Rupture of Hepatocellular Carcinoma: A Case Report

Sıradışı Bir Hemorajik Şok Nedeni
Spontan Hepatosellüler Karsinom Rüptürü: Olgu Sunumu

Mehmet Aziret, Metin Ercan, Kerem Karaman, Necattin Fırat, Erdal Birol Bostancı, Musa Akoğlu

Sakarya University Faculty of Medicine, Department of General Surgery, Sakarya Turkey

Correspondence / Yazışma Adresi:

Op. Dr. Mehmet AZİRET

Adnan Menderes Street Sağlık Sok. No: 195 54100 Adapazarı, Turkey

E-mail: mhmtaziret@gmail.com

Geliş Tarihi / Received : **14.05.2017**

Kabul Tarihi / Accepted : **23.12.2017**

Abstract

- Introduction:** Spontaneous rupture of hepatocellular carcinoma (HCC) is a rare but fatal complication that can be occurred during follow up in advanced stages of chronic liver failure.
- Case Report:** A 66-year-old male was admitted with fade, abdominal distention and tachycardia at the emergency clinic. The patient's hemoglobin level was 5 mg/dl and hematocrit value was 19 %. Abdominal CT detected an extensive hematoma in perihepatic area with a laceration of 37.7x35 mm in the dome of the liver. The tumor mass/HCC was resected with negative surgical margins in hemorrhagic shock status. Patient's postoperative course was uneventful.
- Discussion:** Spontaneous HCC rupture is a catastrophic situation which generally occurs suddenly and leads to coagulopathy, hemodynamic instability and liver failure.
- Conclusion:** Spontaneous HCC rupture is a serious life-threatening complication. If possible, resection of the ruptured HCC in emergency situations is not only lifesaving but also the treatment of choice of the primary disease. (**Sakarya Med J 2017, 7(4):235-239**)
- Key Words:** Hemorrhagic shock; hepatocellular carcinoma (HCC); Spontaneous HCC rupture; Surgical resection

Özet

- Giriş:** Spontan Hepatosellüler Karsinom (HCC) rüptürü nadir görülen mortalitesi yüksek bir komplikasyondur ve genellikle kronik karaciğer yetmezliğinin ileri evrelerinde ortaya çıkmaktadır.
- Olgu Sunumu:** 66 yaşında erkek hasta solukluk, batında distansiyon ve taşikardi nedeniyle acil serviste değerlendirildi. Hastanın hemoglobini 5 gr/dl ve hematokriti % 19 idi. Abdominal BT'de peri-hepatik alanda yaygın hematoma ve karaciğer kubbede segment 5' den 8' e uzanan 37.7 x 35 mm ebatlarında laserasyon hattı tespit edildi. Hasta hemorajik şok tablosunda ameliyata alındı ve HCC negatif cerrahi sınırlar ile rezeksiyon edildi. Hastanın postoperatif takiplerinde sıkıntı olmadı ve taburcu edildi.
- Tartışma:** HCC rüptürü koagülopati, hemodinamik instabilite, karaciğer yetersizliği ve hemorajik şok gibi fatal komplikasyonlar ile karakterize katastrofik bir durumdur. Rüptüre HCC'nin rezeksiyonu mümkünse önerilen tedavi yöntemidir.
- Sonuç:** Spontan HCC rüptürü hayatı tehdit eden ciddi bir durumdur. Acil durumlarda rüptüre tümörün rezeksiyonu hem hayat kurtarıcı hem de primer hastalığın tedavi seçeneğidir. (**Sakarya Tıp Dergisi 2017, 7(4):235-239**)
- Anahtar Kelimeler:** Hemorajik şok; Hepatosellüler Karsinom (HCC); HCC rüptürü; Cerrahi tedavi

Introduction

Hepatocellular carcinoma (HCC) is a high mortal disease resulting in chronic liver failure that generally occurs due to hepatitis B and C viruses¹. HCC is diagnosed more than a half million new people and is the third leading cause of cancer death in worldwide^{1,2}. In addition, 250.000 - 1.000.000 people die annually due to HCC in the world³.

Spontaneous HCC rupture is a significant life-threatening complication and to early diagnose and treatment crucial^{4,5}. The mortality rate in HCC rupture is from 25 up to 75 %⁵. The clinical presentation of HCC rupture includes abdominal pain, vomiting and nausea, paleness, confusion, palpitation, tachycardia, hemodynamic instability⁶. Treatment of spontaneous HCC ruptures consist often by surgical methods and also trans-arterial chemoembolization (TACE) and trans-arterial oily chemoembolization (TOCE) are increasingly more commonly used since two decades. However, surgery is commonly performed in hemodynamic unstable patients⁷⁻¹¹. Herein, we aimed to present an appropriate management of spontaneous HCC rupture superimposed in emergency hemorrhagic shock status.

Case Report

A 66-year-old male patient was evaluated with complaints of abdominal pain, paleness, confusion, nausea and vomiting in emergency room. He had chronic hepatitis B infection. Abdominal distention and right upper abdominal pain was detected on physician examination. His hemoglobin and hematocrit levels were 9 g/dl and 28 %, respectively. Abdominal USG showed an extensive hematoma in the perihepatic area with a mass of 35x30 mm in doom of the liver. A contrast-enhanced CT detected a hematoma in the perihepatic area with a laceration of 37.7x35 mm in liver extending from segment IV to segment VIII (Figure 1). The patient's Alfa-Fetoprotein (AFP) level was 1.32 ng/ml (normal range 0.0 – 8.78 ng / ml). A few hours later, hemoglobin and hematocrit levels have continued to fall to 5 g/dl and 19 %, respectively. It was decided to an explorative laparotomy due to patient's hemodynamic instability. A midline laparotomy was performed after starting erythrocyte suspension, crystalloids and ASA 3-E (American society of anesthesiology- Emergency). Abdominal exploration revealed a

tumoral mass 5 X 4 cm of size in doom of the liver with approximately 2000 ml free hemorrhagic fluid in the abdominal cavity (Figure 2). Hemorrhagic fluid was aspirated and bleeding was controlled with gas-compresses. The tumor mass was resected with negative surgical margins (Figure 3). The resection area was repaired using hemostatic 'U' sutures. The patient was taken to the intensive care unit. The patient's postoperative course was uneventful and he was discharged on 9th postoperative day. The histo-pathological examination of resected specimen revealed HCC. In macroscopic examination, a brown and nodular appearance of the resection material was reported with a diameter of 5x4x1.5 cm (Figure 3). Immuno-histochemical examination detected positive reaction with HepPar-1 and negative reaction with AFP. In tumoral areas with reticulin, it was completely seen deteriorating of the roof. Also the neoplastic liver cells were seen with granular cytoplasm, large nucleus, prominent nucleoli, forming pseudo-glandular structures at the trabecular pattern in the desmoplastic stroma. The neoplastic area was observed staining strongly positive in cytoplasm in immunohistochemical examination. The patient is now well and is under follow-up.

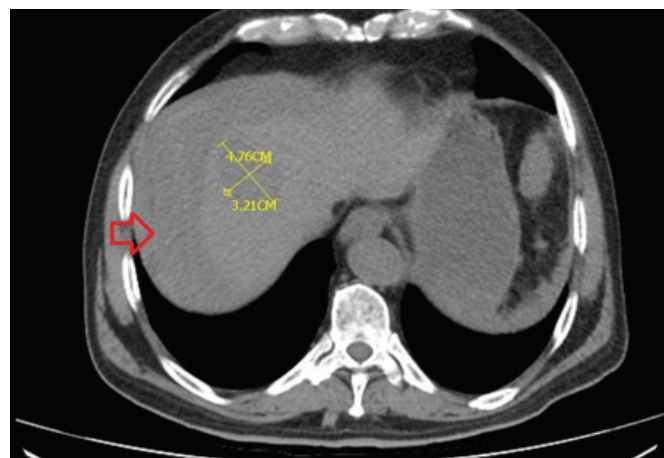


Figure 1. Spontaneous Hepatocellular carcinoma rupture in the abdominal CT (Red Arrow: HCC, Black Arrow: Ascites and hematoma line)

Discussion

HCC is a mortal disease which mostly occurs during the follow up chronic viral hepatitis¹. It is the sixth most seen cancer and third leading cause of cancer death in the world¹⁻³. Spontaneous HCC rupture generally occurs in advanced stages of HCC with a frequ-

ency of 3 - 15 % and the mortality rates changes between 25 - 75 %^{4,5}. Spontaneous HCC rupture incidences are approximately 3.5 % in South Korean, 1 % in Japan, 12.4 % in Thailand and 3 % in the United Kingdom⁵⁻⁸.

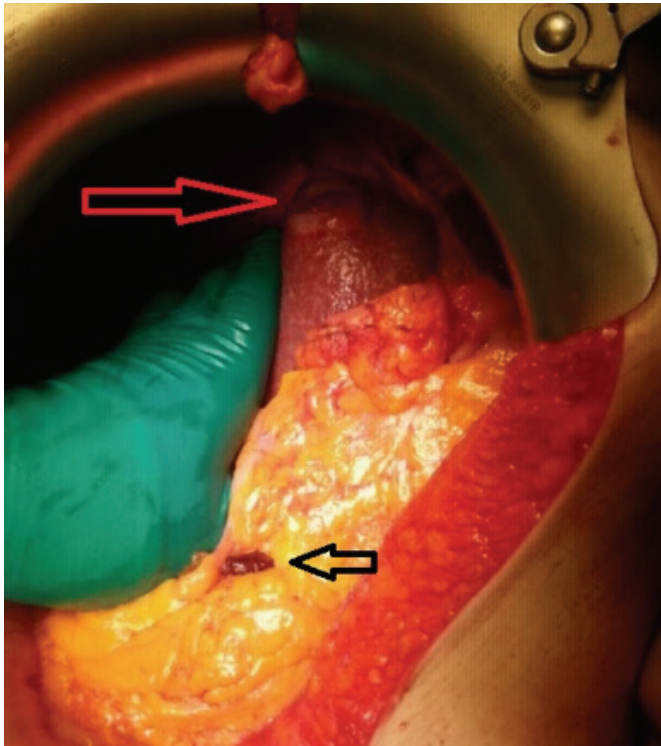


Figure 2. Appearance of Intraoperatively Hepatocellular carcinoma rupture (Red Arrow: HCC, Black Arrow: Hematoma or fibrin)

Management of spontaneous HCC rupture should be considered multidisciplinary by gastroenterology, surgery, interventional radiology, oncology and pathology because HCC rupture is a fatal complication which leads to hemodynamic instability, coagulopathy and liver failure⁵⁻⁹. The clinical presentation of HCC rupture includes abdominal pain, nausea and vomiting, paleness, confusion, fainting, tachycardia, hemodynamic instability and hemorrhagic shock. Fall in hemotocrit levels is remarkable and abdominal USG and CT can detect intraperitoneal fluid, a mass or hematoma in the liver^{9,10}. Our patient was admitted to emergency room with abdominal pain, confusion, hemodynamic instability and hemorrhagic shock which had started in a few hours. We performed the emergency laparotomy with diagnosis of hemorrhagic shock due

to the patient's chronic hepatitis B history, promptly fall in hemotocrit, intraperitoneal fluid and mass in the liver in USG and CT.

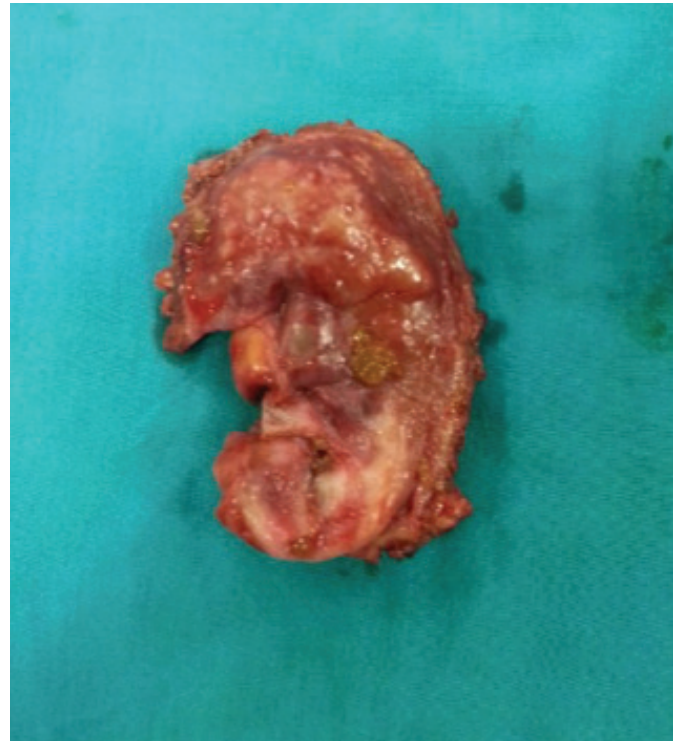


Figure 3. Resection specimen of HCC rupture

In patients with liver cirrhosis, spontaneous HCC rupture generally occurs spontaneously. Liver cirrhosis can be diagnosed with clinic symptoms and signs such as portal hypertension (encephalopathy, oesophageal varices, ascites, splenomegaly or platelet count $< 100000 / \text{mm}^3$) or USG^{10,11}. Liver cirrhosis is often evaluated with 'Child-Turcotte-Pugh' (CTP) and 'Model for End-stage Liver Disease' (MELD), and stage of HCC can be used with staging system of 'Barcelona Clinic Liver Cancer (BCLC)¹². In BCLC staging system, patients with stage 0 with very early HCC are optimal candidates for liver resection, transplantation or percutaneous, and patients with stage B having intermediate HCC may benefit from TACE. In patients with stage C having advanced (metastases or vascular invasion) HCC, may receive new agents like sorafenib, and patients at stage D with end-stage disease will receive supportive treatment^{12,13}. Acute spontaneous ruptured-HCC is classified at stage D (BCLC stage D). Our patient had stage D liver disease,

and he was in the fifth months of follow up.

In patients with HCC rupture, early diagnosis and treatment is crucial. Surgery is the most commonly performed treatment modality for HCC rupture¹⁴. Additionally, TACE and trans-arterial oily chemoembolization (TOCE) are another alternative treatment option in selected cases where surgery is not suitable. In the study by Jin et al⁵, surgery tended to provide better survival benefit than TACE. In an analysis of 250 cases with spontaneous rupture of HCC complicating cirrhosis conducted by et al Cherqui¹⁴, it was found that emergency resection is the treatment of choice in these patients, and TACE is an alternative to surgery in high co-morbid patients or may be used as bridging before liver resection. In the study by Miyamoto et al⁶ including 172 cases with spontaneous rupture of a HCC, it is recommended that emergency hemostatic procedures should be implemented to avoid hemorrhagic shock and two-stage hepatectomy may be considered, if possible. In the study by Ngan et al¹⁵, the role of TACE in the ruptured-HCC was carried out. They found that TACE is the treatment of choice in life-threatening hemorrhagic conditions with a total bilirubin level of ≤ 50 micromol/l. However, in patients with bilirubin level > 50 micromol/l, they found that TACE is rarely effective for prolonging survival. In the study by Liu et al¹⁶, which compared surgery with Transarterial oily chemoembolization (TOCE), they found longer survival after hepatectomy than the TOCE (25.7 months versus 9.7 months). In patients with HCC ruptures, many studies have been carried out for comparison surgery with TACE and TOCE. TACE and TOCE are minimal invasive methods and they are generally performed in selected cases^{16,17}. However, the surgical treatment is better than TACE/TOCE in terms of overall survival in patients with unstable HCC ruptures^{18,19}. In our spontaneous rupture of HCC, we performed the liver resection, and the patient is well with outpatient in fifth months.

Conclusion

Spontaneous HCC rupture is a catastrophic complication which has high risk of fatal progression. If possible, resection of the ruptured tumor mass in emergency situations is not only lifesaving but also the treatment of choice of the primary disease.

Acknowledgments:

This study was not supported by any institution and company. This study was presented as the oral presentation at 4th National Congress of Gastroenterology Surgery.

Conflict of interest:

There is not any conflict of interest.

References

1. Forner A, Llovet JM, Bruix J. Hepatocellular carcinoma. *Lancet* 2012; 379: 1245-1255
2. Siegel R, Ma J, Zou Z, Jemal A. Cancer statistics, 2014. *CA Cancer J Clin* 2014; 64: 9-29
3. Yang T, Lau WY, Zhang H, Huang B, Lu JH, Wu MC. Grey zone in the Barcelona Clinic Liver Cancer Classification for hepatocellular carcinoma: Surgeons' perspective. *World J Gastroenterol*. 2015 Jul 21;21(27):8256-61.
4. Yeh CN, Lee WC, Jeng LB, Chen MF, Yu MC. Spontaneous tumour rupture and prognosis in patients with hepatocellular carcinoma. *Br J Surg* 2002; 89: 1125-1129
5. Jin YJ, Lee JW, Park SW, Lee JI, Lee DH, Kim YS et al. Survival outcome of patients with spontaneously ruptured hepatocellular carcinoma treated surgically or by transarterial embolization. *World J Gastroenterol*. 2013 Jul 28;19(28):4537-44.
6. Miyamoto M, Sudo T, Kuyama T. Spontaneous rupture of hepatocellular carcinoma: a review of 172 Japanese cases. *Am J Gastroenterol* 1991; 86: 67-71
7. Chearanai O, Plengvanit U, Asavanich C, Damrongsak D, Sindhvananda K, Boonyapisit S. Spontaneous rupture of primary hepatoma: report of 63 cases with particular reference to the pathogenesis and rationale treatment by hepatic artery ligation. *Cancer* 1983; 51: 1532-1536
8. Clarkston W, Inciardi M, Kirkpatrick S, McEwen G, Ediger S, Schubert T. Acute hemoperitoneum from rupture of a hepatocellular carcinoma. *J Clin Gastroenterol* 1988; 10: 221-225
9. Lai EC, Wu KM, Choi TK, Fan ST, Wong J. Spontaneous ruptured hepatocellular carcinoma. An appraisal of surgical treatment. *Ann Surg* 1989; 210: 24-28.
10. Seung Rim Han, Jong Man Kim, Gyu-Seong Choi, Jae Berm Park, Choon Hyuck David Kwon, Sung Joo Kim, and Jae-Won Joh. Protrusion of hepatocellular carcinoma is a predictor of early recurrence in hepatectomy patients after spontaneous rupture. *Ann Surg Treat Res*. 2016 Jul; 91(1): 17-22.
11. Di Lelio A, Cestari C, Lomazzi A, Beretta L. Cirrhosis: diagnosis with sonographic study of the liver surface. *Radiology* 1989; 172: 389-392
12. Llovet JM, Burroughs A, Bruix J. Hepatocellular carcinoma. *Lancet* 2003; 362: 1907-1917
13. Pons F, Varela M, Llovet JM. Staging systems in hepatocellular carcinoma. *HPB (Oxford)*. 2005;7(1):35-41.
14. Cherqui D, Panis Y, Rotman N, Fagniez PL. Emergency liver resection for spontaneous rupture of hepatocellular carcinoma complicating cirrhosis. *Br J Surg* 1993; 80: 747-749
15. Ngan H, Tso WK, Lai CL, Fan ST. The role of hepatic arterial embolization in the treatment of spontaneous rupture of hepatocellular carcinoma. *Clin Radiol* 1998; 53: 338-341
16. Liu CL, Fan ST, Lo CM, Tso WK, Poon RT, Lam CM et al. Management of spontaneous rupture of hepatocellular carcinoma: single-center experience. *J Clin Oncol*. 2001 Sep 1;19(17):3725-32.
17. Zhong F, Cheng XS, He K, Sun SB, Zhou J, Chen HM. Treatment outcomes of spontaneous rupture of hepatocellular carcinoma with hemorrhagic shock: a multicenter study. *Springerplus*. 2016 Jul 16;5(1):1101.
18. Kirikoshi H, Saito S, Yoneda M, Fujita K, Mawatari H, Uchiyama T et al. Outcomes and factors influencing survival in cirrhotic cases with spontaneous rupture of hepatocellular carcinoma: a multicenter study. *BMC Gastroenterol* 2009; 9: 29
19. Chen MF, Jan YY, Lee TY. Transcatheter hepatic arterial embolization followed by hepatic resection for the spontaneous rupture of hepatocellular carcinoma. *Cancer* 1986; 58: 332-335

