



Killing Beans; Two Cases of Asphyxia Due to Bean Seed Aspiration Öldüren Fasulyeler; Fasulye Tohumu Aspirasyonu Sonucu İki Asfiksi Olgusu

Abdulkadir Yıldız¹

¹Section of Forensic Medicine, Sırnak, Turkey.

Objective

Tracheobronchial foreign body aspiration is a common childhood emergency, constituting a major cause of mortality. Foreign body aspiration should be kept in mind in children who have persistent cough, wheezing, and unilateral pulmonary findings in radiologic imaging. Bronchoscopy is still the most commonly used and reliable diagnosis and treatment method. To enable visualization of the entire tracheobronchial tree, all clinically suspected tracheobronchial foreign body aspiration cases should be monitored in a hospital setting.

Case: In this report two cases of asphyxia due to aspiration of food material (bean seed) have been presented that may be easily missed during examinations and radiographic imaging.

Conclusion: This report highlights the importance of clear-cut diagnosis and effective treatment of tracheobronchial foreign body aspiration in children to reduce complications and mortality.

Keywords: Forensic Medicine, Autopsy, Postmortem, Foreign Body Aspiration, Bean Seed

Amaç

Trakeabronşiyal yabancı cisim aspirasyonları çocukluk döneminde ölüme sebebiyet veren sık görülen bir acil durumdur. Israr eden öksürük, hışıltılı solunum ve radyolojik görüntüleme tek taraflı akciğer bulguları olan çocuklarda yabancı cisim aspirasyonu akılda bulundurulmalıdır. Bronkoskopi tanı ve tedavide hala en sık kullanılan geçerliliği kabul edilmiş yöntemdir. Trakeabronşiyal sistemin tamamı görüntülenmeden klinik olarak şüpheli tüm trakeabronşiyal yabancı cisim aspirasyonları hastanede yatırılarak monitorize edilmelidir.

Olgular: Bu yazıda, muayene ve radyografik görüntüleme sırasında kolayca gözden kaçabilen yiyecek materyali (fasulye tohumu) aspirasyonuna bağlı gelişen iki farklı asfiksi olgusu sunulmuştur.

Sonuç: Bu yazıda, çocuklardaki trakeabronşiyal yabancı cisim aspirasyonlarına bağlı komplikasyon ve mortaliteyi azaltmada hızlı ve kesin tanı ve etkili tedavinin önemi vurgulanmıştır.

Anahtar Kelimeler: Forensic Medicine, Autopsy, Postmortem, Foreign Body Aspiration, Bean Seed

Introduction

Most asphyxia deaths caused by foreign body aspiration occur in children, although it can also occur in specific high-risk groups of adults, such as individuals with underlying esophageal diseases, mental retardation or psychiatric illnesses or individuals who are incarcerated. We report two cases of children less than 2 years of age, without any previous medical history, who died 4-6 hours after aspirating a bean seed. At autopsy, the foreign body was found wedged in the carina and obstructing the right and left bronchus origin. In this report we also highlight the importance of parents' awareness as well as continuation of effort in part of the attending doctors until mitigation of the disease.

Case Report

Case 1, a 1-year-old female child, and Case 2, a 2-year-old female child, both with a history of recent foreign body aspiration, were taken to the Forensic Medicine section due to unknown sudden death. Complete autopsy, including brain examination, was carried out 4-6 hours after death for both

cases. Case 1 was 77 cm in height and weighed 10560 g and Case 2 was 81 cm in height and weighed 8790 g. External examination of the entire bodies of the cases determined no evidence of stabbing, firearms or weapons injuries, cord marks on the neck, acute poisoning or sexual assault and the finding from the usual toxicological screening was negative in both cases.

For Case 1, internal examination indicated that the ribs, clavicle and the sternum were intact with no fractures. The heart was removed and weighed as 43g. It contained dark red blood, and was without lethal malformations. A small amount of serous fluid that was considered to be physiological was drained from both chest cavities. The lungs had the macroscopic appearance of petechial hemorrhages (Fig. 1-B-D). The left and right lungs weighed 45g and 87g, respectively, and were deeply congested and over-inflated. In the right lung, atelectasis of the upper and middle lobes was seen. A single white bean seed (14x 0.5x 0.6 mm in diameter) was found in the trachea, just above the bifurcation of the trachea. It was concluded that the bean seed occluded the trachea

completely (Fig. 1-D-F). A white-yellow fluid found in the trachea contained a small amount of foam. There were no signs of pneumothorax. There was deep congestion in the rest of the viscera. Light microscopy indicated severe pulmonary congestion and edema. Some alveoli were enlarged with the destruction of alveolar walls. In the left lung, alveoli were incompletely expanded with normal structure.

For Case 2, internal examination indicated that the heart weighed 57 g; bilaterally the chest cavities were clean and macroscopic examination of lungs revealed minimal congestion. The left and right lungs weighed 108g and 83g, respectively and were over-inflated. In the right lung, atelectasis of the upper and middle lobes was seen. A single, white bean seed (11x 0.5x 0.7 mm in diameter) was found in the right main bronchus. It was concluded that the bean seed totally occluded the right bronchus (Fig. 1-C). Yellowish sticky mucoid fluid was found in the distal segment of the occluded bronchus (Fig. 1-E). In both cases, the abdominal organs were observed to be in their anatomical place with no

evident macroscopic pathology. Specimens of other tissues showed no other pathologic lesions, except for congestion in both cases.

The autopsy examinations concluded the cause of death of these cases was asphyxia associated with bean aspiration, which was missed by their parents as well as medical professionals.

Discussion

In forensic medicine practice, the diagnosis of asphyxia by autopsy examination is generally difficult because of the non-specific autopsy findings (1). Although visceral congestion, petechiae, hyper-inflated lung and mucoid deposition in the obstructed segment are seen, they can also occur in deaths caused by other causes, and are therefore regarded as non-specific. In asphyxia due to obstruction in the air-ways, patient history and airway occlusion are the only parameters that indicate choking. Therefore, every patient with suspected foreign body aspiration must be evaluated until the entire

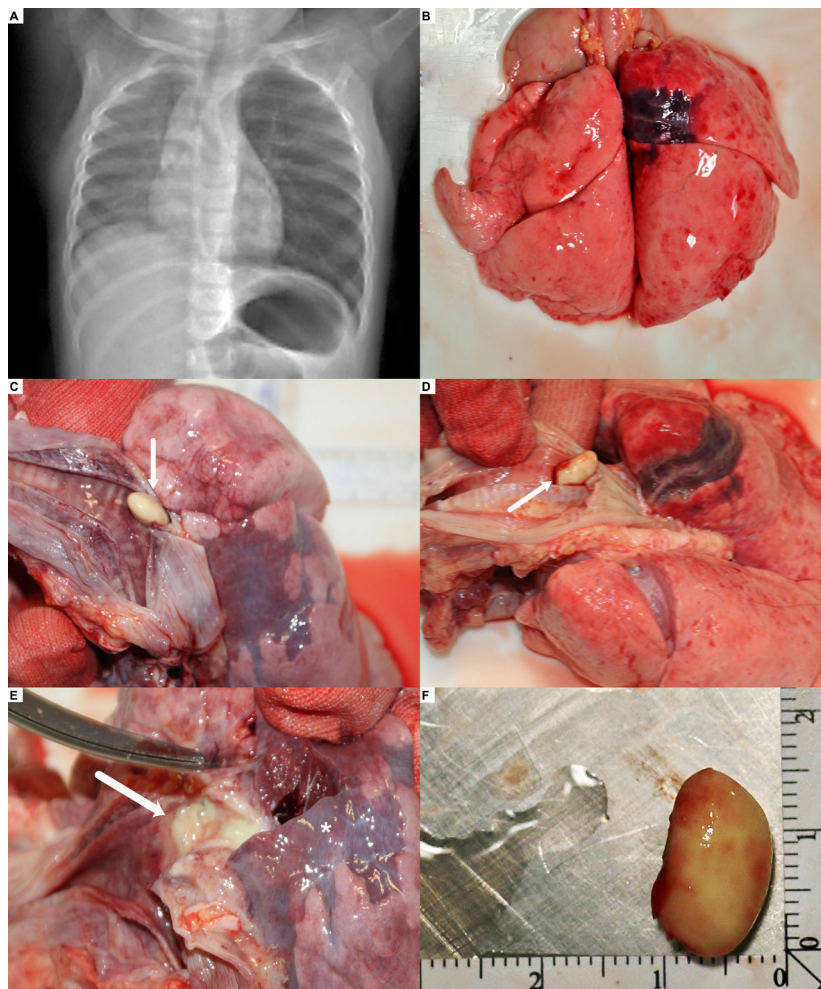


Figure 1A. The difference in air gap between the right and left lung as seen in the chest X-ray of Case 1. **B** - Macroscopic appearance of petechial hemorrhages (Case 1). **D,F** - The bean seed that totally occluded the trachea (Case 1). **C** - The bean seed that totally occluded the right bronchus (Case 2). **E** - Yellowish sticky mucoid fluid that was found in the distal segment of the occluded bronchus (Case 2).

air-way, from trachea to the smallest bronchus, is clear. In the present case (Case 1), the medical history indicated that although the parents of the dyspneic child stated that she had swallowed a bean seed, the physician in the emergency department did not carry out a complete examination. First an X-ray was carried out, which revealed air entrapment / hyperinflation but did not provide any indication of the presence of a foreign body. This was followed by direct visualization with flexible bronchoscopy but only up to the level of the trachea. As nothing abnormal was visualized, the patient was discharged and sent home. She underwent asphyxia at her home after 3-4 hours and was re-admitted to emergency department in an exodus situation. The autopsy examination revealed the exodus diagnosis as asphyxia by a bean seed.

In the second case, choking developed rapidly and the patient did not have a chance to be treated. Therefore, parents must be careful to prevent any foreign body aspiration and should have a basic idea of how to eliminate any obstruction of the airway.

The diagnosis provided at the autopsy was based on patient history and actual detection of the bean seed in the airway. Additionally, during choking by the foreign body, the presence of petechial laryngeal mucosa, hemorrhages and edema can be considered as autopsy findings, as seen in the present cases. In other words, an unequivocally accurate diagnosis of airway obstruction, its sites and mechanisms is impossible by autopsy alone (1). We could merely assume that the presence of the bean seed occluded ventilation in the trachea at the bifurcation, and were supported by the detection of the bean seed in the trachea and the atelectasis of the right lung. Identification of asphyxia and exclusion of other fatal diseases on autopsy, however, are some of the most useful findings to enhance the accuracy of diagnosis of pediatric asphyxia (1, 2). Foreign body aspiration is still the most common cause of accidental death among children under the age of three years (2). Foreign body aspiration occurs typically when a child is eating or playing and expresses sudden respiratory distress (1, 3). Hard and round food items should be regarded as potential aspiration hazards e.g. boiled sweets, nuts, popcorn, carrots, grapes, sausages, seeds, peas and bread pieces. Coins, marbles, tablets and balloons and parts of toys can also lead to a fatal blocking of the upper airways. Besides radiography and bronchoscopy, a CT scan can be of special value to visualize the foreign body both ante- and post-mortem (3). The reason for avoidance of items with a choking hazard is that children have underdeveloped abilities for chewing and swallowing, high rate of ventilation, immature protective reflexes of the upper aero-digestive tract, and narrow airway, which may not permit easy expulsion of foreign objects (1). The lack of molar teeth decreases their ability to masticate food. In addition, children often place items into their mouths while talking, running, and exploring the environment (3).

Therefore, they may not be attentive during eating.

The aspiration event usually comes to the fore based on the observation of an adult. Although it is not reliable in all cases, the presence of a witness has diagnostic importance (4, 5). Most of the aspirated foreign bodies are food products and radiolucent (90%). Because of this, indirect findings need to be examined further. The most common radiological findings in patients with foreign body aspiration are air entrapment / hyperinflation (33%) (Fig. 1-A) and atelectasis (16%) (5). Computerized tomography (CT) can reveal an undetectable foreign body on x-ray graphs, airway edema, and hyperinflation (4). If a foreign body is suspected, flexible bronchoscopy is strongly recommended if it cannot be diagnosed by examination and radiographic studies and also, rigid bronchoscopy is safer, because during this procedure, the patients can be ventilated and foreign body can be easily extracted or pushed to distal airways (4, 5).

Conclusion

Every year, several cases of tracheobronchial aspiration of foreign bodies are seen in children and a part of them cannot be saved. The basics of the management of these frightful incidents are early diagnosis and rapid intervention. In comparison to bronchial foreign bodies, tracheal foreign bodies need faster therapeutic intervention. Rigid bronchoscopy should be the principal method in the diagnosis and management of this event. The most important preventive measures against the foreign body aspirations are education in basic first aid of the general public as well as better awareness and training of health personnel. Postmortem chest CT in suspected choking cases may be helpful for the diagnosis of the cause of asphyxia.

References

1. Takamiya M, Niitsu H, Saigusa K, Dewa K. Pediatric autopsy case of asphyxia due to salmon egg (ikura) aspiration. *Pediatrics International* 2016; 58(9): 899–901.
2. Chiu C-Y, Wong K-S, Lai S-H, Hsia S-H, Wu C-T. Factors predicting early diagnosis of foreign body aspiration in children. *Pediatric Emergency Care* 2005; 21(3): 161–4.
3. Meyer FS, Trübner K, Schöpfer J, Zimmer G, Schmidt E, Püschel K, et al. Accidental mechanical asphyxia of children in Germany between 2000 and 2008. *International Journal of Legal Medicine* 2012; 126(5): 765–71. doi:10.1007/s00414-012-0737-Z.
4. Salih AM, Alfaki M, Alam-Elhuda DM. Airway foreign bodies: A critical review for a common pediatric emergency. *World Journal of Emergency Medicine* 2016; 7(1): 5-12.
5. Mortellaro VE, Iqbal C, Fu R, Curtis H, Fike FB, St Peter SD. Predictors of radiolucent foreign body aspiration. *Journal of Pediatric Surgery* 2013; 48(9): 1867–70.