

A Familiar Face in the Treatment of Immunoglobulin A Vasculitis: Colchicine

Merve Cansu POLAT, Mehveş IŞIKLAR EKİCİ, Melike Mehveş KAPLAN, Elif ÇELİKEL, Zahide EKİCİ TEKİN, Vildan GÜNGÖRER, Cüneyt KARAGÖL, Nimet ÖNER, Didem ÖZTÜRK, Emine ÖZÇELİK, Yasemin UĞUR ES, Sultan Nilay YOĞUN, Banu ÇELİKEL ACAR

Department of Pediatric Rheumatology, Ankara Bilkent City Hospital, Ankara, Türkiye

ABSTRACT

Objective: The aim of this study was to evaluate immunoglobulin A vasculitis (IgAV) patients on colchicine therapy and determine the causative factors leading to the initiation and maintenance of colchicine.

Material and Methods: This retrospective study was conducted receiving IgAV patients on colchicine at our clinic between January 2013 and June 2023. Demographic, clinical, and laboratory data of IgAV patients were obtained from their electronic medical records.

Results: A total of 33 IgAV patients receiving colchicine, 20 (60.6%) males and 13 (39.4%) females, were included in the study. The mean age at diagnosis of IgAV was 111.6±45.5 months. Colchicine was initiated in 13 (39.4%) patients with persistent rash, 8 (24.2%) with severe gastrointestinal tract involvement, seven (21.2%) with generalized/severe rash, and five (15.2%) with recurrent IgAV. The median elapsed time to colchicine initiation was 30 (10.5-60) days. The median duration of colchicine usage was ten (IQR, 6-54) months. Colchicine treatment was discontinued in 14 patients after a median 6.5 (IQR, 3-11.2) months. At the last visit, 13 (39.4%) patients were receiving colchicine for familial Mediterranean fever (FMF), four (12.1%) for recurrent IgAV, and two (6.1%) for persistent rash.

Conclusion: Colchicine should be kept in mind especially in the presence of severe, persistent or recurrent rash. Early initiation of colchicine treatment should be considered in IgAV patients with severe GI tract disease, especially in countries where FMF is common.

Key Words: Colchicine, Immunoglobulin A vasculitis, Leukocytoclastic vasculitis, Recurrence

INTRODUCTION

Immunoglobulin A vasculitis (IgAV; also known as Henoch-Schoenlein purpura), is a multisystemic disease characterized by cutaneous, gastrointestinal (GI) tract, articular, and renal involvement. Although IgAV is the most common vasculitis of childhood, its etiology and pathogenesis are still uncertain (1). Clinical manifestations are

diagnostic, but sometimes skin biopsy may be required in the presence of atypical or persistent rash. The histopathological finding of IgAV is leukocytoclastic vasculitis (LCV) characterized by IgA deposition mostly in dermal capillaries and postcapillary venules (2). It is often a self-limiting disease. Sometimes severe and generalized skin rash, severe GI tract symptoms, or renal involvement may require pharmacological treatment. Corticosteroids are the first agent recommended for these patients. In patients

Conflict of Interest : On behalf of all authors, the corresponding author states that there is no conflict of interest.

Ethics Committee Approval : This study was conducted in accordance with the Helsinki Declaration Principles. This study was approved by the Ankara Bilkent City Hospital Clinical Researches Ethics Committee (Date: 24/01/2024, Decision No: E2-24-6126).

Contribution of the Authors : **POLAT M:** Constructing the hypothesis or idea of research and/or article, Planning methodology to reach the conclusions, Organizing, supervising the course of progress and taking the responsibility of the research/study, Taking responsibility in patient follow-up, collection of relevant biological materials, data management and reporting, execution of the experiments, Taking responsibility in logical interpretation and conclusion of the results, Taking responsibility in necessary literature review for the study, Taking responsibility in the writing of the whole or important parts of the study, Reviewing the article before submission scientifically besides spelling and grammar. **IŞIKLAR EKİCİ M:** Planning methodology to reach the conclusions. **KAPLAN MM:** Organizing, supervising the course of progress and taking the responsibility of the research/study, Taking responsibility in patient follow-up, collection of relevant biological materials, data management and reporting. **ÇELİKEL E:** Taking responsibility in logical interpretation and conclusion of the results, Taking responsibility in patient follow-up. **EKİCİ TEKİN Z:** Taking responsibility in patient follow-up. **GÜNGÖRER V:** Taking responsibility in patient follow-up. **KARAGÖL C:** Taking responsibility in patient follow-up. **ÖNER N:** Collection of relevant biological materials, data management and reporting. **ÖZTÜRK D:** Collection of relevant biological materials, data management and reporting. **ÖZÇELİK E:** Collection of relevant biological materials, data management and reporting. **UĞUR ES Y:** Taking responsibility in necessary literature review for the study. **YOĞUN SN:** Taking responsibility in necessary literature review for the study. **ÇELİKEL ACAR B:** Constructing the hypothesis or idea of research and/or article, Planning methodology to reach the conclusions, Taking responsibility in the writing of the whole or important parts of the study, Reviewing the article before submission scientifically besides spelling and grammar.

How to cite : Polat MC, Işıklar Ekici M, Kaplan MM, Çelikel E, Ekici Tekin Z, Güngörer V, et al. A Familiar Face in The Treatment of Immunoglobulin A Vasculitis: Colchicine. Turkish J Pediatr Dis. 2025;19(1): 38-42.

0000-0003-3279-8435 : POLAT M
0009-0008-7942-3714 : IŞIKLAR EKİCİ M
0000-0002-8012-2774 : KAPLAN MM

0000-0003-0129-4410 : ÇELİKEL E
0000-0002-5446-667X : EKİCİ TEKİN Z
0000-0002-9838-2603 : GÜNGÖRER V

0000-0002-2987-1980 : KARAGÖL C
0000-0003-0403-151X : ÖNER N
0000-0002-9911-9225 : ÖZTÜRK D

0000-0003-4619-8342 : ÖZÇELİK E
0000-0002-3691-8708 : UĞUR ES Y
0000-0002-8287-5972 : YOĞUN SN

0000-0002-1808-3655 : ÇELİKEL ACAR B

Correspondence Address :

Merve Cansu POLAT
Department of Pediatric Rheumatology,
Ankara Bilkent City Hospital, Ankara, Türkiye
E-posta: mervegulerpolat@gmail.com

Received : 11.07.2024
Accepted : 16.09.2024
DOI: 10.12956/tchd.1514723

with an inadequate response to corticosteroids or in organ- or life-threatening conditions, other immunosuppressive therapies such as intravenous immunoglobulin, cyclophosphamide, or mycophenolate mofetil (MMF) are suggested (3).

Colchicine is an alkaloid that acts its anti-inflammatory effects by binding to tubulin and disrupting microtubule assembly. In fact, inhibition of microtubule polymerization inhibits neutrophil chemotaxis and activity, reduces neutrophil-platelet interaction and aggregation, and consequently suppresses inflammation (4). Although colchicine is mainly used in the treatment of familial Mediterranean fever (FMF) and gout, it is also recommended in the management of LCV (5). In addition, the use of colchicine alone or in combination with dapson is known to lead to prompt and complete resolution of persistent and/or recurrent cutaneous vasculitis (6).

In this study, we aimed to evaluate IgAV patients receiving colchicine therapy and determine the causative factors leading to the initiation and maintenance of colchicine.

MATERIALS and MERTHODS

Study design and participants

This study retrospectively analysed the electronic medical records of pediatric IgAV patients receiving colchicine who fulfilled the Ankara 2008 classification criteria at a tertiary referral hospital between January 2013 and June 2023. According to these criteria, petechiae or purpura with predominance in the lower extremities should be accompanied by at least one of the following four criteria: (1) IgA predominance on histopathology, (2) acute onset arthralgia/arthritis, (3) acute onset abdominal pain, (4) renal involvement. Patients diagnosed with any vasculitis, such as adenosine deaminase 2 deficiency or ANCA-associated vasculitis, and/or a connective tissue disease at presentation or during follow-up were excluded (7). During the study period, the electronic medical records of 54 IgAV patients receiving colchicine were evaluated. Eight patients, all with FMF, were excluded as they were receiving colchicine treatment at the time of IgAV diagnosis. Our country is one of the regions where FMF is common. Since the association between FMF and IgAV is well known, all IgAV patients are evaluated for FMF symptoms in our clinic. MEFV mutation is performed in patients with a suspicious clinical history of FMF. Thirteen patients who fulfilled Yaçınkaya-Özen criteria or Eurofever classification criteria and therefore initiated colchicine were not included in the study (8,9). The remaining 33 patients were included in the study.

Demographic, clinical, and laboratory data were obtained from the electronic medical records. Age at diagnosis, gender, follow-up period, systemic involvements, and treatment modalities were analyzed. The time of colchicine initiation, duration of usage, and causative factors for initiation and continuation were recorded. MEFV gene analysis were noted. Histopathological features of skin biopsy were analyzed with hematoxylin-eosin staining and direct immunofluorescence.

Persistence of active purpuric or petechial rash after the first month of IgAV diagnosis was defined as persistent rash. General/severe rash was defined as rash above the waist or necrotic or bullous rash.

Severe GI tract involvement was defined as massive GI tract bleeding, refractory ongoing abdominal pain despite receiving corticosteroid, or severe abdominal complications such as intestinal perforation or obstruction, intussusception, and hypovolemic shock.

Recurrence was defined as a new flare of symptoms attributable to IgAV in a patient previously diagnosed with IgAV after a symptom-free period of at least one month.

Disease activity was assessed using the pediatric vasculitis activity score (PVAS) based on the evaluation of the following nine organ systems: general, skin, mucous membranes/eyes, ear/nose/throat, cardiovascular, respiratory, GI tract, renal, and nervous systems (10).

This study was approved by the Ankara Bilkent City Hospital Clinical Researches Ethics Committee (Date: 24/01/2024, Decision No: E2-24-6126). All procedures were performed in accordance with the ethical rules and the principles of the Declaration of Helsinki.

Statistical analyses

Statistical analyses were performed using the IBM Statistical Package for the Social Sciences, version 25.0 (SPSS Inc., Armonk, NY, IBM Corp., USA). Descriptive analyses were presented using means and standard deviations for normally distributed variables, medians and interquartile range for the non-normally distributed and ordinal variables, and frequencies for the categorical variables.

RESULTS

A total of 33 IgAV patients receiving colchicine, 20 (60.6%) males and 13 (39.4%) females, were included in the study. The mean age at diagnosis of IgAV was 111.63 ± 45.52 months. Rash was present in all patients at presentation. Twenty-nine patients (87.9%) had purpura, two (6.1%) had bullous rash and the other two (6.1%) had necrotic rash. The rash was localized on the lower extremities and buttocks in 17 patients (51.5%). In ten (30.3%) patients, rash was also present in the upper extremities and trunk. The remaining 6 (18.2%) patients had rash all over the body including the face. In addition, subcutaneous edema was present in 14 (42.4%) patients. Following skin involvement, the GI tract was the most commonly involved system (63.6%), followed by articular (33.3%), renal (18.2%), and scrotal (9.1%) involvement, respectively.

MEFV mutation was performed in all patients except two (6.1%). Eleven (33.3%) patients had no mutation, while 18 (54.5%) had at least one exon 10 mutation. FMF symptoms occurred in 13 (72.2%) of 18 patients with exon 10 mutation during follow-up, and colchicine was continued.

Skin biopsy was performed in 5 (15.2%) patients with persistent rash, 3 (9.1%) with recurrent IgAV, and 2 (6.1%) with generalized/severe skin involvement. Findings of skin biopsy were consistent with LCV with IgA deposits.

Table I: Demographic and clinical characteristics of immunoglobulin A vasculitis patients receiving colchicine

	IgAV patients receiving colchicine (n=33)
Gender, Male*	20 (60.6)
Age at diagnosis (months) [†]	111.6±45.5
Follow-up time (months) [‡]	24 (8-60)
Colchicine initiation time (days) [‡]	30 (10.5-60)
Duration of colchicine use (months) [‡]	10 (6-54)
System involvement*	
Cutaneous	33 (100)
Rash	33 (100)
Subcutaneous edema	14 (42.4)
Articular	11 (33.3)
Gastrointestinal tract	21 (63.6)
Renal	6 (18.2)
Scrotal	3 (9.1)
Rash distribution*	
Lower extremities and buttocks	17 (51.5)
Upper extremities or trunk	10 (30.3)
Involve face	6 (18.2)
Rash characteristic*	
Purpura	29 (87.9)
Bullous	2 (6.1)
Necrotic	2 (6.1)
MEFV*	
None	2 (6.1)
Negative	11 (33.3)
Positive	
Exon 10 homozygous	2 (6.1)
Exon 10 heterozygous	12 (36.4)
Exon 10/ Exon 10; compound heterozygous	3 (9.1)
Exon 10/ Not Exon 10; compound heterozygous	1 (3)
Other	2 (6.1)
Treatment*	
Corticosteroid (2 mg/kg/day)	29 (80.4)
Pulse methylprednisolone (30 mg/kg/day)	12 (36.4)
Intravenous immunoglobulin	2 (6.1)
Cyclophosphamide	6 (18.2)
Plasmapheresis	1 (3)
Recurrence*	7 (21.2)
Cutaneous	4 (12.1)
Cutaneous + Gastrointestinal tract	2 (6.1)
Cutaneous + Scrotal	1 (3)
Elapsed time until recurrence [‡]	12 (5-48)
PVAS at the time of diagnosis [‡]	2 (2-3)

*:n(%), †: mean±SD, ‡: median (Interquartile range), **IgAV**: Immunoglobulin A vasculitis, **PVAS**: Pediatric Vasculitis Activity Score

Before initiation of colchicine, three (9.1%) patients had not received any treatment except nonsteroidal anti-inflammatory drugs. Seventeen (51.5%) patients received corticosteroids for GI tract involvement, seven (21.2%) for skin involvement, four (12.1%) for GI tract + renal involvement, and two (6.1%) for renal involvement. Immunosuppressive treatment was given to eight (24.2%) patients, and plasmapheresis was performed in one (3%) patient with severe GI tract involvement refractory to steroid treatment. Seven (21.2%) patients developed recurrence a median 12 (IQR, 5-48) months after the first IgAV

diagnosis. Median PVAS was two (IQR, 2-3) points at the time of diagnosis. Demographic, clinical and laboratory characteristics of IgAV patients receiving colchicine are given in Table I.

Colchicine was initiated in 13 (39.4%) patients with persistent rash, eight (24.2%) with severe GI tract involvement, seven (21.2%) with generalized / severe rash, and five (15.2%) with recurrent IgAV. The median elapsed time to colchicine initiation was 30 (10.5-60) days. The median duration of colchicine usage was ten (IQR, 6-54) months. Colchicine was initiated in a total of 20 (60.6%) patients owing to severe or persistent rash. The rash resolved completely with colchicine in all patients except one (3%). This patient was a 16-year-old girl with persistent and generalized rash. MMF was initiated in the 4th month of colchicine treatment as her rash still persisted. She recovered almost completely in the 1st month of MMF treatment. No recurrence was observed after colchicine in any of the patients who were initiated on colchicine due to recurrent IgAV. Colchicine treatment was discontinued in 14 patients after a median 6.5 (IQR, 3-11.2) months. During follow-up, 13 (39.4%) patients were diagnosed with FMF and continued colchicine treatment. Among these patients, seven (21.2%) were receiving colchicine for severe GI tract involvement, three (6.5%) for persistent rash, two (6.1%) for recurrent IgAV and one (3%) for generalized/severe rash. In addition, colchicine was continued in four (12.1%) patients due to recurrent LCV and in two (6.1%) due to persistent rash (Figure 1). The mean duration of colchicine usage was 17.5±12.55 months in patients with recurrent LCV and 7±1.41 months in patients with persistent rash.

DISCUSSION

Immunoglobulin A vasculitis is usually self-limiting, but intensive immunosuppressive therapies may be required in severe organ involvement. The first and most preferred agent is corticosteroids and occasionally other cytotoxic agents may be needed (11). Some patients may not respond to corticosteroids in cases such as severe and generalized rash or recurrent IgAV. Colchicine is an anti-inflammatory drug with a tolerable side effect profile that has been used for years in the treatment of various vasculitides. In this study, it was shown that colchicine treatment was effective in a small group of patients.

Skin manifestations, which are mandatory classification criteria in IgAV, are usually limited to the lower extremities and resolve spontaneously. However, approximately 2% of patients may have a generalized rash, or severe rash with bullous or necrotic characteristics (11,12). Severe cutaneous manifestations are known to be associated with the risk of developing severe GI tract complications and nephritis (13,14). Moreover, necrotic and dehisced bullous lesions may result in infections. Apart from these life- and organ-threatening complications, severe skin lesions may cause social and cosmetic anxiety in patients and their families. In fact, Sestan et al. (13) reported that about half of IgAV patients with severe cutaneous manifestations had permanent skin sequelae (post inflammatory hyperpigmentation or permanent scars). The optimal treatment of IgAV patients with severe cutaneous involvement is still unknown. Corticosteroids are

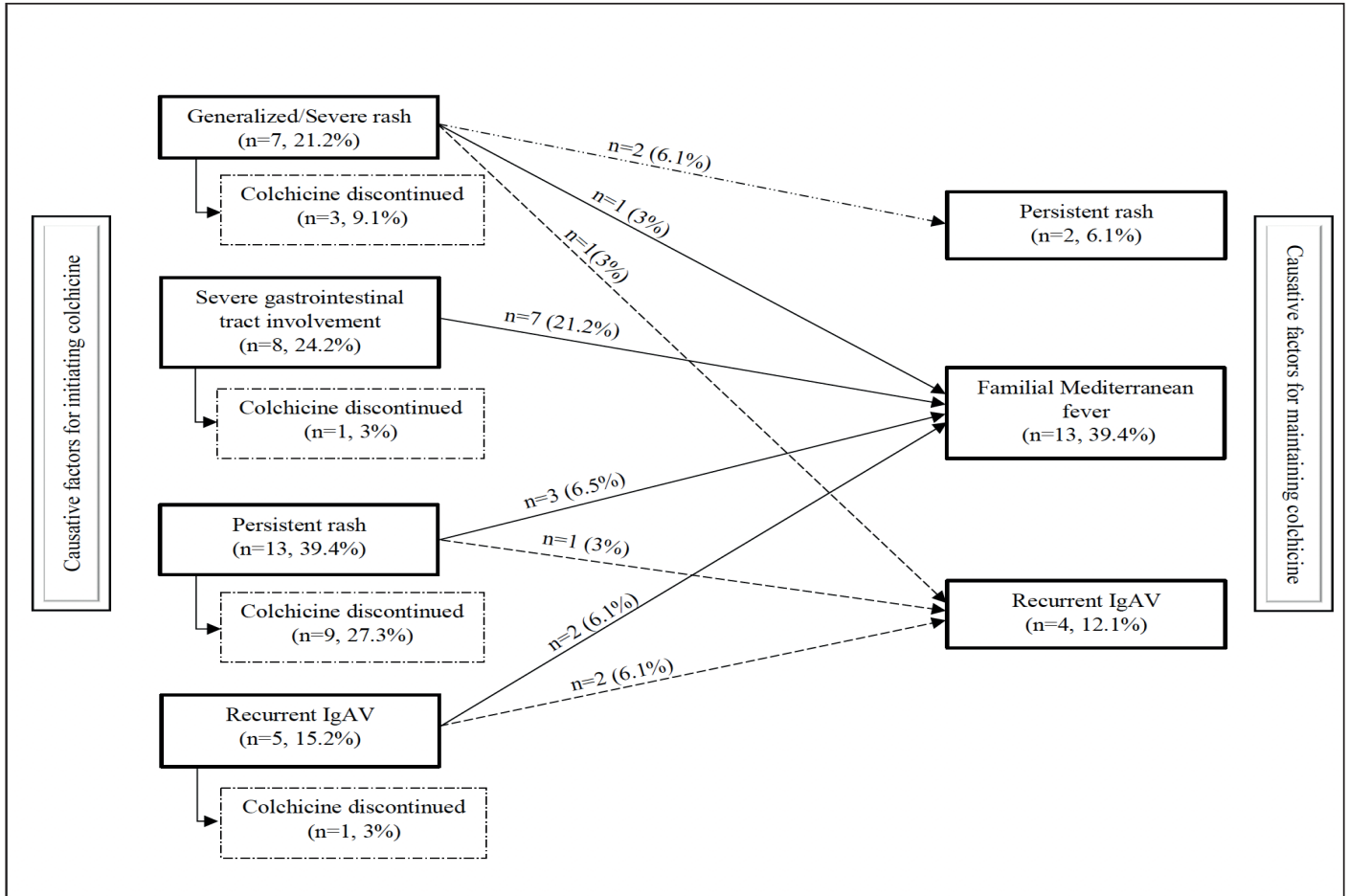


Figure 1: Flowchart showing the reasons for initiating and maintaining colchicine in IgAV patients. **IgAV:** Immunoglobulin A vasculiti

usually the first-line drug of choice for the treatment of severe skin lesions. There are also studies reporting that early corticosteroid treatment reduces scar formation by providing faster resolution of skin symptoms (11,13,15). Similarly, in our study, patients with severe skin involvement received corticosteroid treatment most frequently. However, considering the side effects that may occur with long-term use of corticosteroid therapy, early initiation of steroid-sparing agents is logical. LCV is a small vessel vasculitis histologically characterized by neutrophilic infiltration and nuclear debris around postcapillary venules, fibrin deposits in the vessel wall, and erythrocyte extravasation (16). Considering that colchicine acts its anti-inflammatory effects through neutrophils, it can be predicted that it may be effective in the treatment of LCV. Although there are no randomized studies showing the efficacy of colchicine in pediatric IgAV patients, it has been reported to be an effective treatment option in various case reports (17-19). However, the time of initiation and duration of colchicine use are still unanswered questions. In our study, colchicine treatment was used successfully in patients with severe or persistent skin rash. Nevertheless, all of these patients had received corticosteroids or nonsteroidal anti-inflammatory drugs as previously reported in the literature. Colchicine treatment is beneficial in some cases, as demonstrated by the long-term follow-up of our study, including the period after other immunosuppressives were discontinued.

In IgAV, if there is a concomitant rheumatologic disease and/or uncontrolled inflammation secondary to any disease, the disease course is likely to be more severe than expected or relapse may occur. FMF is the most common autoinflammatory disease caused by gain-of-function mutations in the MEFV gene. Some studies have reported that the presence of MEFV mutations in IgAV patients may be responsible for high inflammation and poor clinical outcome (20, 21). In these studies, it was also reported that GI tract involvement was more severe in the presence of MEFV mutation variant in exon 10. In our study, colchicine treatment was also initiated in eight patients with severe GI tract involvement to suppress inflammation in the acute period. Exon 10 mutation was found in seven patients, and they continued colchicine treatment for FMF.

The main limitation of this study is that it was conducted retrospectively from a single center. However, given that there are only a few case reports of colchicine experience in pediatric IgAV patients, we believe that this largest pediatric cohort data will be informative for clinicians.

CONCLUSION

Although IgAV patients respond well to supportive care or short-term corticosteroid use, colchicine treatment should be kept in mind especially in the presence of severe, persistent or recurrent

rash. In addition, early initiation of colchicine treatment should be considered in IgAV patients with severe GI tract disease, especially in countries where FMF is common.

REFERENCES

- Du L, Wang P, Liu C, Li S, Yue S, Yang Y. Multisystemic manifestations of IgA vasculitis. *Clin Rheumatol* 2021;40:43-52.
- Pillebout E, Sunderkötter C. IgA vasculitis. *Semin Immunopathol* 2021;43:729-38.
- Ozen S, Marks SD, Brogan P, Groot N, de Graeff N, Avcin T, et al. European consensus-based recommendations for diagnosis and treatment of immunoglobulin A vasculitis-the SHARE initiative. *Rheumatology (Oxford)* 2019;58:1607-16.
- Poddighe D, Romano M, Garcia-Bournissen F, Demirkaya E. Conventional and novel therapeutic options in children with familial Mediterranean fever: A rare autoinflammatory disease. *Br J Clin Pharmacol*. 2022;88:2484-99.
- Fraticelli P, Benfaremo D, Gabrielli A. Diagnosis and management of leukocytoclastic vasculitis. *Intern Emerg Med* 2021;16:831-41.
- Chen KR, Carlson JA. Clinical approach to cutaneous vasculitis. *Am J Clin Dermatol* 2008;9:71-92.
- Ozen S, Pistorio A, Iusan SM, Bakkaloglu A, Herlin T, Brik R, et al. EULAR/PRINTO/PRES criteria for Henoch-Schönlein purpura, childhood polyarteritis nodosa, childhood Wegener granulomatosis and childhood Takayasu arteritis: Ankara 2008. Part II: Final classification criteria. *Ann Rheum Dis* 2010;69:798-806.
- Gattorno M, Hofer M, Federici S, Vanoni F, Bovis F, Aksentijevich I, et al. Classification criteria for autoinflammatory recurrent fevers. *Ann Rheum Dis* 2019;78:1025-32.
- Yalçinkaya F, Ozen S, Ozçakar ZB, Aktay N, Cakar N, Düzova A, et al. A new set of criteria for the diagnosis of familial Mediterranean fever in childhood. *Rheumatology (Oxford)* 2009;48:395-8.
- Dolezalova P, Price-Kuehne FE, Özen S, Benseler SM, Cabral DA, Anton J, et al. Disease activity assessment in childhood vasculitis: development and preliminary validation of the Paediatric Vasculitis Activity Score (PVAS). *Ann Rheum Dis* 2013;72:1628-33.
- Nothhaft M, Klepper J, Kneitz H, Meyer T, Hamm H, Morbach H. Hemorrhagic Bullous Henoch-Schonlein' Purpura: case Report and Review of the Literature. *Front Pediatr* 2019;6:413.
- Ramelli V, Lava SA, Simonetti GD, Bianchetti MG, Ramelli GP, Milani GP. Blistering eruptions in childhood Henoch-Schonlein' syndrome: systematic review of the literature. *Eur J Pediatr* 2017;176:487-92.
- Sestan M, Kifer N, Sozeri B, Demir F, Ulu K, Silva CA, et al. Vasculitis Working Party of the Pediatric Rheumatology European Society (PReS). Clinical features, treatment and outcome of pediatric patients with severe cutaneous manifestations in IgA vasculitis: Multicenter international study. *Semin Arthritis Rheum* 2023;61:152209.
- Li Y, Zhang X, Liu H, Li G, Guan W, Zhang T, et al. Severe gastrointestinal involvement in pediatric IgA vasculitis: a retrospective single-center cohort study in China. *Front Pediatr* 2023;11:1194214.
- Den Boer SL, Pasmans S, Wulffraat NM, Ramakers-Van Woerden NL, Bousema MT. Bullous lesions in Henoch Schonlein Purpura as indication to start systemic prednisone. *Acta Paediatr* 2010; 99:781-3.
- Fraticelli P, Benfaremo D, Gabrielli A. Diagnosis and management of leukocytoclastic vasculitis. *Intern Emerg Med* 2021;16:831-41.
- Chan KH, Tang WY, Lo KK. Bullous lesions in Henoch-Schönlein purpura. *Pediatr Dermatol* 2007;24:325-6.
- Saulsbury FT. Successful treatment of prolonged Henoch-Schönlein purpura with colchicine. *Clin Pediatr (Phila)* 2009;48:866-8.
- Allali S, Freitag S, Terrier B, Bodemer C, Chalumeau M. Efficacy of colchicine in a child with relapsing bullous Henoch-Schönlein purpura. *Eur J Pediatr* 2016; 175:147-9.
- Ekinci RMK, Balci S, Bisgin A, Atmis B, Dogruel D, Altintas DU, et al. MEFV gene variants in children with Henoch-Schönlein purpura and association with clinical manifestations: a single-center Mediterranean experience. *Postgrad Med* 2019;131:68-72.
- Cakici EK, Kurt Şükür ED, Özlü SG, Yazılıtaş F, Özdel S, Gür G, et al. MEFV gene mutations in children with Henoch-Schönlein purpura and their correlations-do mutations matter? *Clin Rheumatol* 2019;38:1947-52.