

A Rare Cause of Tension Pneumothorax: Echinococcus Granulosus

Müslüm Gökhan Baskan¹ 

¹ Department of Thoracic Surgery, Sincan Training and Research Hospital, Ankara, Türkiye

Abstract

Hydatid cysts, caused by the Echinococcus parasite, are predominantly found in the liver and the lungs. While pulmonary hydatid cysts can lead to various complications, such as rupture into the bronchus, tension pneumothorax is extremely rare. Diagnosis typically involves a combination of clinical evaluation, radiologic imaging, and serologic testing. In this case presented, an adult patient with tension pneumothorax was diagnosed with a hydatid cyst through these methods. Surgical intervention was necessary to excise the cyst, followed by medical treatment to manage any remaining issues. This case highlights the unusual occurrence of tension pneumothorax as a complication of pulmonary hydatid cysts and emphasizes the importance of prompt diagnosis and treatment.

Key words: Hydatid cyst of the lung, rare complication, tension pneumothorax

INTRODUCTION

Hydatid disease is a zoonotic infection caused by the Echinococcus genus, with Echinococcus (E.) granulosus and E. multilocularis being the most prevalent species in humans. The less are E. vogeli and E. oligarthropoli (1). This disease is particularly endemic in developing countries and can affect multiple organs, with the liver (50-54%) and lungs (35-40%) being the most frequently involved sites. Other organs that can be affected include the kidneys, spleen, brain, skeleton, and heart (2).

The most common complication of pulmonary hydatid cysts is rupture into the bronchus, which can lead to significant respiratory issues. Tension pneumothorax, while a serious condition, remains a very rare complication associated with hydatid cysts. This highlights the importance of early diagnosis and intervention to manage potential complications effectively.

CASE REPORT

The 42-year-old woman's presentation is concerning for a significant respiratory issue. With her history of persistent cough, dyspnea, and right Frank pain, along with vital signs indicating hypotension (70/40 mmHg) and tachycardia (110/min), she is likely in respiratory distress (respiratory rate: 22/min, oxygen saturation: 88). The decreased breath sounds on the right side further support this. Posterior-Anterior chest X-ray (PA CXR) findings of a total pneumothorax on the right, along with accompanying effusion in the right lung lower zone, suggest a significant pleural process. (Figure 1)

After tube thoracostomy, it's encouraging that the patient's vital signs improved significantly, indicating successful decompression of the pneumothorax and drainage of fluid. Although the control PA CXR shows "expansive" findings (Figure 2), massive air leak from

Corresponding Author:
Müslüm Gökhan Baskan, MD
Department of Thoracic Surgery, Sincan Training and Research Hospital, Ankara, Türkiye
E-mail: muslum_gokhan@hotmail.com



Content of this journal is licensed under a Creative Commons Attribution-NonCommercial 4.0 International License.

the tube thoracostomy continued, and a Thorax Computed Tomography (CT) was ordered.

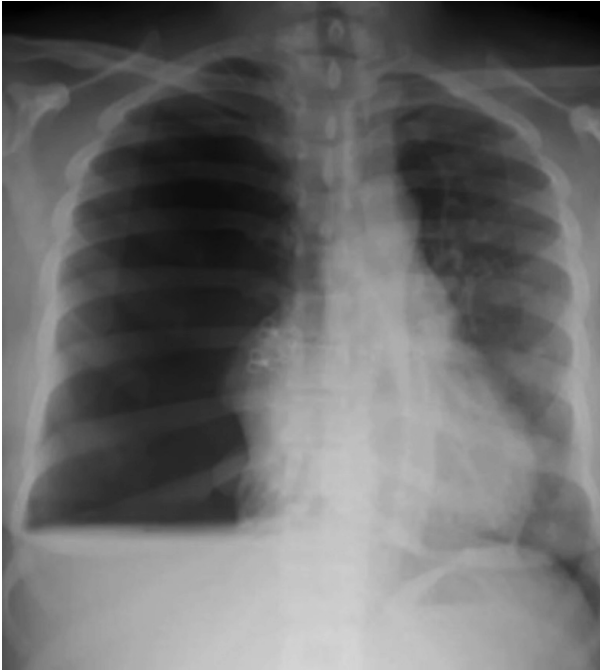

Figure 1. Posterior-Anterior chest X-ray (PA CXR) findings of a total pneumothorax on the right, along with accompanying effusion in the right lung lower zone, suggest a significant pleural process

The thorax CT findings indicating a hydatid cyst cavity that has perforated into the pleural space in the middle lobe of the right lung (Figure 3), an enucleated hydatid cyst membrane located in the posterior costophrenic sinus (Figure 4), pneumothorax on the right, metastatic diffuse milimetric level cystic lesions in bilateral lungs (Figure 5) and a 17 cm type-1 hydatid cyst in the 7th-8th segment of the liver (Figure 4). The patient underwent surgery to address the complications of a perforated hydatid cyst.

Rigid bronchoscopy was performed to aspirate any residual material from the bronchial tree.

The enucleated cyst membrane was removed, and the thoracic cavity was thoroughly washed with povidone-iodine via thoracotomy. The bronchial openings were sutured and the perforated hydatid cyst cavity was quilted, and partial decortication of the parietal pleura was performed. The patient was then placed in supine position, and the liver hydatid cyst was aspirated lapa-

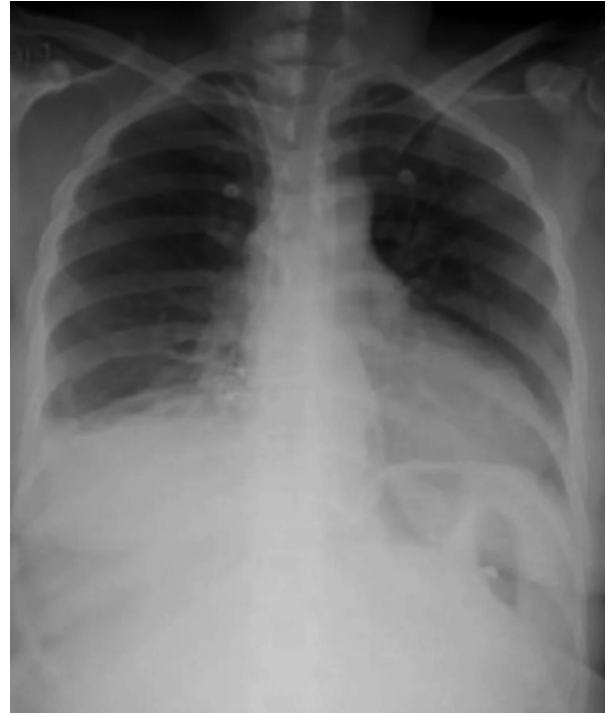

Figure 2. After tube thoracostomy, it's encouraging that the patient's vital signs improved significantly, indicating successful decompression of the pneumothorax and drainage of fluid. Although the control PA CXR shows "expansive" findings

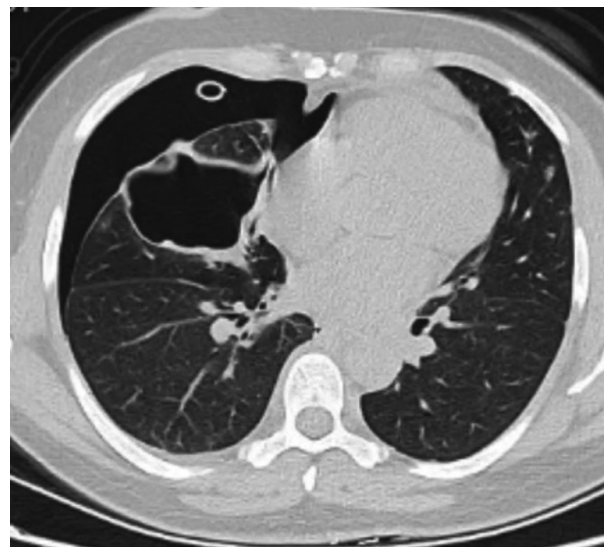


Figure 3. The thorax CT findings indicating a hydatid cyst cavity that has perforated into the pleural space in the middle lobe of the right lung

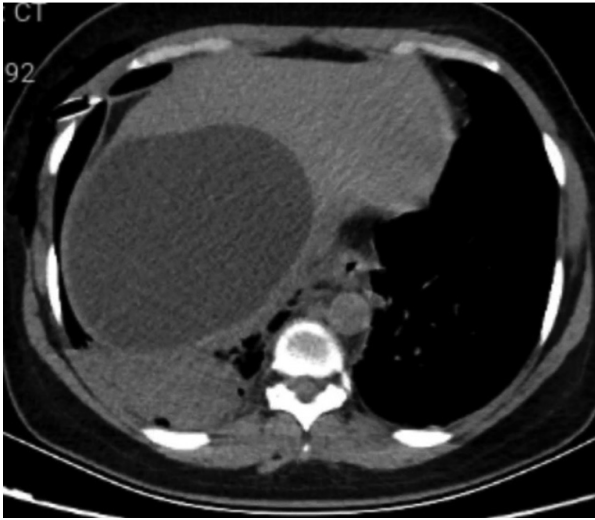

Figure 4. An enucleated hydatid cyst membrane located in the posterior costophrenic sinus and a 17 cm type-1 hydatid cyst in the 7th-8th segment of the liver

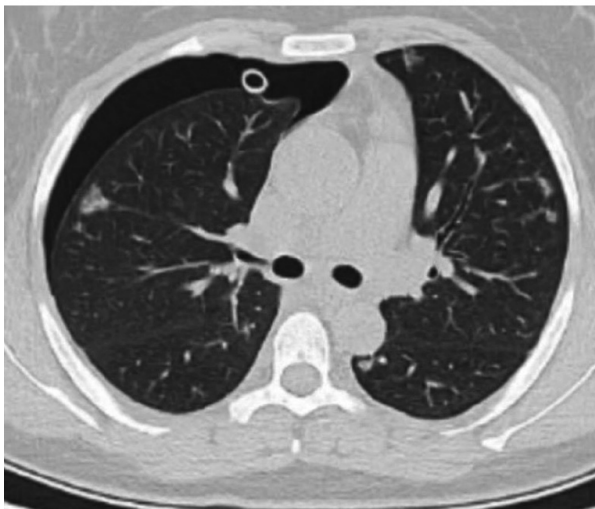


Figure 5. Metastatic diffuse milimetric level cystic lesions in bilateral lungs

roscopically, followed by saline washing by the general surgeon.

Postoperative pathology confirmed the presence of a hydatid cyst membrane. Starting on the 2nd postoperative day, the patient was prescribed albendazole (andazol) at a dosage of 400 mg twice daily, with biochemistry parameters remaining within normal limits. The patient was discharged on the 5th postoperative day and would continue follow-up for 3 months while on albendazole,

with regular monitoring of biochemistry parameters to ensure ongoing safety and effectiveness of the treatment.

DISCUSSION

Pulmonary hydatid cysts are often asymptomatic and typically only become symptomatic when they grow large enough to compress lung tissue or when complications arise. The clinical presentation can vary significantly based on whether the cyst perforates the pleura or the bronchus.

Complications such as perforation into the pleural cavity can lead to hydropneumothorax, while perforation into the bronchus may result in symptoms like asphyxia, bronchospasm, and even anaphylaxis. Pleural complications occur with an incidence ranging from 0.5% to 18.2% (3), Aribas et al. reported that these complication rates are even higher (32.5%) (4). Sayir et al found that ,involving 412 patients, the rate of complicated hydatid cysts was 42.71%. Among these complicated cases, 56.8% had ruptured into the bronchial tree, while 43.2% had perforated into the pleural cavity. The incidence of tension pneumothorax among patients with hydatid cysts that ruptured into the pleura was reported to be 1.52% (5). Cernay et al. reported an incidence of tension pneumothorax of 1.3% in their study of 336 patients with ruptured hydatid cysts (6). If the cyst ruptures into the pleural cavity, it may cause pneumothorax, tension pneumothorax, pleural effusion or empyema (7). In our case, the cyst ruptured and opened into the pleura and caused tension pneumothorax, which is a very rare complication. It is a very rare case because It was accompanied by a giant type-1 hydatid cyst in the liver, and there were also bilateral metastatic diffuse cystic formations of several millimeters in size.

Common symptoms in patients with tension pneumothorax include air hunger, tachycardia, agitation, and severe chest pain. Radiologically, mediastinal compression and shifting are observed, making this a life-threatening condition. Tube thoracostomy is a critical intervention that can significantly improve the patient's overall condition and is often life-saving (5). In our patient, the symptoms associated with tension pneumothorax improved significantly following the tube thoracostomy performed under emergency conditions.

Hydatid cyst rupture can occur spontaneously, as a result of trauma, or iatrogenically. Severe coughing can also trigger rupture. If the cyst is located peripherally, it is more likely to open into the pleural space (4, 5). In our case, the perforated hydatid cyst cavity was located peripherally. Severe cough was the first symptom and there was no history of trauma.

The treatment for hydatid cysts located in the lung is primarily surgical. When hydatid cysts rupture into the pleural space, they can lead to complications such as pleural thickening, secondary echinococcosis, and the formation of adhesions. Kuzucu et al. reported that decortication was performed in 24.4% of patients (7). In our case, partial decortication was performed in the areas of contamination in the parietal pleura.

Medical treatment for hydatid cysts in the lungs is recommended in cases of multiple cysts, when surgery poses significant risks, and both before and after surgical or percutaneous interventions. Albendazole is preferred due to its antihelminthic efficacy being ten times great-

er than that of other medications (8). The recommended dosage of albendazole is 10-15 mg/kg/day, administered in two divided doses for three weeks, followed by a one-week break between treatment sessions, with a total duration of at least three months. Studies have shown that a three-month course of albendazole significantly reduces the viability of protoscoleces and cysts (9). A three-month course of albendazole has been shown to significantly reduce the viability of protoscoleces and cysts (10). In our patient, we administered albendazole treatment for three weeks in two divided doses each month during the postoperative period, monitoring biochemical parameters closely. After a one-week break, we completed the treatment over a total duration of three months.

It is important to remember that tension pneumothorax can very rarely occur as a result of a ruptured hydatid cyst, particularly in endemic areas or in patients with a history of exposure to hydatid cysts. This condition requires urgent intervention and surgical management.

REFERENCES

1. Vurucu S, Yüksel C, Akça A, Önder T, Kayta S, Alkan S. Kist hidatik hastalığının intratorasik ve pulmoner tutulumları. *Phoenix Med J.* 2022;4(3):102-4.
2. Durgun C, Alkan S, Durgun M, Demiray EKD. Türkiye’den kist hidatik konusunda yapmış yayınların analizi. *Black Sea J Health Sci.* 2022;5(1):45-9.
3. Parelkar SV, Gupta RK, Shah H, Sanghvi B, Gupta A, Jadhav V, et al. Experience with video-assisted thoracoscopic removal of pulmonary hydatid cysts in children. *J Pediatr Surg.* 2009;44(4):836-41.
4. Aribas OK, Kanat F, Gormus N, Turk E. Pleural complications of hydatid disease. *J Thorac Cardiovasc Surg.* 2002;123(3):492-7.
5. Sayir F, Cobanoglu U, Sehitogullari A. Surgical treatment of pulmonary hydatid cysts, which perforated to the pleura. *Eurasian J Med.* 2012;44(2):79.
6. Cernay J, Bensenouci A, Boukhelal H, Zaouche A, Grangaud J. The rupture of the pleura: a serious complication of hydatid cyst of the lung in children. *Rev Fr Mal Respir.* 1979;7(1):45-7.
7. Kuzucu A, Soysal Ö, Özgel M, Yologlu S. Complicated hydatid cysts of the lung: clinical and therapeutic issues. *Ann Thorac Surg.* 2004;77(4):1200-4.
8. Anadol D, Özçelik U, Kiper N, Göçmen A. Treatment of hydatid disease. *Pediatr Drugs.* 2001;3:123-35.
9. Nabarro LE, Amin Z, Chiodini PL. Current management of cystic echinococcosis: a survey of specialist practice. *Clin Infect Dis.* 2015;60(5):721-8.
10. Gil-Grande LA, Sánchez-Ruano J, García-Hoz F, Bárcena R, Rodríguez- Caabeiro F, Brasa C, et al. Randomised controlled trial of efficacy of albendazole in intra-abdominal hydatid disease. *Lancet.* 1993;342(8882):1269-72.

Abbreviations list

E: Echinococcus

PA CXR: posterior-anterior chest x-ray

CT: computed tomography

Ethics approval and consent to participate

Ethical committee approval is not required because of this article is a case report. Informed consent was obtained from patient.

Consent for publication

Informed consent was obtained from patient.

Availability of data and materials

The data of the study are not stored digitally or physically.

Competing interests

There is no potential conflict of interest to declare.

Funding

There is no funding source for this case report.

Authors' contributions

Idea/Concept: MGB. Control/Supervision MGB. Data Collection And/Or Processing: MGB. Literature Review: MGB. Writing The Article: MGB. Critical Review: MGB. References And Fundings: MGB.

Acknowledgements

None.