



ORJİNAL MAKALE / ORIGINAL ARTICLE

Balıkesir Sağlık Bilimleri Dergisi / BAUN Sağ Bil Derg
Balıkesir Health Sciences Journal / BAUN Health Sci J
ISSN: 2146-9601- e ISSN: 2147-2238
Doi: <https://doi.org/10.53424/balikesirsbd.1530341>



Developmental Status of Thoracic Limb Bones of 40-Day-Old Watchdog Hybrid Fetus

Şükrü Hakan ATALGIN¹, Mustafa KORKMAZ¹, Semih YILMAZ²

¹ Balıkesir University, Faculty of Veterinary Medicine, Department of Veterinary Anatomy

² Balıkesir University, Faculty of Veterinary Medicine

Geliş Tarihi / Received: 08.08.2024, Kabul Tarihi / Accepted: 04.11.2024

ABSTRACT

Objective: In this study, the developmental status of the thoracic Limb bones of a 40-day-old watchdog hybrid fetus was studied. **Materials and Methods:** Bones of 40-day-old animals were dyed with Inouye technique. Dissections of the bones stored in appropriate solutions were performed. Photographs were taken with a stereomicroscope and a digital camera. Measurements were taken from the dissected legs with a 150 mm Mitutoyo brand caliper. **Results:** It was observed that some of the thoracic limb bones of a 40-day-old watchdog hybrid had a primary ossification center (POC), while some bones did not have a primary and secondary ossification center (SOC). Primary ossification centers were observed in the bodies of the bones of the scapula, humerus, radius, ulna, and ossa metacarpus of the fore limb, but no ossification centers were observed in the proximal and distal ends. Furthermore, ossification centers were not observed in the carpal bones and ossa digitorum manus. **Conclusion:** The formation status and dimensions of POC seen in the bones of the forelimbs of a 40-day-old guard dog hybrid fetus were determined. The ossification centers in guard dog hybrid fetuses were consistent with studies conducted in a large number of domestic animals. As a result, it should mark the ossification in various features such as hormones, environmental factors, and individual variations.

Keywords: Bone, Fetus, Fore Limb, Forty Days Old, Watchdog Hybrid.

40 Günlük Bekçi Köpeği Melezi Ön Ekstremitte Gelişme Durumu

ÖZ

Amaç: Bu çalışmada 40 günlük beğçi köpeği melezinin ön ekstremitte gelişim durumu üzerinde çalışılmıştır. **Gereç ve Yöntem:** Inouye tekniğine göre alizarin red ve alcian blue ile 40 günlük hayvanlara ait kemikler boyandı. Uygun solüsyonlarda saklanan kemiklerin diseksiyonları yapıldı. Stereomikroskop ve dijital kamera ile fotoğrafları çekildi. Disekte edilen bacaklardan 150 mm'lik mitutoyo marka kumpas ile ölçümler alındı. **Bulgular:** 40 günlük beğçi köpeği melezinin ön ekstremitte kemiklerinin bazılarında primer ossifikasyon merkezine sahipken bazı kemikler primer ve sekonder ossifikasyon merkezine sahip olmadıkları gözlemlendi. Ön ekstremitte kemiklerinden scapula, humerus, radius, ulna ve ossa metacarpus'a ait kemiklerin corpus'larında primer ossifikasyon merkezi gözlenirken proximal ve distal uçlarında ossifikasyon merkezi gözlemlenmedi. Ayrıca karpal kemikler ve ossa digitorum manus'ta ossifikasyon merkezlerini gözlemlenmedi. **Sonuç:** Yapılan çalışmada, 40 günlük bir beğçi köpeği melezi fetüsünün ön ayaklarının kemik gelişiminde görülen POC (primary ossification center)'ün oluşum durumu ve boyutları belirlendi. Bekçi köpeği melezi fetüslerindeki kemikleşme merkezleri çoğunlukla evcil hayvanlarda yapılan çalışmalarla uyuyordu. Sonuç olarak, beslenme alışkanlıkları, hormonlar, çevresel faktörler ve kişisel farklılıklar gibi çeşitli faktörlerin kemikleşmeyi etkilediğini belirtmek gerekir.

Anahtar Kelimeler: Bekçi Köpeği Melezi, Fetüs, Kemik, Kırk Günlük, Ön Ekstremitte.

Sorumlu Yazar / Corresponding Author: Şükrü Hakan ATALGIN, Balıkesir University, Faculty of Veterinary Medicine, Department of Anatomy, Balıkesir, Turkey

E-mail: sukruhakan@balikesir.edu.tr

Bu makaleye atıf yapmak için / Cite this article: Atalgın Ş.H., Korkmaz, M., & Yılmaz, S. (2024). Developmental status of thoracic limb bones of 40-day-old watchdog hybrid fetus. *BAUN Health Sci J*, 13(3), 653-656. <https://doi.org/10.53424/balikesirsbd.1530341>



BAUN Health Sci J, OPEN ACCESS <https://dergipark.org.tr/tr/pub/balikesirsbd>

This work is licensed under a Creative Commons Attribution-NonCommercial 4.0 International License

INTRODUCTION

Intramembranous ossification happens in extremity bones, while intracartilaginous ossification occurs in cranium bones especially (Govindarajan & Overbeek, 2006; Zhang et al., 2011). Ossification starts in the embryonic period and proceeds throughout postnatal life. POC (Primary ossification center) which form the body of the bone, first appear during gestation, while one or more SOC (Secondary ossification center) appear in the epiphysis of long bones after birth. This cartilage part, which is obligatory for longitudinal bone development, ossified over time and completes the closure of the cartilage in long bones (Getty, 1975). Understanding the normal growth and ossification processes of bones is critical in the diagnosis and therapy of intrauterine anomalies, developmental disorders and genetic bone diseases (Atalgın & Çakır, 2006; Barone, 1986; Dyce et al., 1987; Williams & Dyson, 1989). Various techniques such as single and double staining techniques (DST), radiography, ultrasonography, MRI and different histological dyeing methods are used to evaluate the stages of ossification. DST in particular have been successfully applied in experimental research on bone development in poultry, rabbits, and mammals (Atalgın & Çakır, 2006; Atalgın & Kürtül, 2009; Atalgın et al., 2007; Sevinç et al., 2017). In the study, the DST of alizarin red (AR) and alcian blue (AB), which offers significant advantages in showing the details of ossification centers, was applied. This study was conducted to visualize the ossification centers in the forelimbs of a approximately 40-day-old watchdog hybrid fetuses and to determine the ossification stages.

MATERIALS AND METHODS

In this study, the right forelimbs of four 40-day-watchdog hybrid were examined. Gender is ignored. Their ages were decided using the crown rump length (CRL) measurements recommended in the studies of Evans, Sack and Henry (1973). It was determined that they were about 40 days old and 55-74 mm long. The obtained samples were kept in 15% formaldehyde mixture and washed with water. They were then preserved in containers containing 90% ethanol. The limbs were stained in a final solution containing AB (300 mg AB and 100 ml 70% ethanol) and AR (100 mg AR and 100 ml 95% ethanol) to notice the ossification stages. It was prepared by adding 100 ml of glacial acetic acid and 1700 ml of 70% ethanol to this solution. Limbs were incubated in the mixed dyeing liquid in an oven at 35 °C for four days and then washed under running water for 2 h. After washing, they were stored in a container containing 2% KOH. In addition, the limbs were cleaned with 20% glycerin and 1% KOH and saved in 55% and 85% glycerin solutions for 7 days. Finally, they were stored in a 100% glycerin solution (Atalgın & Çakır, 2006). Findings and images were taken using a stereo microscope (Nikon SMZ 745T). Digital caliper was used to measure the cartilage primitives and ossified

parts of the bones. Since dead material was used, no ethics committee approval was obtained.

Ethical considerations

Since the study was conducted on dead material, ethics committee approval is not required.

RESULTS

Scapula

The collum scapula was ossified, indicating the presence of a POC. (Figure 1/2) No SOC was observed at this period (Figure 1).

The cartilage border of the scapula was openly noticed. The body of the scapula appeared its typical similarity as it can be seen in the mature period. Cartilago scapula was present (Figure1/1). It was determined that the ossified part of the scapula was not seen homogeneously, the fossa supraspinata was less mineralized than the total area, and the fossa infraspinata showed more ossification. More ossification was observed especially in the sections where the middle parts of the spina scapula meet the body (Figure 1).

Humerus

The primary ossification center (POC) of the humerus was present, constituting the foundational structure of the bone. The POC appeared as a cylindrical tube with two open ends; however, no secondary ossification center (SOC) was observed at either end (Figure 1).

Regarding the antebrachial skeleton, the POC was noted in the bodies of both the radius (Figure 2/2) and ulna (Figure 2/1). It was determined that the density and elongation of ossification were significantly greater in the radius compared to the ulna. No fusion was detected between the two bone models. Additionally, no SOCs were identified at the proximal or distal ends of either the radius or ulna. Upon examination, it was found that the ossification center of the radius appeared lower when viewed laterally, while the relatively longer ulna had its ossification center positioned higher (Figure 2).

Ossa carpi

Cartilage outline was formed in all carpal bones. However, no POC or SOC was observed in any carpal bone (Figure 2).

Ossa metacarpi

A POC (Figure 2/3) was observed in each of metacarpale II, III, IV. It was determined that those in metacarpale III and IV were larger. It was determined that there was no fusion between the bones (Figure 2).

Phalanx

A cartilaginous outline was formed in each of the phalanxes. However, no POC or SOC was observed in any of them (Figure 2).

Total and ossification centre right lengths of bones are shown in table 1.

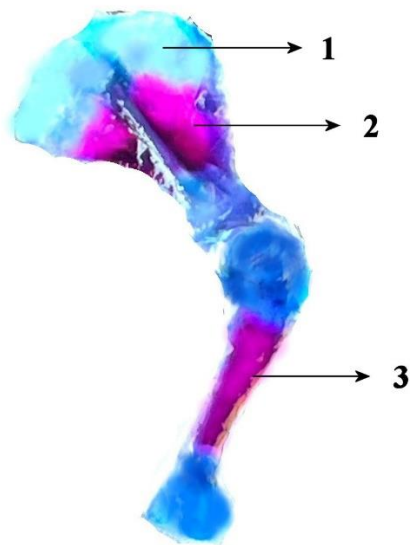


Figure 1. Scapula and Humerus of a 40-day-old watchdog hybrid fetus, 1. Cartilago scapula, 2. POC of scapula, 3. POC of humerus.

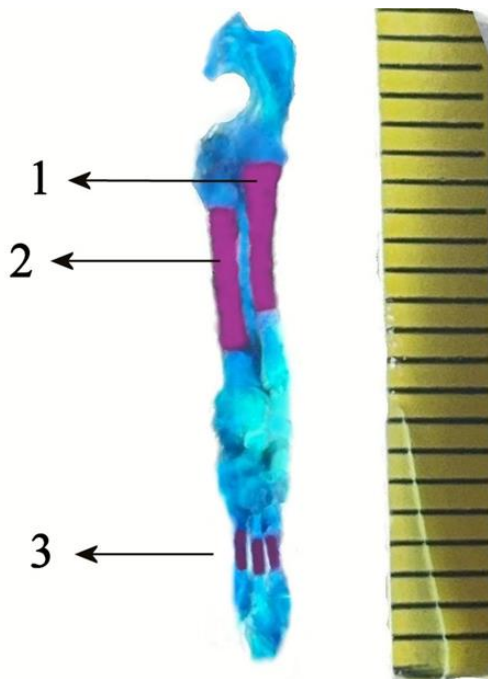


Figure 2. Skeleton antebrachii and ossa metacarpea of a 40-day-old watchdog hybrid fetus, 1. POC of ulna, 2. POC of radius, 3. POC of ossa metacarpea.

Table 1. Total and ossification center right lengths of bones.

Bone (mm)	n	Total Length (average)	POC Length (average)
Scapula	4	9	4.8
Humerus	4	13	4.9
Radius	4	9.5	5
Ulna	4	12	4.5
Metacarpus (average)	4	1.3	0.9

DISCUSSION

It is stated that ossification of the scapula in mammals is provided by one POC and two SOC, while in humans, the scapula ossifies from 8 secondary ossification centers (Barone, 1986). According to Getty (1975), the scapula ossifies from four centers in equidae and three centers in ruminantia. Patton and Kaufman (1995) reported that the scapula ossifies from one primary center and one secondary center in mice. Hare (1961) and Chapman (1965) reported that the scapula in dogs has a total of two ossification centers located in the collum scapula and tuber scapula. In our study, a single center was observed in the corpus in 40-day-old fetuses, and these data are generally consistent with our study. It has been reported that the SOC of the radius in dogs begins to ossify on postnatal days 10-25 (Chapman, 1965; Hare, 1961). No SOC was observed in 40-day-old fetuses, and our data are suitable for this study.

It has been stated that the ulna has three ossification centers in mammals, one of which is in the corpus, the other two are in the olecranon and the proc. styloideus (Doğuer & Erençin, 1962). The existence of one POC and two SOC has been reported in the literature (Barone, 1986; Chapman, 1965; Getty, 1975; Hare, 1961; Olgun, 1978). It is said that these two secondary ossification centers begin to ossify on the 40th-45th day in dogs (Chapman, 1965; Hare, 1961) and on the 48th-54th day in the Angora cat (Olgun, 1978). It was determined that the SOC of the ulnas of the 5-6 month-old materials fused with the corpus at both ends. In the 7-month-old material, it was determined that the epiphyseal plates were closed. These bones are found as two separate bones in adult dogs (Chapman, 1965; Hare, 1961). In our study, the fact that the ossification centers of the two bones were not at the same level can be considered as a precaution taken to ensure the strength of the antebrachium. No secondary ossification centers were seen in the 40-day-old fetuses in our study and no evaluation could be made for these dates. Lopez et al (1993) stated that the ossa carpi in Siamese cats was not ossified in newborns. It was reported that the ossa carpi began to ossify between postnatal days 18-45 in dogs (Chapman, 1965; Hare, 1961).

No secondary ossification centers were seen in the 40-day-old fetuses in our study.

It was observed that primary centers were formed in the scapula and humerus, but secondary centers were not formed. It was observed that the primary ossification center was formed in the radius and ulna, and this primary center was longer in the radius. However, it was determined that the secondary ossification center had not yet formed in both bones. In each of the ossa metacarpale II, III, IV bones, a primary ossification center was observed, while those in ossa metacarpale III and IV were larger. It was observed that the cartilaginous bone primitive was formed in all carpal bones, but the primary or secondary center had not yet formed. It was observed that the cartilaginous bone primitive was formed in the phalanges, but the primary or secondary center had not yet formed.

CONCLUSION

In this study, the formation status and sizes of the POC seen in the bone development of the forelimb of a 40-day-old watchdog hybrid fetus were determined. The ossification centers in the watchdog hybrid fetuses mostly matched the studies conducted on domestic animals. In conclusion, it should be noted that there are various factors that affect ossification, such as nutritional habits, hormones, environmental factors, and individual differences.

Acknowledgement

The authors would like to extend their sincere thanks to anyone who contributed to this study.

Conflict of Interest

The author declares no potential conflicts of interest with respect to the research, authorship and/or publication of this article.

Author Contributions

Plan, design: ŞHA, MK, SY; **Material, methods and data collection:** ŞHA, MK, SY; **Data analysis and comments:** ŞHA, MK; **Writing and corrections:** ŞHA, MK, SY.

Funding

None.

Ethical Approval

Since the study was conducted on dead material, ethics committee approval is not required

REFERENCES

Atalgın, H., Kürtül, I., & Bozkurt, E. U. (2007). Postnatal osteological development of hyoid bone in the New Zealand White Rabbit. *Veterinary Research Communications*, 31, 653-660. <https://doi.org/10.1007/s11259-007-3475-9>.

- Atalgın, Ş. H., & Çakır, A. (2006). Yeni Zelanda Tavşanında Os Coxae ve Femur'un Postnatal Osteolojik Gelişimi. Ankara Üniversitesi. *Ankara Üniversitesi Veteriner Fakültesi Dergisi*, 53, 155-159. https://doi.org/10.1501/Vetfak_0000000093
- Atalgın, Ş. H., & Kürtül, I. (2009). A morphological study of skeletal development in Turkey during the prehatching stage. *Anatomia, Histologia, Embryologia*, 38, 23-30. <https://doi.org/10.1111/j.1439-264.2008.00887.x>
- Ateş, S., Atalgın, Ş. H., Kürtül, İ., & Takçı, L. (2017). 80 günlük yaban domuzu fütüslerinde ön ve arka ekstremiteelerin kemikleşme ve gelişimleri. *Balikesir Sağlık Bilimleri Dergisi*, 6(2), 64-69. <https://doi.org/10.5505/bsbd.2017.48802>
- Barone, R. (1986). Anatomie comparée des mammifères domestiques: Ostéologie. Paris: Vigot Frères, 461-521.
- Chapman, W. L. (1965). Appearance of ossification centers and epiphysial closures as determined by radiographic techniques. *Journal of the American Veterinary Medical Association*, 147, 138-141.
- Doguer, S., & Erencin, Z. (1962). *Evcil hayvanların komparativ osteolojisi* (pp. 251-282). Ankara: Ankara Üniversitesi Basımevi.
- Dyce, K. M., Sack, W. O., & Wensing, C. J. G. (1987). *Textbook of veterinary anatomy* (pp. 67-76). London: W.B. Saunders Company.
- Evans, H. E., & Sack, W. O. (1973). Prenatal development of domestic and laboratory mammals: growth curves, external features and selected references. 2: 11-45.
- Getty, R. (1975). *The Anatomy of The Domestic Animals* (pp. 271-296). London: W.B. Saunders Company.
- Govindarajan, V., & Overbeek, P. A. (n.d.). (2006). FGF9 can induce endochondral ossification in cranial mesenchyme. *BMC*. <https://doi.org/10.1186/1471-213X-6-7>
- Hare, W. C. D. (1961). The ages at which the centers of ossification appear roentgenographically in the limb bones of the dog. *American Journal of Veterinary Research*, 90, 825-835.
- Olgun, M. (1978). Ankara keçisi iskelet kemiklerinde postnatal kemiklerin anatomik yönden araştırılması (Doctoral dissertation). Ankara Üniversitesi Sağlık Bilimleri Enstitüsü.
- Patton, J. T., & Kaufman, M. H. (1995). The timing of ossification of the limb bones, and growth rates of various long bones of the fore and hind limbs of the prenatal and early postnatal laboratory mouse. *Journal of Anatomy*, 186, 175-185.
- Paul, C., & Hodges, J. R. (1953). Ossification in the fetal pig: A radiographic study. *Anatomical Record*, 116, 315-325. <https://doi.org/10.1002/ar.1091160308>
- Williams, P. L., & Dyson, M. (1989). *Gray's anatomy* (pp. 279-322). London: The Both Press.
- Zhang X, Siclari VA, Lan S, Zhu J, Koyama E, Dupuis HL, Iwamoto ME, Beier F, Qin L. (2011). The Critical Role of the Epidermal Growth Factor Receptor in Endochondral Ossification. *Journal of Bone and Mineral Research*. 26 (11): 2622-2633. <https://doi.org/10.1002/jbmr.502>