

Original Research Article

Maxillary Labial Frenum Types in Children and Effects on the Oral Cavity: A Cross-Sectional Study

Çocuklarda Maksiller Labial Frenum Tipleri ve Ağız Boşluğu Üzerindeki Etkileri: Kesitsel Bir Çalışma

Taibe Tokgöz Kaplan¹ , Mihriban Gökcek Taraç² 

ABSTRACT

Aim: This study evaluated the maxillary labial frenum (MLF) types and their effects on children's diastema, caries, and gingival health.

Material and Method: The study included 500 children (50.2% girls, 49.8% boys) aged 3-14. MLF types were classified according to the Mirko classification, and the gingival index score was performed according to the Löe-Silness classification. Dentition periods, the presence of anterior caries, and diastema widths were saved. Data were analyzed by Chi-square test, and Kruskal-Wallis-H test in SPSS software.

Results: There was no statistically significant difference between the genders regarding MLF types. The most common frenum type was gingival type frenum (48%), followed by papillary type (30%) and papillary penetrating type (16%). The gingival frenum type was significantly higher in the older age group. Among the 291 patients with diastema, the papillary penetrating type was significantly higher in those with 2-4 mm diastema. A significant correlation was found between frenum type and caries between the anterior teeth.

Conclusion: Frenums can cause gingival recession, midline diastema, dental caries, and gingival disease.

Keywords: Gingival health; Frenum attachment; Maxillary anterior caries; Maxillary labial frenum; Midline diastema

ÖZ

Amaç: Frenulum, dudak ve yanağı alveolar prosese bağlayan; boyut, şekil ve yapışma açısından değişiklik gösterebilen bir mukoza kalıntısıdır. Maksiller labial frenulum (MLF) ağız boşluğunda birçok dental veya gingival malformasyonla ilişkilidir. Bu çalışmanın amacı, çocuklarda labial frenulum tiplerini ve diastema, çürük ve dişeti sağlığına etkilerini değerlendirmektir.

Gereç ve Yöntem: Çalışmaya 3-14 yaş arası 500 çocuk (%50.2 kız, %49.8 erkek) atılmıştır. MLF tipleri Mirko sınıflamasına göre sınıflandırılmış; gingival indeks skoru Löe-Silness sınıflamasına göre yapılmıştır. Dişlenme dönemleri, anterior dişler arasında çürük varlığı ve diastema genişlikleri kaydedilmiştir. Veriler SPSS yazılımında Ki-kare testi ve Kruskal-Wallis-H testi ile analiz edilmiştir.

Bulgular: MLF tipleri açısından cinsiyetler arasında istatistiksel olarak anlamlı bir fark bulunmamıştır. En yaygın frenulum tipi gingival tip frenulum (%48) olurken, bunu papiller tip (%30) ve papiller penetran tip (%16) takip etmiştir. Gingival frenum tipi ileri yaş grubunda anlamlı olarak daha yüksekti. Diasteması olan 291 hastada, papiller penetran tip, 2-4 mm diasteması olanlarda anlamlı olarak daha yüksekti. Frenulum tipi ile ön dişler arasında çürük varlığı arasında anlamlı korelasyon bulundu.

Sonuç: Frenulumlar dişeti çekilmesi, orta hat diasteması, diş çürükleri ve dişeti hastalıklarına neden olabilir.

Anahtar Kelimeler: Gingival sağlık; Frenulum bağlantısı; Maksiller anterior çürük; Maksiller labial frenulum; Orta hat diasteması

Makale gönderiliş tarihi: 27.08.2024; Yayına kabul tarihi: 25.12.2024

İletişim: Dr. Taibe Tokgöz Kaplan

Department of Pediatric Dentistry, Faculty of Dentistry, Karabük University

E-mail: ttokgoz71@gmail.com

¹ Asst. Prof., Karabük University, Department of Pediatric Dentistry, Faculty of Dentistry, Karabük, Turkey

² Asst. Prof., Karabük University, Department of Pediatric Dentistry, Faculty of Dentistry, Karabük, Turkey

INTRODUCTION

The frenum is a mucosal membrane remnant, usually triangular, connecting the lip and cheek to the alveolar process. It is seen in the mandibular and maxillary vestibular mucosa in the midline and premolar region.^{1,2} The maxillary frenum histologically contains elastic fibers, collagen tissue components, striated muscle fibrils, blood vessels, nerves, and minor salivary glands.^{3,4} The frenum is a dynamic and variable structure that can vary in size, shape, and attachment position at different stages of growth and development.^{5,6} The frenum attachment point, which is smaller, thicker, and more cervical in infants, moves apically with the eruption of the deciduous incisors, the development of the maxillary sinus, and the increase in the alveolar vertical dimension.³

Sewerin described eight types of frenum according to their morphological characteristics: simple frenum, simple appendicular frenum, nictum labial frenum, nodule frenum, nodule labial frenum, bifid labial frenum, persistent tectolabial frenum, and double frenum.⁷ In the classification by Mirko *et al.*⁸ the frenum is divided into four types according to its anatomical position: mucosal, gingival, papillary, and papillary penetrating. Many clinicians have accepted Mirko's classification and is still in use.^{5,8} The frenum is at the mucogingival margins in the mucosal type, at the attached gingival margin in the gingival type, at the gingival papilla margin in the papillary type, and within the gingival papilla in the papillary penetration type.^{8,9}

Maxillary labial frenum (MLF) is associated with many dental or gingival malformations, especially in children, as it has different types, thickness and morphology in the oral cavity.^{5,10,11} Abnormal positioning of the MLF may cause midline diastemas between the central incisors, making orthodontic treatment difficult and/or causing relapses after orthodontic treatment.^{9,12,13} In babies, the labial frenum may negatively affect sucking and feeding.^{14,15} Kotlow *et al.*^{14,16} reported that the labial frenum damaging the gingival margin may prevent the patient from brushing their teeth and cause dental plaque accumulation, deterioration of oral hygiene, and caries formation. Additionally, when the junction of the labial frenum is towards the gingival margin, it may cause the marginal gingival papilla to stretch

and gingival recession. As a result, it may contribute to the formation and progression of periodontal diseases, especially in adults,^{8,17} and may adversely affect the fit and retention of dental prostheses.⁵

Some of the effects of MLF in the oral cavity have been evaluated in the literature, but no study evaluating all possible effects together has been reported. In this study, all of the conditions that may occur in the mouth according to the type of MLF are presented together. This study aimed to evaluate the MLF types in children aged 3-14 years in the period of primary, mixed, and permanent dentition and its surroundings and to determine its relationship with the midline diastema between frenum and anterior teeth, the presence of caries and periodontal health status. The study hypothesis was that there is a positive relationship between labial frenum and the presence of diastema and caries, and a negative relationship with gingival health in children.

MATERIAL AND METHOD

This is a cross-sectional epidemiological study conducted at Karabuk University Faculty of Dentistry. It was conducted under the principles of the Declaration of Helsinki. The Ethics Committee of Karabuk University Human Research granted approval (Approved by decision number 2023/1254, decision date 27.02.2023). In addition, "informed consent" was obtained from the legal representatives of all children participating in the study.

The study included 500 systemically healthy children between the ages of 3 and 14 who were admitted to the Karabuk University, Department of Pediatric Dentistry. Exclusion criteria were children with orofacial anomalies, trauma to the frenum region, history of surgical intervention in the maxillary labial region, and medication (antiepileptic, calcium channel blocker, immunosuppressive drug) known to cause gingival enlargement. In addition, the study did not include children with incomplete eruption of both deciduous/permanent central incisors.

An 11 years experienced pediatric dentist performed the intraoral examination of the patients under reflector light. The examiner evaluated the MLF types, gingival health of the teeth in the relevant region, caries on the mesial surfaces of the anterior region teeth, and the width of the midline diastema, if any.

MLF types were recorded according to the classification of Mirko *et al.*⁸ Frenum attachment point was always examined with the lip gently stretched away from the alveolar process in the almost horizontal direction. In this classification, four types of frenal attachment are defined with detailed criteria as follows (Figure 1):

- Mucosal (Figure 1a): Frenal fibers are attached over the mucogingival junction
- Gingival (Figure 1b): Frenal fibers are attached to the gingival barrier
- Papillary (Figure 1c): Frenal fibers are expanded to interdental papilla
- Papillary penetrating (Figure 1d): Frenal fibers cross the alveolar process and extend to papilla palatin

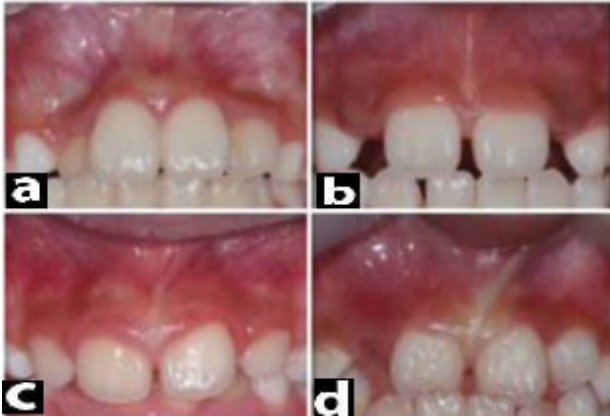

Figure 1. Frenum types

Gingival health was scored according to the gingival index defined by Löe and Silness,¹ and the highest gingival score in the relevant region was recorded. The score was recorded as 0 if there was no inflammation, discoloration, and bleeding; 1 if there were mild surface changes, mild inflammation, and discoloration but no bleeding; 2 if there was moderate inflammation, redness, edema, pressure, and bleeding by probing; 3 if there were severe inflammatory changes, severe redness and edema, spontaneous bleeding tendency and ulceration. Frenum class and the highest gingival score of the region were recorded.

Caries between the anterior region teeth were recorded as present/absent. To determine the width of the midline diastema, the diastema value was recorded by measuring the widest part of the diastema with a digital caliper on the plaster model prepared by taking measurements. The patient's age, dentition

period, gender, and sibling relationship were evaluated. The frenum examinations of children who came to the clinic with their siblings were evaluated and recorded based on their siblings' MLF types.

Data analysis

Statistical analyses were performed using SPSS (v. 22.0) software. Fisher's exact test was used to evaluate the relationship between frenum types and dentition types. The relationship between frenum types and age, gender, and the presence of caries and the relationship between gingival index scores and dentition types and frenum types were evaluated with the Chi-squared test. In addition, the Kruskal-Wallis-H test was used to evaluate the relationship between frenum types and diastema values since the data were not normally distributed. Additionally, the compatibility between siblings' frenum types was evaluated using a Kappa analysis.

RESULTS

A total of 500 children (50.2% girls, 49.8% boys) aged 3-14 years were included in the study. The results were presented in 3 groups: a group of participants aged 3-5 years, a group of participants aged 6-9 years, and a group of participants aged 10-14 years. 1.8% of the participants were 3 years old, 9.2% were 4 years old, 16.8% were 5 years old, 18.2% were 6 years old, 13.4% were 7 years old, 12.6% were 8 years old, 9.4% were 9 years old, 6.4% were 10 years old, 7% were 11 years old, 4% were 12 years old, 2.4% were 13 years old, and 0.8% were 14 years old. Among the participants, 159 (31.8%) were in primary dentition, 282 (56.4%) were in mixed dentition, and 59 (11.8%) were in permanent dentition. The most common frenum type in all dentition periods was gingival type frenum (48%), followed by papillary type (30%) and papillary penetrating type (16%). The least common frenum type in all dentition periods is the mucosal type (6%) (Figure 2). However, the most common period in which gingival type frenum was statistically significant was found to be the mixed dentition ($p=0.01-0.05$). In addition, the relationship between frenum types and age group was found to be statistically significant ($p=0.01-0.05$); gingival type frenum was most common in the 10-14 age group, and the other three frenum types were seen in the 6-9 age group.

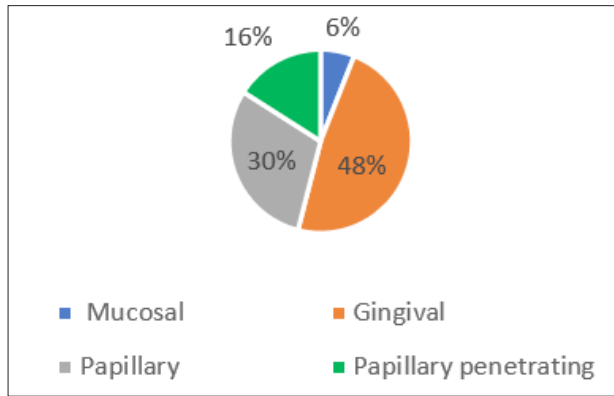


Figure 2. Percentage of different types of frenal attachment

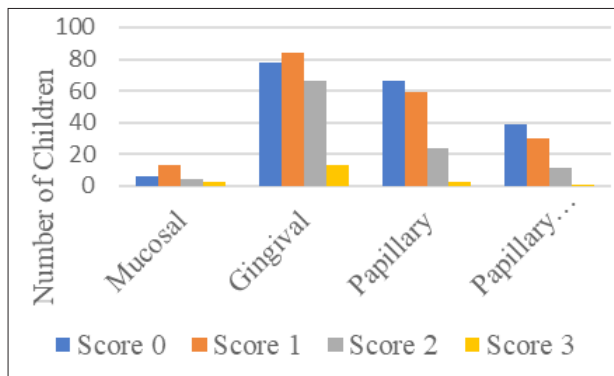


Figure 3. Gingival index scores related to frenum types

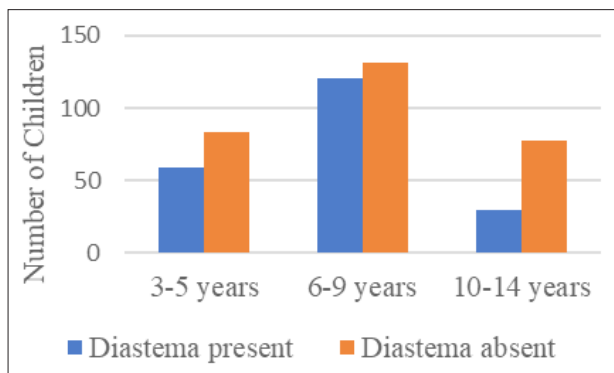


Figure 4. Age distribution of patients with and without diastema

The distribution of frenum types according to gender was not statistically significant ($p = 0.4$). The gingival index score was statistically significantly higher in mixed dentition ($p = 0.00$). Scores 0, 1, and 2 were most frequently seen in mixed dentition. Score 3 was seen least frequently in all dentition types. In addition, the gingival index score was significantly higher in gingival type frenum ($p = 0.02$). Scores 0, 1, and 2 were most frequently in the gingival frenum type. Score 3 was the least frequent of all frenum types (Figure 3).

291 participants (50.2% boys and 49.8% girls) did not have diastema. The age distribution of patients without diastema is given in Figure 4. No significant association was found between frenum types in patients without diastema. ($p = 0.16$). While gingival type frenum was the most common in 62.9%, papillary, mucosal, and papillary penetrating type frenum were seen, respectively (Figure 5).

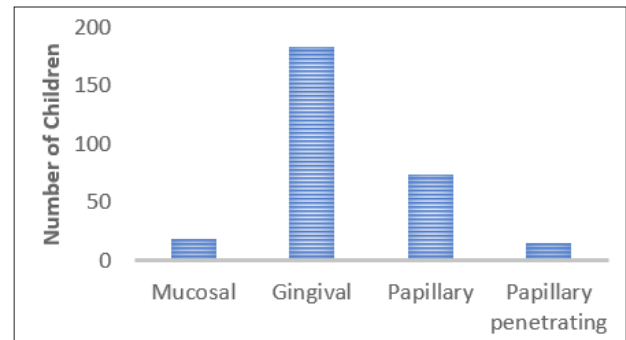


Figure 5. Type of frenum in the group without diastema

The presence of midline diastema was detected in 209 of the participants (50.7% girls and 49.2% boys). The age distribution of patients with midline diastema is given in Figure 4. When the age distribution of patients with diastema was evaluated, it was found that diastema was most commonly seen in the 6-9 age range. The distribution of midline diastema width ranges of patients with diastema for both sexes was as follows: 43.1% of patients (46% boys and 54% girls) had diastema widths between 0 and 1 mm. In 34.4% of the patients (54% boys, 46% girls), diastema widths between 1 mm and 2 mm were included. Diastema width between 2 mm and 3 mm was observed in 17.7% of the patients (48% boys, 52% girls). Diastema width of 3 to 4 mm inclusive was observed in 4.8% of the patients (28% boys, 72% girls). Due to the small group of patients with diastema width of 0-1 mm and 3-4 mm, the measured widths of diastema have been divided into the following two groups for statistical analysis: I — width of diastema 0-2 mm (small diastema); II — width of diastema 2-4 mm (large diastema). The mean midline diastema width of all participants was 0.62 ± 0.8 . A statistically significant association was observed between frenum type and midline diastema width ($p < 0.005$). Mucosal, gingival, and papillary frenum types were more common in patients with 0-2 mm diastema, while papillary penetrating frenum type was statistically significantly more common in patients with 2-4 mm diastema. Mucosal frenum was

observed in 5.1% of those with diastema, gingival frenum in 47.8%, papillary frenum in 29.5%, and papillary penetrating frenum in 17.6% (Figure 6). There was no statistically significant association between the presence of maxillary anterior caries and frenum type ($p = 0.058$). The most common frenum type was the gingival type in both caries and non-caries patients. It was observed that the MLF types of 31 children who came to the clinics with siblings were not statistically compatible according to the Kappa agreement test ($K: 0.29$). In addition, it was concluded that the diastema values were not similar by the Spearman Correlation test ($p=0.88$).

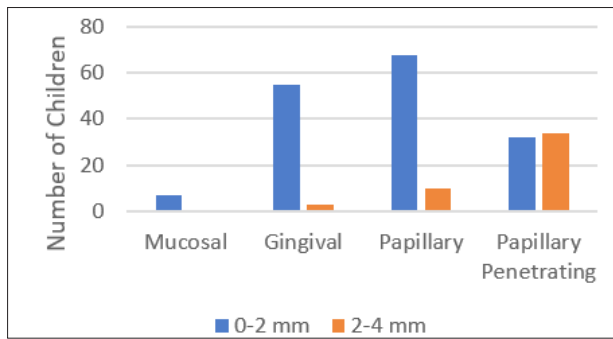


Figure 6. Type of frenum in different sizes of diastema

DISCUSSION

The MLF is a dynamic and frequently changing complex structure subjected to changes in shape, size, and position at different stages of growth and development. Since these changes in the frenum affect other oral structures, the child's health, aesthetics, oral hygiene habits, and social life can also be affected. Therefore, this study aimed to determine the MLF types of pediatric patients aged 3-14 years living in Karabük province and to evaluate the relationship between labial frenum type and gingival health, dental caries, and diastema. The study included children with deciduous and mixed dentition between the ages of 3 years, when deciduous teeth are complete, and 14 years, when permanent teeth are complete (excluding wisdom teeth).

No case without labial frenum was found in the 500 patients whose MLFs were analyzed in this study. Cases without MLF are usually seen in patients with craniofacial defects.¹⁸ In the deciduous and permanent dentition, the most common type of frenum was the gingival frenum. Similar findings were found in

many studies.^{6,9,19} On the other hand, there are also studies in which the mucosal frenum type is the highest.^{8,20,21} Findings may vary according to the number of participants, age distribution.

In the literature, many studies have reported no significant association between frenum type and gender.^{9,22} Divater *et al.*²³ reported no significant relationship between gender and frenum, but there was a significant difference according to age. Children with gingival type frenum were found to be the oldest, and children with papillary-type frenum were found to be the youngest among all groups. Similarly, in the present study, in agreement with the literature, no statistically significant correlation was found between MLF type and gender, whereas a statistically significant correlation was found between MLF type and age. Gingival type frenum was statistically significantly higher in the 10-14 age group, the oldest group among the participants. The other three types of frenum were seen in the 6-9 age group. In a study conducted on a Turkish population aged 2-65, no significant difference was found between gender and MLF, whereas a significant difference was found in age groups. Gingival and mucosal types of frenum were seen in the 2-6 age group, and gingival type frenum was seen in all participants aged 7 years and older.³ Boutsis *et al.*⁹ in a study performed on 226 children aged 1-18 years, a significant correlation was found between MLF type and age, and it was reported that children with mucosal type frenum were the oldest and children with papillary penetrating type frenum were the youngest. However, many studies have not reported a statistical correlation between MLF types and age.^{8,18,20} Díaz-Pizán *et al.*²⁴ reported that in a large cohort of 1355 children in the deciduous dentition, the frenum attachment can move from a more coronal to a more apical position. However, a movement in the opposite direction was never detected. In conclusion, it is possible that the frenal attachment migrates apically with age, with or without a statistically significant difference. The frenum's apical migration depends on the alveolar process's coronal growth. This is also supported by the findings of this study.

Frenum may cause mucogingival problems.^{5,8} In cases where the frenum attachments extend to the free gingiva, lip-cheek movements will be restricted, plaque and calculus accumulation will increase and

will lead to gingival recession and periodontal pocket formation over time.⁵ In a study examining the effects of frenum level on oral structures, it was reported that the mandibular labial frenum was ineffective in plaque and gingivitis formation, while the maxillary frenal connection affected plaque retention and the degree of gingivitis.²⁵ Divater *et al.*²³ reported that oral hygiene status was worse in patients with papillary penetrating type frenum. Since lip movements will be limited in individuals with papillary penetrating frenum, gingival index scores are expected to be higher. In this study, the gingival index score was found to be lowest in mucosal type frenum and significantly higher in gingival type frenum ($p=0.02$). This may be due to the fact that 48% of the participants had gingival frenum. The findings are consistent with those of Taran *et al.*¹⁹ who studied Turkish children. In addition, in the present study, the gingival index score was statistically significantly higher in the mixed dentition type ($p<0.001$). Although frenum type is an important predisposing factor, oral hygiene skills of the child are more effective on gingival index. Today, oral hygiene habits in children cannot be fully established due to the increase in pathogenic microflora in the mouth due to the increase in refined sugar and ready-to-eat food consumption, the busy work schedule of parents and the lack of tooth brushing support that makes children responsible at an early age. Therefore, caries risk and gingival index scores increase.

In many publications, the impact of oversized upper lip frenum on diastema formation was described. Regarding attachment type, papillary (27.6 to 62.5%) and penetrating papillary penetrating (47.1 to 100%) attachments were associated with the occurrence of diastemas.^{13,26,27} Rathod *et al.*²² found that this attachment type was more prevalent in women and that the occurrence of diastemas was more common in this group. Placek reported that in the group of people without diastema, only 2% of the papillary type frenum and no papillary penetrating type were observed.⁸ On the other hand, there are studies that reported no specific relationship between diastema and frenum type, and there are also studies finding a significant association between gingival type frenum and mucosal type frenum and diastema.²² In the study of Chaulagain *et al.*²¹ in 102 patients in whom the relationship between frenum

and diastema was investigated, 98% of those with diastema had mucosal type frenum; in the study of Kılınç *et al.*¹⁸, gingival type frenum was detected in 55.2% of 1023 patients with a diastema between the ages 2 and 65. Sekowska *et al.*¹³ reported predominantly mucosal (34.6%) and gingival type (30.8%) frenum types in the small diastema (≤ 2 mm) group. Additionally, no mucosal type was observed in the large diastema (> 2 mm) group, and papillary type (34.6%) and papilla-penetrating type frenum were predominant. The findings in the presented study support the literature; it was found that frenum type was effective on diastema width. In this study, mucosal and papillary type frenum along with gingival type (62.9%) were observed predominantly in the patient group with small diastema (≤ 2 mm). In comparison, papillary and papillary-penetrating frenum (78.8%) was observed in the large diastema (> 2 mm) group. Mucosal frenum was not seen in those with large diastema.

When the age distribution of patients with diastema was evaluated, it was found that diastema was most commonly seen in the 6-9 age range. This age range is the mixed dentition period and is the beginning of the period when both deciduous and permanent teeth are in the mouth simultaneously. In the mixed dentition period, it is normal to see a "midline diastema" approximately 1-3 mm wide between the permanent upper central incisors. Because the permanent canines compress the roots of the permanent upper incisors in the mesial direction, the crowns of these teeth are slightly inclined distally. As a result, midline diastema occurs. In 1975, Broadbent called this situation the "ugly duckling stage" and explained this stage as a transitional stage in dental development.²⁸ It has been reported that midline diastema will close after the canine teeth emerge.²⁸ In the presented study, diastema was most frequently seen in the 6-9 age group; diastema width can be checked by following patients until their canine teeth erupted. Díaz-Pizan *et al.*²⁴ suggested that frenal types change with age and craniofacial growth. Therefore, the decision to perform early frenal interventions in children should be postponed until the eruption of permanent teeth. In children, interincisal diastemas are wider and tend to decrease with age.^{26,24,27} In many individuals, the closure of diastemas occurs between 14 and 19 years of age.^{11,24} So, considering

the child's age, the need for frenectomy will be eliminated with the movement of the frenum attachment apically over time.

Limited publications are investigating the relationship between the type of MLF and caries.^{14,18} It is stated that babies with labial frenum-type papillary and papillary penetration will have milk accumulation between their teeth after breastfeeding due to the structure of the frenum. This will increase the risk of caries. Additionally, it is said that in children with papillary frenum or with papillary penetration frenum, the thick fibrous structure of the frenum may restrict the normal function and mobility of the upper lip and cause early dental caries.^{14,16} On the other hand, there is a study reporting that there is no relationship between the degree of MLF attachment and restriction in lip movements and difficulty in breastfeeding.²⁹ In a previous study, dental caries were detected between the maxillary incisors of children with primary and permanent teeth. The existing decayed teeth and the type and morphology of the MLF were examined, and although a higher rate of caries was detected in deciduous teeth than in permanent teeth, no statistically significant result was found between frenum type and dental caries.¹⁸ In the present study, the most common frenum type in patients with or without caries between anterior teeth was a gingival type. However, no statistically significant relationship was found between the presence of maxillary anterior caries and frenum type. In addition, the association between siblings with MLF was evaluated in this study. In the literature, studies on siblings with midline diastema have generally focused on the prevalence and etiology of maxillary midline diastema in siblings.³⁰ It has been reported that 78% of patients with a diastema between the maxillary anterior teeth had at least one family member (mother, father, or sibling) with diastema.³⁰ In this study, when the relationship between siblings and MLF was evaluated with Kappa statistics, no significant relationship was found between frenums and diastemas in 31 siblings presenting to the clinic. Similarly, Kılınç *et al.*¹⁸ did not find a significant correlation in their study.

A major limitation of this study is that our sample consisted of a small number of children from a geographically limited area and they may not be representative of the entire population. For a better evaluation, a larger sample and data obtained from

wider geographies are required. A multicenter study conducted in different regions makes it possible to determine the malocclusion status, treatment needs, and periodontal health map by determining the potential effects on the frenum and the related oral cavity. Additionally, longitudinal studies should be conducted to assess changes over time and potential causal relationships, and potential clinical implications should be explored in detail through further research.

CONCLUSION

Frenums are associated with various issues such as oral hygiene, midline diastemas, gingival health, and the need for orthodontic treatment and may cause pathologies. Therefore, every dentist should carefully examine the frenum during intraoral examination, especially in pediatric patients. The clinician should follow the patient for a long time to prevent unnecessary surgical intervention, taking into account that the attachment of the frenum of the examined child may shift to a more apical position with increasing age, and the morphology of the frenum may change with age.

REFERENCES

1. Løe H., Silness J. Periodontal disease in pregnancy I. Prevalence and severity. *Acta Odontol Scand* 1963;21:533-51.
2. Minsk L. The frenectomy is an adjunct to periodontal treatment. *Compend Contin Educ Dent* 2002;23:424-8.
3. Kılınç G, Çetin M, Köse ZB, Ertunç Ü, Ateşçi AA. Evaluation of median maxillary labial frenum type and morphology in different age groups. *J Basic Clin Health Sci* 2021;5:30-5.
4. Olivi M, Genovese MD, Olivi G. Laser labial frenectomy: a simplified and predictable technique. Retrospective clinical study. *Eur J Paediatr Dent* 2018;19:56-60.
5. Delli K, Livas C, Sculean A, Katsaros C, Bornstein MM. Facts and myths regarding the maxillary midline frenum and its treatment: a systematic literature review. *Berlin: Quintessence Int* 2013;44-50
6. Biradar SM, Patil AY, Kotnoor SS, Bacha S, Bijjaragi SC, Kattimani PT. Assessment of Diverse Frenal Morphology in Primary, Mixed, and Permanent Dentition: A Prevalence Study. *J Contemp Dent Pract* 2020;21:562-7.
7. Sewerin IB. Prevalence of variations and anomalies of the upper labial frenum. *Acta Odontol Scand* 1971;29:487-96.
8. Mirko P, Miroslav S, Lubor M. Significance of the labial frenum attachment in periodontal disease in man. Part 1. Classification and epidemiology of the labial frenum attachment. *J Periodontol*

1974;45:891-4.

9. Boutsis EA, Tatakis DN. Maxillary labial frenum attachment in children. *Int J Paediatr Dent* 2011;21:284-8.

10. Lioliou E, Kostas A, Zouloumis L. The maxillary labial fraenum: A controversy of oral surgeons vs. orthodontists. *Balkan Journal of Stomatology* 2012;16:141-6.

11. Santos A, Silva LM, Lima I, Oliveira LML de, Vajgel B de CF, Cimões R. Morphological variations of the labial frenum, type of attachment and presence of diastemas: integrative review. *RGO-Revista Gaúcha de Odontologia* 2023;71:1-10

12. Kotlow LA. Oral diagnosis of abnormal frenum attachments in neonates and infants: evaluation and treatment of the maxillary and lingual frenum using the Erbium: YAG laser. *J Pediatr Dent Care* 2004;10:11-4.

13. Sękowska A, Chalas R. Diastema size and upper lip midline frenulum attachment type. *Folia Morphol* 2017;76:501-5.

14. Kotlow LA. The influence of the maxillary frenum on the development and pattern of dental caries on anterior teeth in breastfeeding infants: prevention, diagnosis, and treatment. *Journal of Human Lactation* 2010;26:304-8.

15. Razdan R, Callahan S, Saggio R, Chafin M, Carr MM. Maxillary frenulum in newborns: association with breastfeeding. *Otolaryngology-Head and Neck Surgery* 2020;162:954-8.

16. Kotlow LA. Diagnosing and understanding the maxillary lip-tie (superior labial, the maxillary labial frenum) as it relates to breastfeeding. *J Human Lactation* 2013;29:458-64.

17. Madi M, Alamri A, Aleisa D, Almusallam MO, AlQahtani SS, Al-Aql ZS, *et al.* Associations between maxillary labial frenum Morphology, Attachment, and Patient-Related clinical factors in Saudi Arabian Adults: Cross-sectional study. *Saudi Dent J* 2024;36:615-20.

18. Kiliç G, Bulut G, Ertuğrul F, Ersin N, Ellidok H. Çocuklarda Üst Çene Labial Frenulumun Klinik ve Diş Çürüğü Açısından Değerlendirilmesi. *Türkiye Klinikleri J Dental Sci* 2014;20:36-40.

19. Taran PK, Özdemir Ş, Akarca B, Yüksel H. Evaluation of the Relationship Between Maxillary Labial Frenulum Attachment Types, Periodontal Health, and Dental Caries in Preschool Children. *Bezmialem Sci* 2023;11:73-8.

20. Jindal V, Kaur R, Goel A, Mahajan A, Mahajan N, Mahajan A. Variations in the frenal morphology in the diverse population: A clinical study. *J Indian Soc Periodontol* 2016;20:320-3.

21. Chaulagain R, Khanal N, Singh AK. Morphology of maxillary labial frenum in Chepang community of Chitwan. *J Nepal Health Res Counc* 2021;19:185-8

22. Rathod S, Bawankar P V, Chikhale P, Bidwaikar A. Evaluation of variations in morphology and attachment of frenum in a diverse population-A cross-sectional study. *Clin Epidemiol Glob Health* 2020;8:1094-7.

23. Divater V, Bali P, Nawab A, Hiremath N, Jain J, Kalaivanan D. Frenal attachment and its association with oral hygiene status among adolescents in Dakshina Kannada population: A cross-sectional study. *J Family Med Prim Care* 2019;8:3664-7.

24. Díaz-Pizán ME, Lagravère MO, Villena R. Midline diastema and frenum morphology in the primary dentition. *J Dent Child* 2006;73:11-4.

25. Addy M, Dummer PMH, Hunter ML, Kingdon A, Shaw WC. A study of fraenal attachment, lip coverage, and vestibular depth association with plaque and gingivitis. *J Periodontol* 1987;58:752-7.

26. Jonathan PT, Thakur H, Galhotra A, Galhotra V, Gupta N. Maxillary labial frenum morphology and midline diastema among 3 to 12-year-old schoolgoing children in Sri Ganganagar city: A cross-sectional study. *J Indian Soc of Pedodon and Prev Dent* 2018;36:234-9.

27. Patel J, Parikh H, Duseja S, Agrawal C, Dholakia P, Pathak V. Variations in the attachment and morphology of maxillary labial frenum in a diverse population of Gujarat: an observational study. *J Res Adv Dent* 2021;11:336-41.

28. Broadbent** BH. The face of the normal child. *Angle Orthod* 1937;7:183-208.

29. Kinney R, Burris RC, Moffat R, Almpani K. Assessment and Management of Maxillary Labial Frenum-A Scoping Review. *Diagnostics (Basel)* 2024;14:1710.

30. Luqman M, Sadatullah S, Saleem MY, Ajmal M, Kariri Y, Jhair M. The prevalence and etiology of maxillary midline diastema in a Saudi population in the Aseer region of Saudi Arabia. *Int J of Clinic Dent Science* 2014;1:86-90