

Evaluation of Anatomical and Morphological Characteristics of the Infraorbital Foramen

Foramen Infraorbitale'nin Anatomik ve Morfolojik Özelliklerinin Değerlendirilmesi

Menekşe CENGİZ¹, Mehmet KARAGULLE², Ege ALKAN³, Hanife ERTURK⁴, Lütfiye Bikem SUZEN⁵

¹ Antalya Bilim University, Vocational School of Health Services, Physiotherapy, Antalya, 0000-0003-2549-7941

² Antalya Bilim University, Vocational School of Health Services, Physiotherapy, Antalya, 0000-0001-7463-3562

³ Akdeniz University, Faculty of Medicine, Department of Anatomy, Antalya, 0000-0002-7805-5808

⁴ Antalya Bilim University, Vocational School of Health Services, Physiotherapy, Antalya, 0000-0003-3892-1035

⁵ Antalya Bilim University, Faculty of Dentistry, Department of Anatomy, Antalya, 0000-0003-2293-9388

ÖZET

Amaç: Foramen infraorbitale, a., v. ve n. infraorbitale'nin geçtiği kanalın açıldığı deliktir. Çalışmamızda infraorbital forameni anatomik ve morfometrik olarak incelemeyi amaçladık.

Materyal ve Yöntemler: Çalışmamızda 111 kuru kafatası ve 144 yarım kafatası kemiği kullanıldı. Foramen infraorbitale'nin insidansı ve tiplendirmesi araştırıldı. Foramen infraorbitale'nin incisura nasalis'e, margo infraorbitale'ye, ve juga alveolaria'ya ve sutura zygomaticomaxillaris'in alt ucuna olan en kısa mesafesi; ayrıca yüz genişliği ve burun yüksekliği dijital kumpasla ölçüldü.

Bulgular: Çalışma sonucunda 144 yarım kafatasında bulunan foramen infraorbitale'nin %69,4'ünün oval, %15,3'ünün semilunar, %9'unun yuvarlak ve %0,7'sinin üçgen olduğu görüldü. Vakaların %5,6'sında foramen infraorbitale'ye rastlanmadı. Foramen infraorbitale'nin incisura nasalis'e olan ortalama uzaklığı 15±1,9 mm, sutura zygomaticomaxillaris'in alt ucuna olan en kısa uzaklığı 25,37±2,26 mm, margo infraorbitale'ye olan uzaklığı 8,41±1,53 mm ve juga alveolaria'ya olan uzaklığı ise 29,79±2,9 mm olarak bulundu. Ortalama yüz genişliğini 112,76±6,19 mm ve ortalama burun yüksekliğini 51,61±6,19 mm olarak bulduk.

Sonuç: Foramen infraorbitale, özellikle lokal anestezi uygulamaları için oral ve maksillofasial cerrahide kullanılan anatomik bir referans noktasıdır. Çalışmamızın klinisyenlere ve cerrahlara foramen infraorbitale anatomisi hakkında katkı sağlayacağını düşünmekteyiz.

Anahtar Kelimeler: Ağız ve çene cerrahisi, Aksesuar infraorbital foramen, Kuru kafatası, Morfometri, Sınıflandırma

ABSTRACT

Objective: The infraorbital foramen is the hole on the face where the infraorbital canal, which carries the infraorbital artery, vein and nerve, opens. In our study, we aimed to investigate the infraorbital foramen anatomically and morphometrically.

Materials and Methods: In our study, 111 dry skulls and 144 hemifaces were used. The incidence and type of infraorbital foramen were classified. The shortest distance of the infraorbital foramen to the nasal notch, infraorbital margin, alveolar juga of the canines, and the lower end of the zygomaticomaxillary suture; additionally, face width and nasal height were measured with a digital caliper.

Results: As a result of the study, 69.4% of the infraorbital foramen in 144 hemifaces were oval, 15.3% were semilunar, 9% were round, and 0.7% were triangular. We did not encounter infraorbital foramen in 5.6% of the hemifaces. We found the average distance of the infraorbital foramen to the nasal notch as 15±1.9 mm, the shortest distance to the lower end of the zygomaticomaxillary suture as 25.37±2.26 mm, the distance to the infraorbital margin as 8.41±1.53 mm, and the distance to the alveolar juga of the canines as 29.79±2.9 mm. We found the mean face width to be 112.76±6.19 mm and the mean nose height to be 51.61±6.19 mm.

Conclusion: The infraorbital foramen is an anatomical reference point used in oral and maxillofacial surgeries, especially for local anesthesia applications. We believe that our study will provide information about the variations of the infraorbital foramen to clinicians and surgeons.

Keywords: Accessory infraorbital foramen, Classification, Dry skulls, Morphometry, Oral and maxillofacial surgeries.

Sorumlu yazar: Mehmet KARAGULLE, Antalya Bilim University, Vocational School of Health Services, Physiotherapy, Antalya, Turkey, mehmet.karagulle@antalya.edu.tr

Başvuru/Submitted: 03.10.2024 **Kabul/Accepted:** 06.12.2024

Cite this article as: Cengiz M, Karagulle M, Alkan E, Erturk H, Suzen LB. Evaluation of Anatomical and Morphological Characteristics of the Infraorbital Foramen. J TOGU Heal Sci. 2025;5(1):26-37.

INTRODUCTION

The infraorbital foramen (IOF) is positioned around 8 mm below the infraorbital border on both sides of the maxillary bone (1). This foramen is where the infraorbital nerve (ION), vein, and artery all pass (1). As a direct continuation of the trigeminal nerve's maxillary division, the ION travels via the infraorbital groove on the orbit's floor before emerging through the IOF (2). The infraorbital nerve supplies sensory innervation to the upper part of the lips, the wings of the nose, and the lower eyelid region (3). The superior alveolar nerve, a branch of the ION, supplies sensory innervation to the incisor and canine teeth. It additionally supplies sensory innervation to the surrounding mucosa (3).

The location of the infraorbital foramen is of clinical importance. The area must be anesthetized for dental and facial surgery procedures (4). The location of the infraorbital foramen is important in the clinic. The area must be anesthetized for dentistry and facial surgery. In order to provide sufficient anesthesia and prevent complications, the injection must be applied to the correct area. Incorrect injections can damage the infraorbital artery and nerve (5, 6).

It should be noted that the presence of an accessory infraorbital foramen adds to the complexity of this region (7). This accessory infraorbital foramen becomes clinically important when adequate anesthesia cannot be achieved in the region (8).

Detailed description of anatomical changes in the IOF will provide important information to specialists working in areas such as jaw surgery, rhinoplasty applications, and post-traumatic surgical interventions, thus contributing to safer procedures performed in this region. In our study, we aimed to contribute to the literature by investigating the shape of the IOF, the presence of accessory IOF, and the relationship between the location of the IOF and anthropometric measurements.

MATERIALS AND METHODS

The study was performed on 111 dry skulls and 144 hemifaces of unknown age and gender found in the Akdeniz University Medical Faculty Anatomy Department Laboratory. Ethical approval for this research was received from the Akdeniz University Clinical Research Ethics Committee, under approval number KAEK-116, on 8 February 2023.

The measurements were repeated three times by two independent observers. The presence of infraorbital foramen (IOF) and its typing (triangular, oval, round, semilunar) were performed. The incidence of accessory infraorbital foramen (AIOF) was investigated.

The shortest distance of the infraorbital foramen (IOF) to the nasal notch, the shortest distance to the infraorbital margin, the shortest distance to the lower end of the alveolar juga of the canines, and the shortest distance to the lower end of the zygomaticomaxillary suture were measured. Morphometric measurements of the infraorbital foramen were made with a digital caliper. Anthropometric measurements of the infraorbital foramen and cranium were compared. For this comparison, the maximum facial width of the cranium (distance between zygion and zygion- the most lateral point of the zygomatic arch on both sides) and nasal height (distance between the anterior nasal spine and nasion) were measured with a digital caliper. In this way, the relationship between IOF and head morphology was evaluated (Figures 1 and 2).

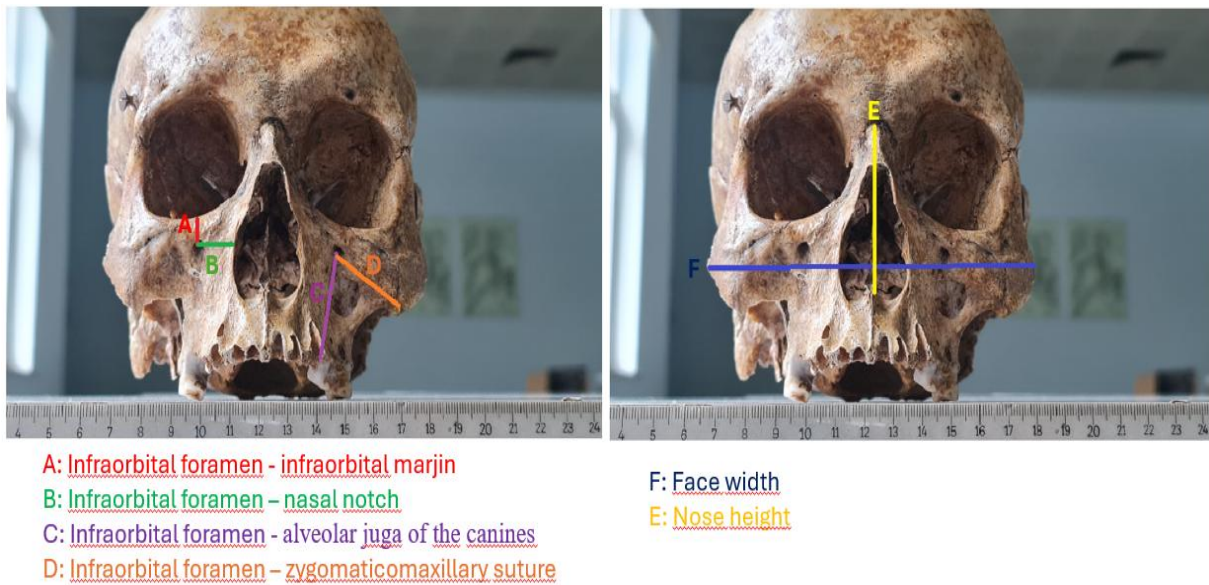


Figure 1: Morphological measurements (It is schematized over dry skulls).

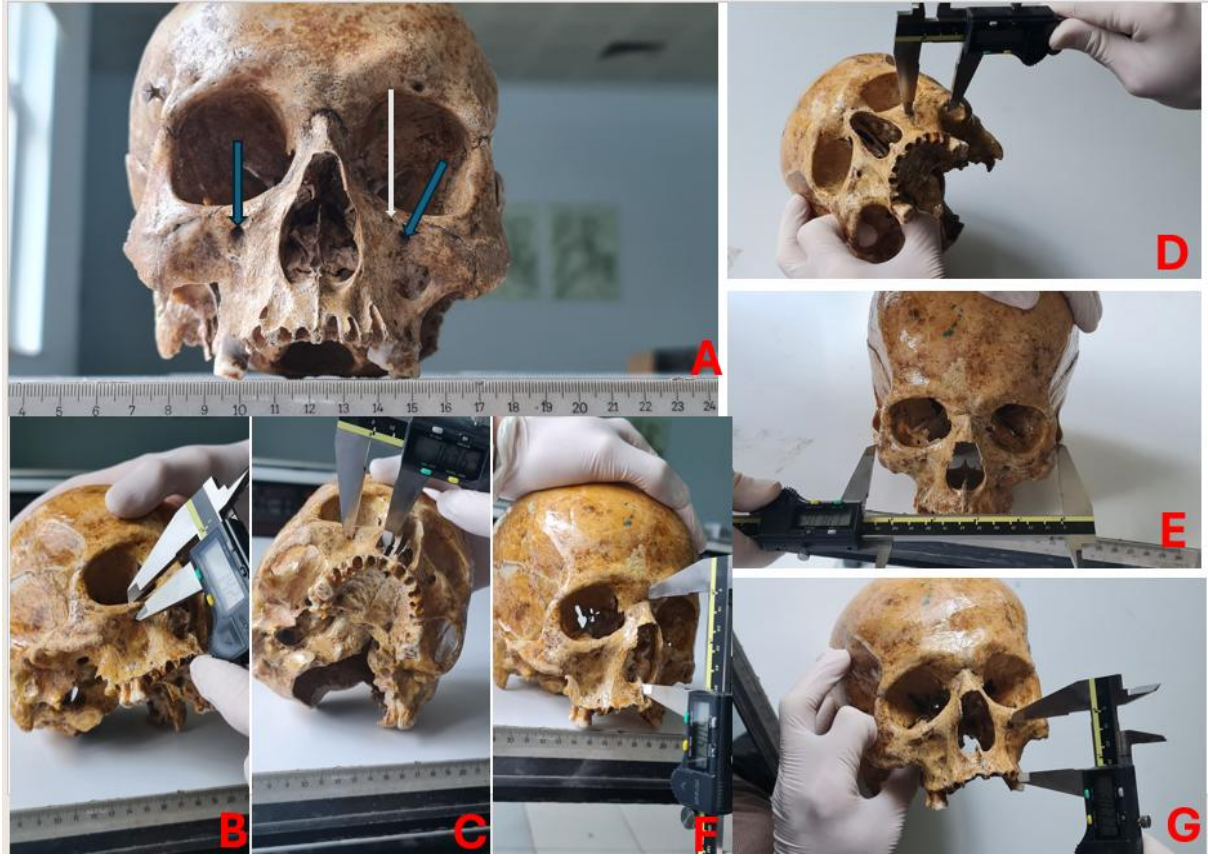


Figure 2: Images obtained from dry skulls (A: Infraorbital foramen is seen on the left side, and accessory infraorbital foramen accompanying the infraorbital foramen superomedially on the right side. Infraorbital foramen is shown with blue arrow and accessory infraorbital foramen is shown with white arrow. B: Infraorbital foramen-infraorbital margin. C: Infraorbital foramen-nasal notch. D: Infraorbital foramen-zygomaticomaxillary suture. E: face width. F: nose height. G: Infraorbital foramen- alveolar juga of the canines)

RESULTS

The IOF types in the 144 hemifaces we examined in our study were; 100 were oval (69.4%), 22 were semilunar (15.3%), 13 were round (9%), and 1 was triangular (0.7%). There was no IOF in 8 of the hemifaces (5.6%) (Table 1). There is no significant difference between the types of infraorbital foramen on the right and left hemiface ($p=0.573$).

Table 1: Incidence of infraorbital foramen types

Table 1	Right		Left		Total	
	<i>n</i>	%	<i>n</i>	%	<i>n</i>	%
Oval	47	65,3	53	73,6	100	69,4
Semilunar	13	18,1	9	12,5	22	15,3
Round	6	8,3	7	9,7	13	9
Triangular	0	0	1	1,4	1	0,7
Dry cranium without infraorbital foramen	6	8,3	2	2,8	8	5,6
Incidence of accessory infraorbital foramen	17	23,6	32	44,4	49	34

We found accessory infraorbital foramen in 49 (34%) of the hemifaces. We found 17 of these foramen in the right hemiface and 32 in the left hemiface. We observed 10 of these accessory infraorbital foramina bilaterally; that is, we found accessory infraorbital foramina bilaterally in five dry skulls. The location of all accessory infraorbital foramen is superomedial to the IOF (Figure 3).

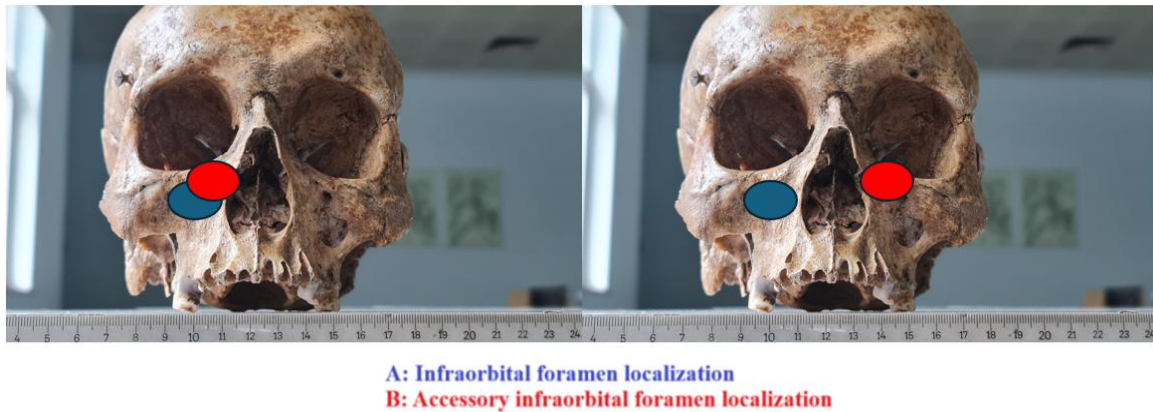


Figure 3: Localization of infraorbital foramen and accessory infraorbital foramen (It is schematized over dry skulls).

There is no significant difference between the types of infraorbital foramen and the incidence of accessory infraorbital foramen ($p=0.233$). Accessory infraorbital foramen was found significantly more frequently in the left hemiface than in the right hemiface ($p=0.017$).

We found the average distance of the infraorbital foramen to the nasal notch as 15 ± 1.9 mm (right 15.01 ± 2.05 mm, left 14.98 ± 1.75 mm), the average shortest distance to the lower end of the zygomaticomaxillary suture as 25.37 ± 2.26 mm (right 25.59 ± 2.21 , left 25.15 ± 2.29 mm), the average shortest distance to the infraorbital margin as 8.41 ± 1.53 mm (right 8.12 ± 1.56 , left 8.68 ± 1.45 mm), and the average shortest distance to the lower end of the the shortest distance

to the lower end of the alveolar juga of the canines, as 29.79 ± 2.9 mm (right 29.79 ± 2.63 , left 29.79 ± 3.15 mm). We found the mean face width to be 112.76 ± 6.19 mm and the mean nose height to be 51.61 ± 6.19 mm (Table 2).

RMS (Mean Square Root Difference Value) is a statistical criterion that measures the magnitude of changes in quantities. It is calculated by taking the square root of the mean value of the square function of the instantaneous values. We found the average RMS value of face width and nose height to be 124.04 ± 6.39 mm (Table 2).

Table 2: Morphological measurements results

Table 2	Right		Left		Total	
	Mean	SD	Mean	SD	Mean	SD
Nasal notch	15,01	2,05	14,98	1,75	15,00	1,90
Zygomaticomaxillary suture	25,59	2,21	25,15	2,29	25,37	2,26
Infraorbital marjin	8,12	1,56	8,68	1,45	8,41	1,53
Alveolar juga of the canines	29,79	2,63	29,79	3,15	29,79	2,90
Nose height					51,61	3,51
Face width					112,76	6,19
Root mean square (RMS)					124,04	6,39

SD: Standard Deviation

While there was no statistically significant difference between the distances of the right and left infraorbital foramen to the nasal notch ($p=0.341$), the lower end of the zygomaticomaxillary suture ($p=0.203$) and the lower end of the the shortest distance to the lower end of the alveolar juga of the canines, ($p=0.778$), there was a significant difference between the distances to the infraorbital margin ($p=0.014$). This difference may be significant because accessory infraorbital foramen is more common on the left side. When statistical tests were repeated excluding hemifaces with accessory infraorbital foramen, no significant difference was found.

As a result of correlation analyses, no significant relationship was found between horizontal measurements (distance to nasal notch and lower end of zygomaticomaxillary suture) and face width. Among the vertical measurements (distance to infraorbital margin, the shortest distance to the lower end of the alveolar juga of the canines, and nasal height), there was a moderate positive correlation between the shortest distance to the lower end of the alveolar juga of the canines, and nasal height measurements ($r=0.529$ $p<0.001$). It is normal that the RMS value calculated from face width and nose height shows a high correlation with face width and nose height (Table 3).

The RMS value showed a weak to moderate correlation with the distance from horizontal measurements to the lower end of the zygomaticomaxillary suture ($r=0.354$, $p<0.001$) and the distance from vertical measurements to the lower end of the the shortest distance to the lower end of the alveolar juga of the canines, ($r=0.452$ $p<0.001$) (Table 3).

Table 3: Correlation table

Table 3	NN	ZS	FW	IM	AJ	NH	RMS
Nasal notch (NN)		,029	,177	,223	,394	,290	,279*
Zygomaticomaxillary suture (ZS)	,029		,239	,048	,423	,340	,354*
Face width (FW)	,177	,239		,091	,238	,476	,838*
Infraorbital marjin (IM)	,223	,048	,091		,024	,067	,090*
Alveolar juga of the canines (AJ)	,394	,423	,238	,024		,529*	,452*
Nose height (NH)	,290	,340	,476	,067	,529*		,866*
Mean Square Root Difference Value (RMS)	,279*	,354*	,838*	,090	,452*	,866*	

* $P<0,05$, NN: Nasal notch, ZS: Zygomaticomaxillary suture, FW: Face width, IM: Infraorbital marjin, AJ: Alveolar juga of the canines, NH: Nose height), RMS: Mean Square Root Difference Value

DISCUSSION AND CONCLUSION

The infraorbital foramen is an important anatomical structure located in the middle part of the face. The infraorbital nerve passing through this opening provides sensory innervation to the upper lip, nose, lower eyelid and upper teeth (9). The location and anatomy of the infraorbital foramen are important in local anesthesia applications and surgical procedures (3, 10). In our study, the anatomy of the IOF and AIOF was analyzed in detail.

The oldest literature information about the anatomy and variations of the infraorbital foramen was reported by Gruber et al. in 1875 (11). The number of accessory infraorbital foramen may be between 1 and 5 and its importance has been reported in the literature (11, 12). In a study conducted on 1400 dry skulls, Kadanoff et al. (13) reported the presence of double accessory infraorbital foramina in 131 (9%), triple in 7 (0.5%), and greater than triple in 4 (0.3%). Investigation of the incidence of accessory infraorbital foramen is restricted to the table

4. The incidence of accessory infraorbital foramen has been reported to be between 7% and 19.91% in the literature (14, 15). We believe that the reason for these differences in the literature is due to the different sample sizes of the studies and their being conducted in different societies. The incidence of accessory infraorbital foramen should be taken into consideration in maxillofacial surgery applications. Knowing the presence and number of accessory infraorbital foramen is important in terms of anatomy and clinic (6, 16).

The infraorbital foramen type is an important anatomical difference that varies from person to person and affects surgical procedures. Differences such as whether this foramen is round, oval or semilunar affect the location of the nerve, surgical approach and complication risk. Therefore, it is important for surgeons and clinicians to know these anatomical variations. Table 5 shows the literature comparison table of IOF type. Although there are differences in the literature in the Egyptian population, the most common type is reported as oval. Round is the second most common type, while semilunar is the third. Triangular type is the least common shape in the literature (3, 16, 17). The shapes seen in our study are also consistent with the literature.

To determine the location and exact position of the infraorbital foramen, distances to various anatomical structures must be evaluated. The distance between the IOF and the infraorbital margin was found to be an average of 6.1 mm in a study by Hindy and Abdel-Raouf (24), an average of 8.6 mm by Chung et al. (25), an average of 6.37 mm by Macedo et al (26), an average of 9.6 mm by Canan et al (27), and an average of 6.15 mm by Singh (21). In our study, we found the average to be 8.4 mm, which is consistent with the literature. In the literature, the distance between the infraorbital margin and the IOF varies between 6.1 mm and 9.6 mm. This anatomical difference is probably due to the different ethnic origins of the study groups.

The average distance between the IOF and nasal notch was reported as 17.23 mm by Hindy and Abdel-Raouf (24), 14.7 mm by Kazkayasi et al. (28), 17.67 mm by Macedo et al. (26), and 15.56 mm by Singh (21). In our study, we found an average of 15 mm, which is consistent with the literature. However, knowing the slight differences in social distances is important for correctly determining the location of the infraorbital nerve and vessels, especially in procedures such as sinus surgery and orbital surgery.

As a result of the correlation analysis of the morphometric measurements we conducted in our study, we found that the distance from the horizontal measurements to the nasal notch

and the distance from the vertical measurements to the infraorbital margin did not correlate with the face width, nose height and RMS value. Accordingly, the IOF does not change place with the extension or widening of the face. The infraorbital foramen is located at a relatively fixed point, independent of the dimensions of the face or the maxillary bone.

The localization of the accessory infraorbital foramen has been reported in the literature to be superomedial to the IOF (20, 27). In our study, we found all of the accessory infraorbital foramina superomedial to the IOF, consistent with the literature. In cases where the face cannot be adequately anesthetized, knowing the localization of the accessory infraorbital foramen will facilitate clinical practice.

Table 4: Studies on the incidence of accessory infraorbital foramen

Study	Year	Population	Materials	Accessory IOF incidence
Aziz et al.(18)	2000	Türkiye	47 dry skulls	15%
Elias et al.(19)	2004	Brazil	210 dry skulls	15.23%
Boopathi et al.(20)	2010	South India	80 dry skulls	16.25%
Singh(21)	2011	India	55 dry skulls	18.2%
Tezer et al.(15)	2011	Türkiye	112 dry skulls	7%
Elsheikh et al. (17)	2013	Egyptian	59 dry skulls	16.9%
Sharma et al. (4)	2015	India	50 dry skulls	15%
Nanayakkara et al.(3)	2016	Sri Lank	54 dry skulls	7,4%
Shin et al.(22)	2020	Korean	25 cadavers	18.2%
Suntirumjairucksa& Vilai Chentanez (14)	2021	Thailand	216 dry skulls and 15 embalmed cadaveric heads	19,91%
Jafri et al. (16)	2022	Lahore	72 dry skulls	8.2%
Our study	2024	Türkiye	111 dry skulls	34%

Table 5: Studies on infraorbital foramen types

Study	Year	Population	Materials	Oval	Semilunar	Round	Triangular
Tezer et al. (23)	2014	Türkiye	112 dry skulls	64.7%	8.3%	27%	-
Singh (21)	2011	India	55 dry skulls	70.8%	-	29.2%	-
Elsheikh et al. (17)	2013	Egyptian	59 dry skulls	23.18%	46.37%	30.43%	-
Nanayakkara et al. (3)	2016	Sri Lank	54 dry skulls	74.9%	28.6%	15.3%	18.6%
Jafri et al. (16)	2022	Lahore	72 dry skulls	39.2%	15.65%	27.65%	23.25%
Our study	2024	Türkiye	111 dry skulls	69.4%	15.3%	9%	0.7%

The fact that the demographic characteristics of the skull bones used in the study are unknown is a situation that limits the generalizability of the results to the general population. However, the comprehensiveness of the study and the inclusion of a large number of anatomical measurements increase the reliability of the findings.

One of the limitations of our investigation is that the ages and genders of the dry bones employed in our investigation are undetermined.

Our study will strengthen the anatomical basis of invasive procedures performed in the facial region, especially in jaw surgery and rhinoplasty, and will provide a new perspective to clinical practice. Our findings have contributed to the literature on a better understanding of IOF anatomy and its social differences. We believe that the findings will reduce the risk of iatrogenic injury, especially in cases such as post-traumatic reconstruction surgery, and will help create personalized treatment plans.

Financial support: none

Conflict of interest: none

Ethics committee approval: Ethical approval for this research was received from the XXX University Clinical Research Ethics Committee, under approval number KAEK-116, on 8 February 2023.

Author Contributions: Acquisition of data: M.K., M.C., E. A. Analysis of data: M.K., M.C., E. A., L.B.S., H.E. Interpretation of data: M. K., M.C., E. A., L.B.S., H.E. Drafting of the manuscript: M.K., M.C. Study conception and design of the work: M.K. Critical revision of the manuscript: E. A., L.B.S., H.E., M.K. Final approval of the article: M.K., M.C., E. A., L.B.S., H.E.

REFERENCES

1. Desai RN, Batra N. Evaluation of Infraorbital Foramen Position Using Cone-Beam Computed Tomography in a Cohort of Central Gujarat, Indian Population. *Cureus*. 2024;16(1).
2. Aggarwal A, Kaur H, Gupta T, Tubbs RS, Sahni D, Batra Y, Sondekoppam RV. Anatomical study of the infraorbital foramen: a basis for successful infraorbital nerve block. *Clinical anatomy*. 2015;28(6):753-60.
3. Nanayakkara D, Peiris R, Mannapperuma N, Vadysinghe A. Morphometric analysis of the infraorbital foramen: the clinical relevance. *Anatomy research international*. 2016;2016(1):7917343.
4. Sharma S, Sharma A, Thakur C, Modi BS. Anthropometric measurements of infraorbital foramen and its anatomic variations in dried human skulls. *Int J Anat Res*. 2015;3(4):1487-90.
5. Isaac J, Walker L, Ali SR, Whitaker IS. An illustrated anatomical approach to reducing vascular risk during facial soft tissue filler administration—a review. *JPRAS open*. 2023;36:27-45.
6. Yılmaz R, Arıcan Ş, Hacıbeyoğlu G, Uzun ST. Effects of Bilateral Infraorbital-Supraorbital Nerve Block on Postoperative Pain Control and Drug Consumption in Rhinoplasty. *European Journal of Therapeutics*. 2021;27(3):235-40.
7. Polo CL, Abdelkarim AZ, von Arx T, Lozanoff S. The morphology of the infraorbital nerve and foramen in the presence of an accessory infraorbital foramen. *Journal of craniofacial surgery*. 2019;30(1):244-53.
8. Hwang K, Lee SJ, Kim SY, Hwang SW. Frequency of existence, numbers, and location of the accessory infraorbital foramen. *Journal of craniofacial surgery*. 2015;26(1):274-6.
9. Standring S, Gray H. *Gray's anatomy: the anatomical basis of clinical practice*. (No Title). 2022.
10. Koçyigit P, Güner MA. Kozmetik ve Cerrahi Uygulamalar için Yüz Anatomisi/Facial Anatomy for Cosmetic and Surgical Procedures. *Türk Dermatoloji Dergisi*. 2015;9(3):115.
11. Grüber W. Über die infraorbitalkanäle bei dem menschen und bei den Säugetieren. *Mem de l'Acad Imp des Sciences de St-Petersbourg*. 1874;21:1-27.
12. Leo JT, Cassell MD, Bergman RA. Variation in human infraorbital nerve, canal and foramen. *Annals of Anatomy-Anatomischer Anzeiger*. 1995;177(1):93-5.
13. Kadanoff D, Mutanoff S, Jordanov J. Über die Hauptöffnungen resp. incisurae des Gesichtsschadels. *Morphologisches Jahrbuch*. 1970;115:405-7.
14. Suntirumjairucksa J, Chentanez V. Localization of infraorbital foramen and accessory infraorbital foramen with reference to facial bony landmarks: predictive method and its accuracy. *Anatomy & Cell Biology*. 2022;55(1):55-62.
15. Tezer M, Öztürk A, Akgül M, Gayretli Ö, Kale A. Anatomic and morphometric features of the accessory infraorbital foramen. *Journal of Morphological Sciences*. 2017;28(2):0-.
16. Jafri SR, Muneeb A, Qureshi F, Sikander H, Arif A, Arshad A. Morphometric Analysis of Infraorbital Foramen in Human Dry Skulls. *Pakistan Journal of Medical & Health Sciences*. 2022;16(10):670-.
17. Elsheikh E, Nasr WF, Ibrahim AAS. Anatomical variations of infraorbital foramen in dry human adult Egyptian skulls, Anthropometric measurements and surgical relevance. *An International Journal of Otorhinolaryngology Clinics*. 2011;5(3):1-5.
18. Aziz SR, Marchena JM, Puran A. Anatomic characteristics of the infraorbital foramen: a cadaver study. *Journal of oral and maxillofacial surgery*. 2000;58(9):992-6.
19. Elias M, Silva R, Pimentel M, Cardoso V, Ravello T, Babinski MA. Morphometric analysis of the infraorbital foramen and accessories foraminas in Brazilian skulls. *Int J Morphol*. 2004;22(4):273-8.
20. Boopathi S, Chakravarthy Marx S, Dhalapathy S, Anupa S. Anthropometric analysis of the infraorbital foramen in a South Indian population. *Singapore medical journal*. 2010;51(9):730.
21. Singh R. Morphometric analysis of infraorbital foramen in Indian dry skulls. *Anatomy & cell biology*. 2011;44(1):79-83.
22. Shin K-J, Lee S-H, Park M-G, Shin HJ, Lee AG. Location of the accessory infraorbital foramen with reference to external landmarks and its clinical implications. *Scientific Reports*. 2020;10(1):8566.

23. Tezer M, Öztürk A, Gayretli Ö, Kale A, Balcioglu H, Şahinoğlu K. Morphometric analysis of the infraorbital foramen and its localization relative to surgical landmarks. *Minerva Stomatol.* 2014;63(10):333-40.
24. Hindy A, Abdel-Raouf F. A study of infraorbital foramen, canal and nerve in adult Egyptians. *Egyptian dental journal.* 1993;39(4):573-80.
25. Chung M, Kim H, Kang H, Chung I. Locational relationship of the supraorbital notch or foramen and infraorbital and mental foramina in Koreans. *Cells Tissues Organs.* 1995;154(2):162-6.
26. Macedo V, Cabrini R, Faig-Leite H. Infraorbital foramen location in dry human skulls. *Journal of Morphological Sciences.* 2017;26(1):0-.
27. Canan S, Asim ÖM, Okan B, Ozek C, Alper M. Anatomic variations of the infraorbital foramen. *Annals of plastic surgery.* 1999;43(6):613-7.
28. Kazkayasi M, Ergin A, Ersoy M, Bengi O, Tekdemir I, Elhan A. Certain anatomical relations and the precise morphometry of the infraorbital foramen–canal and groove: an anatomical and cephalometric study. *The Laryngoscope.* 2001;111(4):609-14.