



## Case Report

### Thyroid Hemiagenesis Co-occurrence with Unilateral Renal Agenesis\*

Özhan Özcan<sup>1</sup>, Celil Uğurlu<sup>2</sup>, İbrahim Erdim<sup>3</sup>

<sup>1</sup>Sinop Atatürk State Hospital, Intensive Care Unit, Sinop, Türkiye.

<sup>2</sup>Erbaa State Hospital, General Surgery Tokat, Türkiye.

<sup>3</sup>Erbaa State Hospital, Otorhinolaryngology, Tokat, Türkiye.

**Cite this article as:** Özcan, Ö., Uğurlu, C., Erdim, İ. (2025). Thyroid hemiagenesis co-occurrence with unilateral renal agenesis. *Northern Journal of Health Sciences*, 1(1), 38-42.

#### Corresponding Author:

Özhan Özcan

#### E-mail:

ozhanturkey@hotmail.com

#### ORCID IDs of the authors:

Ö.Ö. 0000-0001-9928-2383

C.U. 0000-0002-7159-7305

İ.E. 0000-0003-1840-6052

**Received:** October 6, 2024

**Revision Requested:** December 17, 2024

**Accepted:** December 17, 2024

**Publication Date:** January 24, 2025

\*This study was presented as an Electronic Poster with the number PS-0321 at the 20th National Surgery Congress, April 13-17, 2016, Belek/ Antalya.

#### Abstract

Thyroid Hemiagenesis (THA) is an uncommon congenital disorder characterized by the failure of one thyroid lobe with or without the isthmus to develop. This condition may arise from an abnormal descent or agenesis of the thyroid tissue. Many cases of THA remain asymptomatic and are frequently detected incidentally. This report presents a patient with multinodular goiter, concomitant left-sided thyroid, and renal agenesis. A 40-year-old male presented with a long-standing progressive thyroid enlargement, exhibiting euthyroid status. The patient reported compressive symptoms, including dysphagia, dyspnea, and hoarseness due to the goiter's size. This case report documents the first known case of concurrent THA and Unilateral Renal Agenesis (URA), underscoring the importance of thorough preoperative evaluation for congenital anomalies in THA patients. The absence of the left-sided paired organs in this patient adds to the growing body of literature on the association between these congenital abnormalities.

**Keywords:** Multinodular Goiter, Thyroid Hemiagenesis, Unilateral Renal Agenesis

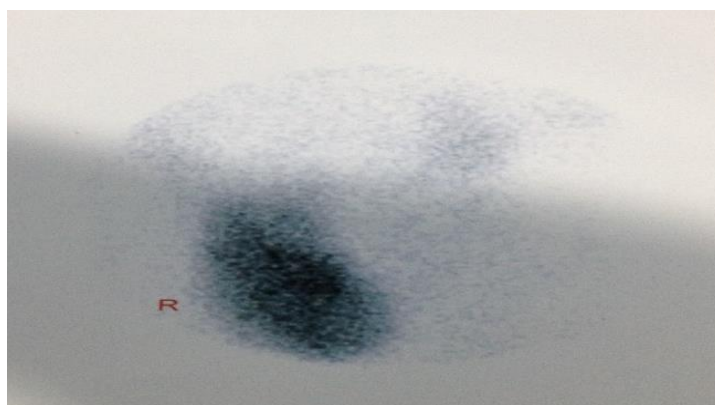
## INTRODUCTION

Thyroid hemiagenesis (THA) is an uncommon congenital disorder characterized by the failure of one thyroid lobe with or without the isthmus to develop. This condition may arise from an abnormal descent or agenesis of the thyroid tissue. Many cases of THA remain asymptomatic and are frequently detected incidentally. THA is often associated with various thyroid pathologies, such as nodules, de Quervain thyroiditis, hyperthyroidism, thyroid adenomas, Graves' disease, Hashimoto's thyroiditis (Gurleyik & Gurleyik, 2015; Kirdak et al., 2014). It has been reported that genetic abnormalities may play a role in the etiology of THA, as reported in monozygotic twins (Mikosch et al., 2020). Additionally, THA can co-occur with other congenital anomalies, such as renal system abnormalities, mixed connective tissue disease, Down's Syndrome and facial malformations (Lesi et al., 2022). Unilateral renal agenesis (URA) is a congenital absence of one kidney, resulting from the failure of embryonic kidney formation. URA has an incidence of approximately 1 in 2000 live births (Westland et al., 2013). This report presents a patient with multinodular goiter, concomitant left-sided thyroid, and renal agenesis.

## Case Report

A 40-year-old male presented with a long-standing progressive thyroid enlargement, exhibiting euthyroid status. The patient reported compressive symptoms, including dysphagia, dyspnea, and hoarseness due to the goiter's size. Physical examination revealed an enlarged right thyroid lobe and isthmus, with a firm, non-tender nodule at the lower pole. The left thyroid lobe was not palpable. Laboratory investigations showed normal levels of free thyroxine (T4: 0.9 ng/dL, normal range: 0.93–1.7 ng/dL), thyroid-stimulating hormone (TSH: 0.86  $\mu$ IU/mL, normal range: 0.27–4.2  $\mu$ IU/mL), and parathyroid hormone (PTH: 58 pg/mL, normal range: 15–65 pg/mL).

High-resolution ultrasonography indicated an enlarged right thyroid lobe (40×34×74 mm) with a cystic, degenerative, isoechoic nodule (37×25 mm) at the lower pole. The left thyroid lobe was absent. Fine-needle aspiration biopsy of the dominant nodule in the right lobe revealed non-atypical thyroid cytology. Radionuclide scintigraphy ( $^{99m}$ Tc pertechnetate) confirmed a hyperplastic right lobe with normoactive heterogeneous nodules in the lower region, while the left lobe was absent (Figure 1).



**Figure 1.** Tc-99m pertechnetate scintigraphy showing the right thyroid lobe and the isthmus. The left lobe was not seen.

Upon reviewing the patient's medical history, it was noted that he had left-sided renal agenesis. Regular urological follow-up had demonstrated

normal renal function, as confirmed by abdominopelvic computed tomography (CT) (Figure 2).

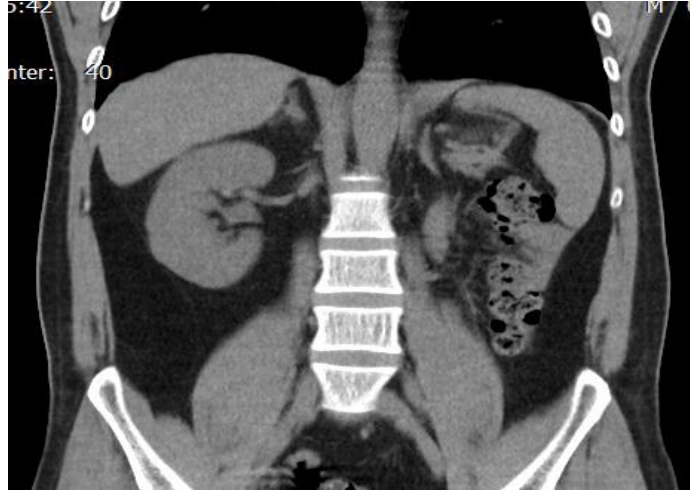


Figure 2. Abdominopelvic CT showing absence of left kidney

No relevant family medical history was reported. Preoperative evaluation suggested multinodular goiter, and surgery was performed. Intraoperatively, the right thyroid lobe and isthmus were found extending to the left of the trachea, and both structures were removed entirely (Figure 3). The patient was discharged

on the first postoperative day without complications and started on levothyroxine sodium (0.1 mg). Histopathological analysis confirmed the diagnosis of multinodular adenomatous goiter. The patient's postoperative course was uneventful, and follow-up has been stable.

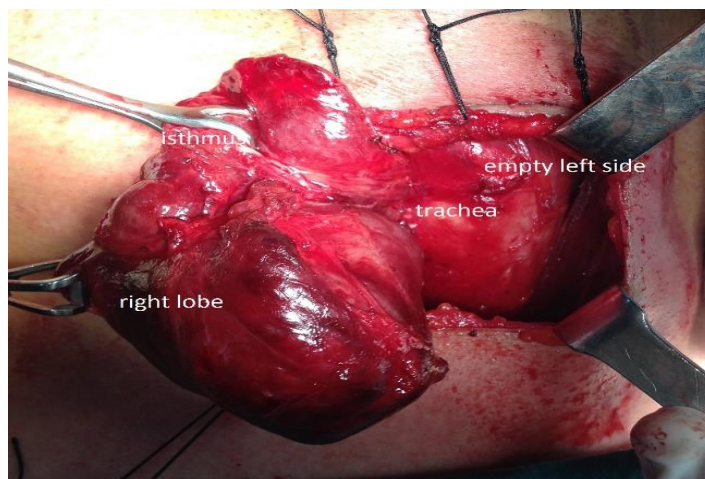


Figure 3. Intraoperative view of the thyroid

## DISCUSSION

The embryological development of the thyroid originates from the endoderm of the primitive pharynx. The thyroid primordium migrates to its final anatomical location anterior to the thyroid cartilage and trachea. THA represents the incomplete genesis of one thyroid lobe with or without the isthmus, and the precise etiology remains unclear. It is a rare congenital anomaly, with an estimated prevalence of 0.05–0.2% based on ultrasonographic screening (Lesi et al., 2022; Shabana et al., 2000). Different studies have shown that it usually affects the left lobe with an L:R ratio of 4:1, with 44–50% also lacking the isthmus. The reason for this left-sided predominance remains unknown, though there is a documented propensity for agenesis in paired organs on the left side (7-9). Although our patient was male, THA is more frequently observed in females, a trend that may reflect the higher prevalence of thyroid disorders among women (Mikosch et al., 1999; Melnick & Stemkowski, 1981; Sereke et al., 2021; Shabana et al., 2000). Ruchala et al. conducted a large cohort study involving 40 patients, which demonstrated a significant female predominance, with a female-to-male ratio of 7:1 (Ruchala et al., 2009).

To date, four genes have been implicated in thyroid development: TTF-1 (Nkx2.1), TTF-2 (FOXE1), Pax8, and the TSH receptor gene (Castanet et al., 2005). While most cases of THA are sporadic, familial clusters have also been reported (Szczepanek et al., 2011). In the literature, THA has been linked to malformations in patients with Pax8 gene mutations (Hermanns et al., 2013). Moreover, experimental studies

demonstrate that Pax8 is expressed during the development of both the thyroid and renal systems, underscoring its role as a shared genetic factor in the embryogenesis of these organs (Plachov et al., 1990). Despite extensive review, we could not find any previous cases of URA occurring alongside THA on the same side. Due to limited resources, genetic analysis could not be conducted in this instance. Nevertheless, our patient represents a notable example of concurrent left-sided thyroid and renal agenesis.

Our patient underwent total thyroidectomy for compressive multinodular goiter. Notably, 16% of THA cases are associated with hyperthyroidism, 8% with multinodular goiter, 7% with papillary carcinoma, and 7% with simple goiter (Karabay et al. 2003; Kirdak et al., 2014). Ultrasonography and Tc-99m scintigraphy were critical in diagnosing the absence of the left thyroid lobe. Intraoperative findings confirmed the lack of thyroid tissue on the left side, with no abnormalities in the right parathyroid tissue. Postoperatively, the patient remained asymptomatic, without any evidence of hypocalcemia or hypoparathyroidism.

## CONCLUSION

This case report documents the first known case of concurrent THA and URA, underscoring the importance of thorough preoperative evaluation for congenital anomalies in THA patients. The absence of the left-sided paired organs in this patient adds to the growing body of literature on the association between these congenital abnormalities.

**Declaration of Interests:** The authors have no conflict of interest to declare.

## References

- Castanet, M., Leenhardt, L., Léger, J., Simon-Carré, A., Lyonnet, S., Pelet, A., Czernichow, P., & Polak, M. (2005). Thyroid hemiagenesis is a rare variant of thyroid dysgenesis with a familial component but without Pax8 mutations in a cohort of 22 cases. *Pediatric Research*, 57(6), 908-913. <https://doi.org/10.1203/01.PDR.0000161409.04177.36>
- Gurleyik, G., & Gurleyik, E. (2015). Thyroid hemiagenesis associated with hyperthyroidism. *Case Reports in Otolaryngology*, 2015, 829712. <https://doi.org/10.1155/2015/829712>
- Hermanns, P., Grasberger, H., Cohen, R., Freiberg, C., Dörr, G., Refetoff, S., & Pohlenz, J. (2013). Two cases of thyroid dysgenesis caused by different novel PAX8 mutations in the DNA-binding region: In vitro studies reveal different pathogenic mechanisms. *Thyroid*, 23(7), 791-796. <https://doi.org/10.1089/thy.2012.0141>
- Karabay, N., Comlekci, A., Canda, M. S., Bayraktar, F., & Degirmenci, B. (2003). Thyroid hemiagenesis with multinodular goiter: A case report and review of the literature. *Endocrine Journal*, 50(4), 409-413. <https://doi.org/10.1507/endocrj.50.409>
- Kirdak, T., Gulcu, B., & Korun, N. (2014). Thyroid hemiagenesis associated with retrosternal nodular goiter: A case report. *Acta Medica Iranica*, 52(9), 725-726. PMID: 25325212
- Lesi, O. K., Thapar, A., Appaiah, N. N. B., Iqbal, M. R., Kumar, S., Maharaj, D., Saad Abdalla Al-Zawi, A., & Dindyal, S. (2022). Thyroid hemiagenesis: Narrative review and clinical implications. *Cureus*, 14(2), e22401. <https://doi.org/10.7759/cureus.22401>
- Melnick, J. C., & Stemkowski, P. E. (1981). Thyroid hemiagenesis (hockey stick sign): A review of the world literature and a report of four cases. *The Journal of Clinical Endocrinology & Metabolism*, 52(2), 247-251. <https://doi.org/10.1210/jcem-52-2-247>
- Mikosch, P., Gallowitsch, H. J., Kresnik, E., et al. (1999). Thyroid hemiagenesis in an endemic goiter area diagnosed by ultrasonography: Report of sixteen patients. *Thyroid*, 9(11), 1075-1084. <https://doi.org/10.1089/thy.1999.9.1075>
- Mikosch, P., Weixlbaumer, V., Irrgang, M., Aistleitner, A., & Trifina-Mikosch, E. (2020). Hemiagenesis of the thyroid gland detected by coincidence—what is the clinical relevance? *Wiener Klinische Wochenschrift*, 170, 403-409. <https://doi.org/10.1007/s10354-020-00783-w>
- Plachov, D., Chowdhury, K., Walther, C., Simon, D., Guenet, J. L., & Gruss, P. (1990). Pax8, a murine paired box gene expressed in the developing excretory system and thyroid gland. *Development*, 110(2), 643-651. <https://doi.org/10.1242/dev.110.2.643>
- Ruchala, M., Szczepanek, E., Szaflarski, W., et al. (2010). Increased risk of thyroid pathology in patients with thyroid hemiagenesis: Results of a large cohort case-control study. *European Journal of Endocrinology*, 162, 153-160. <https://doi.org/10.1530/EJE-09-0590>
- Sereke, S. G., Oriekot, A., & Bongomin, F. (2021). Thyroid hemiagenesis with a TI-RADS 2 nodule in the contralateral lobe. *Thyroid Research*, 14, 10. <https://doi.org/10.1186/s13044-021-00101-5>
- Shabana, W., Delange, F., Freson, M., Osteaux, M., & De Schepper, J. (2000). Prevalence of thyroid hemiagenesis: Ultrasound screening in normal children. *European Journal of Pediatrics*, 159, 456-458. <https://doi.org/10.1007/s004310051307>
- Szczepanek, E., Ruchala, M., Szaflarski, W., et al. (2011). FOXE1 polyalanine tract length polymorphism in patients with thyroid hemiagenesis and subjects with normal thyroid. *Hormone Research in Paediatrics*, 75, 329-334. <https://doi.org/10.1159/000322874>
- Westland, R., Schreuder, M. F., Ket, J. C., & van Wijk, J. A. (2013). Unilateral renal agenesis: A systematic review on associated anomalies and renal injury. *Nephrology Dialysis Transplantation*, 28(7), 1844-1855. <https://doi.org/10.1093/ndt/gft012>