

# Assessment of Treatment Approaches for Oroantral Communication and Fistulas

## Oroantral Açıklık ve Fistüllerin Tedavi Yaklaşımlarının Değerlendirilmesi

İlgin ARI<sup>1</sup>



<sup>1</sup>Hacettepe University, Faculty of Dentistry,  
Department of Oral and Maxillofacial Surgery  
Ankara/ Türkiye

Selen ADİLOĞLU<sup>1</sup>



<sup>1</sup>Hacettepe University, Faculty of Dentistry,  
Department of Oral and Maxillofacial Surgery  
Ankara/ Türkiye

Alper AKTAŞ<sup>2</sup>



<sup>1</sup>Hacettepe University, Faculty of  
Dentistry, Department of Oral and  
Maxillofacial Surgery Ankara/ Türkiye

Ahmet Emin KIZILKAYA<sup>1</sup>



<sup>1</sup>Hacettepe University, Faculty of Dentistry,  
Department of Oral and Maxillofacial Surgery  
Ankara/ Türkiye



### ABSTRACT

**Objective:** The aim of this study was to investigate and compare the treatment methods of large size oroantral defects (OADs) and their clinical outcomes.

**Methods:** The patients who referred our clinic between 2017 and 2023 suffering from oroantral fistula (OAF) and the cases which was occurred oroantral communication (OAC) larger than 5mm during oral procedures were included in the study. The size, type and cause of OAD, treatment method, the patient's demographic data was recorded. VAS scale, analgesic requirement, the edema, and mouth opening measurements were obtained from preoperative day and postoperative records at 3, 7, 10 days after surgery.

**Results:** 23 patient (8 OAF, 15 OAC) was included in this study. 9 of them was treated with buccal advancement flap (BAF), 10 with buccal fat pad (BFP) and 4 with press-fit technique. No problem was occurred at the healing process. Only in one patient BFP application was failed, and after 2 months second surgery was performed, and the area was fully covered. According to postoperative clinical outcomes, any statistically significance wasn't observed between groups in the terms of vas scale, analgesic requirement, edema and trismus at any timepoint ( $p \geq 0.05$ ). Although there was insignificance at all parameters between treatment groups, VAS scale and analgesic requirement was less than BAF and BFP in press fit.

**Conclusion:** BAF, BFP and press-fit methods are reliable and well-known techniques for OAD management, however, further clinical studies with larger sample sizes are needed to create treatment algorithm for OAD.

**Keywords:** Oroantral communication, oroantral fistula, buccal flap, buccal fat pad, press-fit

### ÖZ

**Amaç:** Bu çalışmanın amacı, büyük boyuttaki oroantral defektlerin (OAD) tedavi yöntemlerini araştırmak ve klinik sonuçlarını karşılaştırmaktır.

**Yöntemler:** Bu çalışmaya 2017-2023 yılları arasında 5 mm'den büyük oroantral fistül (OAF) ve oroantral açıklık (OAC) nedeniyle kliniğimize başvuran hastalar dahil edildi. Defektin boyutu, tipi, nedeni, tedavi yöntemi ve hastaların demografik verileri kaydedildi. Preoperatif gün ile cerrahi sonrası 3., 7. ve 10. günlerde VAS ölçeği, analjezik ihtiyacı, ödem ve ağız açıklığı ölçümleri arşiv taraması ile kayıt altına alındı.

**Bulgular:** Çalışmaya 23 hasta (8 OAF, 15 OAC) dahil edildi. Hastaların 9'u bukkal kaydırma flebi (BAF), 10'u bukkal yağ pedi (BFP) ve 4'ü press-fit tekniği ile tedavi edildi. İyileşme sürecinde herhangi bir sorun yaşanmadı. Sadece bir hastada BFP uygulaması başarısız oldu; iki ay sonra yapılan ikinci cerrahi işlemle alan tamamen kapatıldı. Postoperatif klinik sonuçlara göre, gruplar arasında VAS ölçeği, analjezik ihtiyacı, ödem ve trismus açısından herhangi bir istatistiksel anlamlılık gözlenmedi ( $p > 0.05$ ). Tüm parametreler arasında gruplar arasında anlamlı fark olmamakla birlikte, press-fit tekniğinde VAS ölçeği ve analjezik ihtiyacı BAF ve BFP yöntemlerine göre daha düşüktü.

**Sonuç:** BAF, BFP ve press-fit yöntemleri OAD yönetimi için güvenilir ve bilinen tekniklerdir. Ancak, OAD için bir tedavi algoritması oluşturmak amacıyla daha geniş örneklem büyüklüğüne sahip ileri klinik çalışmalara ihtiyaç vardır.

**Anahtar Kelimeler:** Oroantral açıklık, oroantral fistül, bukkal kaydırma flebi, bukkal yağ pedi, press-fit

### INTRODUCTION

The roots of upper molar teeth can be close to the sinuses, risking their perforation during extraction, known as oroantral communication (OAC). Factors like cyst removal, trauma, etc., can also cause OAC. Delayed treatment may lead to sinusitis in about 50% of patients within 48 hours and in 90% after two weeks.<sup>1</sup> Thus, prompt management within 24 hours is advised for such communications. If epithelization occurs, oroantral fistulas (OAF) may develop, which are more challenging to manage compared to OAC. Success rates drop from 95% for OAC to potentially 67% for OAF, as per the literature.<sup>2</sup>

Geliş Tarihi/Received 01.07.2024  
Kabul Tarihi/Accepted 25.09.2024  
Yayın Tarihi/Publication Date 15.04.2024

Sorumlu Yazar/Corresponding author:

İlgin Ari

E-mail: ariilgin@gmail.com

Cite this article: Ari I, Adiloğlu S, Aktaş A, Kızılkaya AE. Assessment of Treatment Approaches for Oroantral Communication and Fistulas. *Curr Res Dent Sci*.  
doi 10.17567/currresdentsci.1507220



Content of this journal is licensed under a Creative Commons Attribution-NonCommercial-NoDerivatives 4.0 International License

Several treatment techniques are available for managing oroantral defects, including buccal advancement flaps, platelet-rich fibrin (PRF) applications, 8 ligature suture, buccal fat pad (BFP) flap, palatal advancement flap or block grafts.<sup>3-6</sup> Despite the various techniques, the ideal choice of treatment method is not clearly defined. Considerations for managing oroantral fistulas, as indicated by Daif et al,<sup>7</sup> include assessing factors such as the location and size of the defect, its relation to adjacent teeth, the height of the alveolar ridge, the duration of the oroantral fistula presence of sinus infection, and patient's medical status. Abuabara et al<sup>9</sup> observed that perforations less than 3 mm in the sinus membrane can heal spontaneously. Another clinical study suggested that perforations less than 5 mm may also heal spontaneously, but perforations larger than 5 mm may require surgical interventions.<sup>9</sup> According to the literature, oroantral defects larger than 5 mm are generally managed with well-vascularized soft tissue flaps or hard tissue grafts.

Buccal advancement flaps (BAF) are a treatment option for OAD. With its ample base, this flap enjoys excellent blood supply. Its substantial tissue volume allows for tension-free closure of the defect, ensuring adequate blood flow. However, literature on the success rates of BAF in managing OAD is contentious. In some instances, particularly with large OAD, BAF applications may prove insufficient.<sup>10</sup> In such cases, the buccal fat pad (BFP) presents itself as a viable option. This flap, essentially a preformed local soft tissue flap, is favored for its good nutrition, easy accessibility, stem cell content, and straightforward application. However, despite its advantages, the BFP flap lacks osteogenic properties, poses a risk of fat necrosis, and might necessitate a second surgery for implant placement.<sup>11</sup> In cases where future implant rehabilitation necessitates hard tissue augmentation, a commonly employed approach involves closing the area with block autografts. Donor sites within oral cavity, such as maxillary tuberosity, ramus, and symphysis, are often utilized for these applications. While press-fit technique stabilization is feasible for these block grafts, it may not always be attainable, thus requiring the use of plates and screws for primary stabilization.<sup>12</sup> Over the years, various options such as prefabricated membranes, auricular cartilage or distant flaps have been considered for managing large oroantral defects (OAD).<sup>6,13</sup> However, recently, there are few studies that investigate treatment options and their post-operative follow-ups for large OAD. The aim of this paper is to examine and compare the treatment of large size OADs and their follow-ups.

## METHODS

This study was approved by Hacettepe University Health Sciences Research Ethics Committee with GO 23/495 protocol number. The patients who referred our clinic between 2017 and 2023 suffering from OAF and the cases which was occurred OAC during oral procedure was larger than 5mm size were included in the study. The patients who have OAF, which was postnasal derange, symptoms of acute sinusitis and hyperemia around the fistula was started antibiotic (Amoxicillin 875 mg + clavulanic acid 125 mg, 2x1, Glaxo Wellcome Production Mayenne, France) 2 weeks before the surgery. Informed consent was obtained from all patients. The patients who have metabolic bone diseases, history of taken radiotherapy to head and neck region, have any metastatic bone diseases were excluded from the study. The size, type and cause of OAD, treatment method and the patient's demographic data was recorded. Also, the edema and mouth opening measurements were obtained from preoperative and postoperative records at 3, 7, 10 days after surgery. Three lines were identified for edema measurements

as A-C (tragus – lateral commissure), A-D (tragus - soft tissue pogonion), B-E (lateral canthus – inferior point of the angulus). The records of VAS scale, analgesic requirement, soft tissue dehiscence was evaluated at 3, 7, 10 days during postoperative period. Due to measurement of defects, CBCT (Cone Beam Computerized Tomography) was taken from the OAF patients, in case of OAC size of defects were calculated with Castroviejo caliper during procedure. Patients who have missing information were excluded from the study. Informed consent forms were obtained from the patients before all surgical procedures.

### 2.1 Statistical Analysis

The suitability of quantitative variables for normal distribution was assessed using the Kolmogorov-Smirnov test. Variance homogeneity was examined with the Levene test. For non-normally distributed variables, independent two groups were compared using the Mann-Whitney U test. Chi-square analysis was performed to examine categorical variables. Parametric assumptions were met for comparisons involving more than two groups, and analysis of variance (ANOVA) was conducted. When parametric assumptions were not met in these cases, the Kruskal-Wallis test was utilized. The two-way ANOVA test was applied for repeated measurements, evaluating group and time interactions simultaneously. In instances of significant differences observed in comparisons involving more than two groups, post hoc tests were conducted to further investigate the source of these differences. All p-values were calculated as two-tailed, with the significance level set at 5% ( $p < 0.05$ ). IBM SPSS 26 was used for the statistical analysis.

## RESULTS

Between 2017 and 2023, twenty-three patients (12 female, 11 male) received treatment for OAD at XXXXXXXX University Faculty of Dentistry the Department of Oral and Maxillofacial Surgery. The average age of the patients was  $39.3 \pm 16.9$  years (ranging from 15 to 69 years) and the average follow up time was  $8.8 \pm 3.2$  months (ranging from 2 to 50 months) Nine patients underwent treatment with BAF, 10 patients with BFP, and 4 patients with the press-fit technique. Statistical analysis revealed no significant differences between treatment methods according to systemic conditions ( $p=0.772$ ), age ( $p=0.215$ ), and gender ( $p=0.648$ ) of the patients. Demographic data are detailed in Table 1 as well as the characteristics of observed OACs and OAFs.

A total of 8 OAF and 15 OAC were diagnosed. No significant difference was observed between groups ( $p=0.254$ ) in the distribution of OACs and OAFs. The mean defect size of all patients at the bone measured as  $8.4 \pm 3.1$  mm mesiodistally and  $8.9 \pm 3.6$  mm buccolingually. The mean defect size was 7x8mm in BAF group, 7.3x6.7mm in press-fit group and 11x11.3mm in BFP group. Although the mean defect size was observed larger in BFP group, there wasn't observed statically significant difference between groups in the terms of defect size ( $p=0.131$  mesiodistally,  $p=0.373$  buccolingually) (Figure 1). The largest defect size (18.2-14mm) was observed in a patient (Number 12), who had an OAF due to a secondary infection at the site where a plate and screw had been inserted after trauma occurred 10 years ago. (Figure 2-A) This patient was undergoing chemotherapy for acute lymphoblastic leukemia. The OAF manifested at the trauma site one month later, after chemotherapy had started. Considering the defect's size (Figure 2-B), soft tissue fistulation, and the patient's medical condition, BFP (Figure 2-C) was chosen instead of using a bony graft. The healing process was uneventful (Figure 2-D).

Even though, the primary cause of OADs was identified as tooth extraction which was seen 15 patients (65.2%), no significant differences

**Table 1.** Descriptive statistics of age, gender of patients, treatment, success status, type and the size of defects.

Patients Number	Age/Gender	OAC or OAF	Cause of OAC/OAF	Size of defect (mm) (MD-BP)	Treatment	Success Status
Patient 1	37/M	OAC	Tooth extraction	5-4	BAF	S
Patient 2	51/F	OAC	Tooth extraction	5-5	BAF	S
Patient 3	69/F	OAC	Tooth extraction	7.8-13	BAF	S
Patient 4	62/M	OAC	Cyst enucleation	9-8	BAF	S
Patient 5	16/M	OAC	Cyst enucleation	8.9-11	BAF	S
Patient 6	25/F	OAC	Tooth extraction	6-10	BAF	S
Patient 7	36/F	OAC	Tooth extraction	5-6	BAF	S
Patient 8	25/F	OAF	Cyst enucleation	10-6.5	BAF	S
Patient 9	39/F	OAF	Tooth extraction	7.8-11.5	BAF	S
Patient 10	38/M	OAF	Tooth extraction	7.4-12	BFP	US
Patient 11	58/F	OAC	Cyst enucleation	10-13.3	BFP	S
Patient 12	51/M	OAF	Seconder infection	18.2-14	BFP	S
Patient 13	18/M	OAF	Tooth extraction	8.6-7	BFP	S
Patient 14	37/F	OAC	Tooth extraction	13-16	BFP	S
Patient 15	19/M	OAC	Odontoma enucleation	10.5-14.5	BFP	S
Patient 16	40/M	OAC	Tooth extraction	10-9.1	BFP	S
Patient 17	69/M	OAF	Tooth extraction	11-5	BFP	S
Patient 18	15/F	OAC	Tooth extraction	5.1-6.9	BFP	S
Patient 19	30/F	OAC	Tooth extraction	5-4	BFP	S
Patient 20	50/F	OAC	Fail of implant	9-8	Press fit	S
Patient 21	62/M	OAF	Tooth extraction	5-5	Press fit	S
Patient 22	25/M	OAC	Sinus lift	9-8	Press fit	S
Patient 23	32/F	OAF	Tooth extraction	6.5-6	Press fit	S

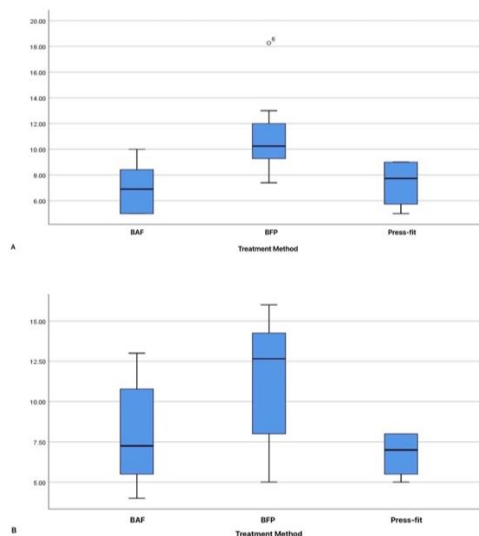
**Abbreviations;** MD: Mesiodistal, BP: Buccolingual, F: Female, M: Male, OAC: Oroantral communication, OAF: Oroantral fistula, BAF: Buccal advancement flap, BFP: Buccal fat pad, S: Successful US: Unsuccessful

**Table 2:** Comparment of treatment methods according to the parameter changes during the time.

Parameters	BAF (The Mean Values)				BFP (The Mean Values)				Press-fit (The Mean Values)				Significance (p values)	Partial Eta Squared
	Pre-op	3	7	10	Pre-op	3	7	10	Pre-op	3	7	10		
A-C Line (cm)	11.2	11.6	11.1	10.9	11.2	12.2	11.3	11.26	11.3	12	11.5	10.8	0.679	0.038
A-D Line (cm)	15.1	15.7	15	14.8	15.5	16.5	15.7	15.6	13.9	15.1	15.2	14.9	0.162	0.166
B-E Line (cm)	10.3	10.6	10.1	10	10.7	11.7	11	10.8	10.1	11	10.8	10.2	0.424	0.082
Mouth opening (mm)	44.1	39.1	43.2	44.5	43.8	32.2	38.6	41.6	44.2	34.2	45.8	44.5	0.509	0.076
VAS Scale	-	3.2	1.1	0.3	-	4.2	1.5	0.7	-	2.5	0.8	1.1	0.356	0.098
Analgesic Requirement	-	3.9	2.2	1.3	-	3.3	3.3	2.1	-	1.6	1.9	1.2	0.412	0.085

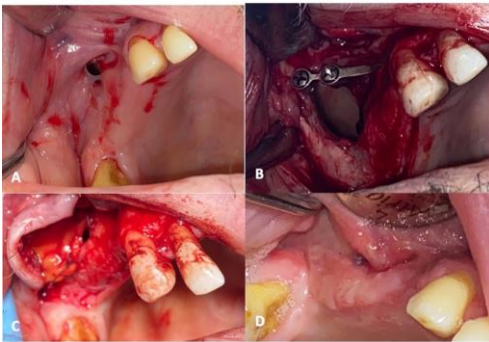
**Abbreviations;** BAF: Buccal advancement flap, BFP: Buccal fat pad, Pre-op: Pre-operative, A-C: tragus – lateral commissure, A-D: tragus - soft tissue pogonion, B-E: lateral canthus – inferior point of the angulus.

between treatment methods according to the cause of OAD between the treatment groups ( $p=0.133$ ). The initial treatment was failed at only one patient (number 10) presented with an OAF after tooth extraction (Figure 3-A). The OAF was initially covered with BFP (Figure 3-B) after a Caldwell-Luc procedure. Although no soft tissue dehiscence was observed at the 3-day follow-up, the OAF fully reopened at the 7-day (Figure 3-C), attributed to probably patient's smoking habit (Figure 3-C). For the second surgery, fixation of a chin graft was planned (Figure 3-E). The region was irrigated with a rifampicin-saline solution (1:1) for two weeks once a day. The chin graft was applied to the region and stabilized with a screw. (Figure 3-D, 3-F) Despite soft tissue dehiscence observed throughout the graft in follow-ups, the graft wasn't removed from the region and used as plug because of resolving the patient's complaints such as fluid coming from the nose, closing oroantral passage, post-nasal drainage, or halitosis by the 10th day. The patient was checked weekly, and at-home irrigation with saline solution was recommended. After two months, the graft was removed, and the region was observed as covered with healthy soft tissue which was regenerated by itself. The healing process remained uneventful during the 8-month follow-up.

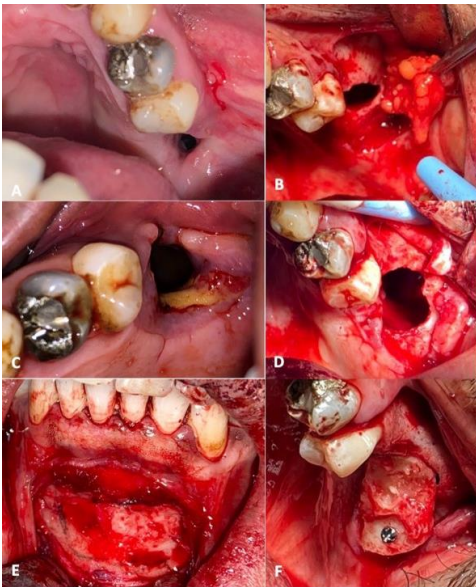


**Figure 1: A)** The mesiodistal defect size measurements of treatment groups **B)** The buccolingual defect size measurements of treatment groups. **Abbreviations;** BAF: Buccal advancement flap, BFP: Buccal fat pad



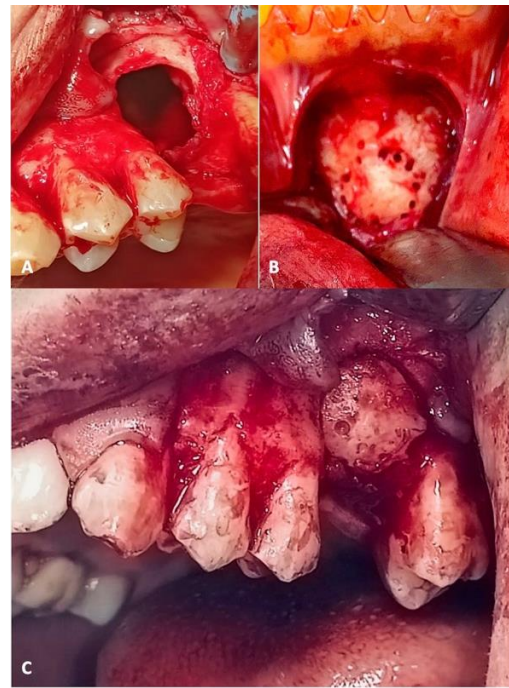


**Figure 2:** A) The preoperative view of OAF (Oroantral fistula) at the patient. B) Intraoperative view of infected maxillary sinus cavity. C) BFP (Buccal fat pad) application after Caldwell-Luc procedure. D) The healing of the OAF area after 2 weeks from the surgery



**Figure 3:** A) The preoperative view of OAF (Oroantral fistula). B) The intraoperative view of OAF after Caldwell-Luc procedure reflection of BFP (Buccal fat pad). C) The fall of BFP application at 7<sup>th</sup> day. D) The view of OAF during intraoperative process at second surgery. E) The preparation of donor site at symphysis area. F) The fixation of symphysis graft to the recipient side

At one of the patients, OAD occurred as a result of an implant explantation dealing with the failure of the trans-alveolar sinus lift approach. After the explantation, the press-fit technique was applied to the area, and the healing period was uneventful. Five OAC were observed due to the enucleation of odontogenic lesions. Two of them were managed with Buccal Fat Pad (BFP), and three were treated with BAF. No complication was indicated during the follow-ups. In one patient (Number 22), an OAF developed after an unsuccessful lateral window approach sinus augmentation. A modified "Cul-De-Sac" approach was performed due to a large-sized sinus membrane perforation during augmentation. However, the patient presented to our clinic with symptoms of OAF two months later. The press-fit technique was planned, and a Caldwell-Luc procedure was performed (Figure 4-A). The symphysis region was reflected, and although the defect measured as 9x8 mm, no trephine burr larger than 9mm in diameter was available in our tools. Measurements were conducted with a Castroviejo caliper, and the donor site was prepared with a round burr (Figure 4-B). The graft was placed using the press-fit technique with primary stability (Figure 4-C), and no problems occurred during the 4-month follow-up.



**Figure 4:** A) Intraoperative view of OAF (Oroantral fistula) after Caldwell-Luc application. B) The graft harvesting from the symphysis area with round burr. C) The view of recipient side with press-fitted graft.

In clinical assessment it was observed that in BFP and press-fit groups, edema and trismus increased more than BAF group at 3<sup>rd</sup> day follow-up, however, no statistically significant differences were observed between groups at any timepoint according to parameters as A-C ( $p = 0.679$ , partial  $\eta^2 = 0.038$ ), A-D ( $p = 0.162$ , partial  $\eta^2 = 0.166$ ), B-E ( $p = 0.424$ , partial  $\eta^2 = 0.082$ ) lines, mouth opening ( $p = 0.509$ , partial  $\eta^2 = 0.076$ ). In press-fit groups VAS scale and analgesic requirement was lower than BFP and BAF, nevertheless there wasn't observed any difference between groups in the terms of VAS Scale ( $p = 0.356$ , partial  $\eta^2 = 0.098$ ) and analgesic requirements ( $p = 0.412$ , partial  $\eta^2 = 0.085$ ) at any point in time (Table 2).

## DISCUSSION

Managing oroantral defects (OAD) in larger size defects can pose challenges, and a definitive treatment algorithm has not been established. Due to this, various treatment methods are being evaluated in the literature. In this presented study, investigation of trismus, swelling, pain, success rates, and analgesic requirements of BAF, BFP, and press-fit techniques for the closure of OAD were aimed. There were no significant differences between treatment methods in terms of any parameters.

As literature suggests that the first 24-48 hours are crucial for OAC management, the decision on the treatment protocol depends on factors such as patients' medical status, size and location of the communication, inflammatory status of the maxillary sinus, and prosthetic rehabilitation options during the postoperative period.<sup>2</sup> In literature it is discussed that OACs smaller than 5mm may heal spontaneously, but larger ones may require advanced methods. On the other hand Buccal Advancement Flap (BAF) is a commonly technique used due to its simplicity, reliability, and versatility, with promising success rates for OAC closure, however, literature often recommends BAF for less than 5mm communications.<sup>4,6,14</sup> On the contrary, there are studies taken promising results at OAD with larger than 5mm by

application of BAF.<sup>15</sup> In our study, BAF was applied to 9 OADs with a mean defect size of 7x8mm, and the healing process was uneventful at every patient. This difference might be associated with the type of defects, as most patients in the BAF group had OACs, and the defects were covered immediately after opening. Only one patient had OAF, and BAF was performed for treatment. Preoperative antibiotic treatment was given for two weeks to prevent complications, considering the potential risks of postoperative infection. Additionally, during the closure process, advanced flap without tension was performed and the tissues were kept as far as possible from the OAD margins in the anastomosis area.

BFP and press-fit techniques are considered reliable options for large-size OAD.<sup>16,17</sup> The press-fit technique, widely used for implant applications in OAD since 2003, has shown a very promising success rates.<sup>3,18</sup> Er et al reported that treatment of 10 patients with OACs or OAFs was showed 100% success rate.<sup>12</sup> Watzak et al reported 80.9% success rate for OAF closure. The authors indicated that the use of monocortical bone grafts harvested at intraoral donor sites is a safe and easy technique for repairing defects of the maxilla, especially OAFs in need of secondary closure.<sup>12,19</sup> In our study, the closure rate for OAD was 100%, and no complications occurred during the follow-up periods. While press-fit is an optimal approach for OAD reconstruction, several parameters should be evaluated such as residual alveolar bone height, adjacent teeth, and adaptation of the graft to the recipient site. One patient underwent active chemotherapy in our study had the largest OAD. In this case, the press-fit technique wasn't preferred due to the patient's medical status. As sufficient donor tissue couldn't be obtained from intraoral sites, the well-nourished BFP flap was applied for preventing the risk of potential graft failure, with uneventful healing. Descriptive statistics in our study did not reveal any significant difference between defect sizes at different treatment groups. However, the mean defect size was lower in the BAF, and press-fit groups compared with BFP group. This difference could be attributed to BFP's robust blood supply and the lack of a need for a substantial donor site.

BFP is a vascularized and easily accessible flap for treating OAD. However, the potential for fat pad necrosis can lead to severe postoperative complications.<sup>20</sup> Park et al. investigated the effectiveness of BFP for managing OAF and reported a 92% success rate. The authors indicated that oroantral fistula closure using a pedicled buccal fat pad was found to have a high success rate.<sup>11</sup> Another clinical study applied the BFP with endoscopic approach at 19 patients with OAF, and the postoperative process was uneventful during the one-year follow-up. The authors declined that BFP flap combination with endoscopic drainage of the maxillary sinus through the middle meatus is an effective, easy, and simple method with high success rate for closure of OAF.<sup>21</sup> Numerous studies suggest that BFP is a meritorious option for OADs.<sup>20,22</sup> In our study, the success rate of BFP was found 90%. Fistulation occurred in only one patient due to heavy smoking, and a second surgery was performed with symphysis graft fixation. Although soft tissue dehiscence occurred, the graft served as an air-tag plug for OAF, and closure was achieved after 2 months by secondary epitalization. Various OAD treatment methods exist, but the key factor in the treatment philosophy is to create an air-tag plug between the antrum and the oral cavity. This plug can consist of hard tissue, soft tissue, a stemmed flap, or even synthetic material.

In literature there is inadequate knowledge about clinical outcomes as pain score, swelling, mouth opening and need of analgesic in OAD closure. Shukla et al was investigated clinical outcomes as trismus, pain, swelling and mouth opening (MO) of BAF and BFP for closure of OAF. They indicated that BAF groups was showed less pain and swelling and

greater MO than BFP group. According to their results BFP could better option for closure of OAF, despite of its more morbidity compared to BAF [10]. Nezafati et al compared BAF and BFP for postoperative clinical outcomes and the results are observed as BAF was greater than BFP for clinical outcomes same as Shukla et al.<sup>10,23</sup> Another clinical study BFP was compared with sandwich graft technique for closure of OAD. According to their results there wasn't observed any significant difference between groups in the terms of pain and swelling.<sup>24</sup> The difference between treatment groups in the terms of swelling, trismus, VAS scale and analgesic requirement wasn't observed in this study. The difference at BAF outcomes between literature and our study may be attributed to stress-free closure and excessive periosteum relaxation of the flap to provide tissue anastomosis away from the fistula site. Although there was observed insignificant difference in terms analgesic requirement and pain score between treatment groups, in press fit group analgesic requirement and pain score was lower than other groups. It may associate with less time consumed during the intraoperative period or our small sample sizes.

## CONCLUSION

In order to perform a successful OAD closure and choose the right treatment method, it is critical to evaluate the size and localization of the OAD, the infectious status of the maxillary sinus, the patient's medical condition and habits, the need for hard tissue reconstruction in the future and gaining air-tag plug between the antrum and oral cavity is the most important result for these patients. BAF, BFP and press-fit are reliable and trusted techniques for OAD treatment, however, further clinical studies with larger sample sizes are needed for defining correct and detailed algorithm for OAD treatment protocol.

**Etik Komite Onayı:** Bu çalışma Hacettepe Üniversitesi Sağlık Bilimleri Araştırmaları Etik Kurulu tarafından GO 23/495 protokol numarası ile onaylandı.

**Hasta Onamı:** Tüm hastalardan bilgilendirilmiş onam formları alındı.

**Hakem Değerlendirmesi:** Dış bağımsız.

**Yazar Katkıları:** Fikir – IA; Tasarım – IA, SA; Denetim – AA; Kaynaklar – AEK; Malzemeler – IA,AEK; Veri Toplama ve/veya İşleme – IA,AEK; Analiz ve/veya Yorum – IA,SA; Literatür Taraması – IA; Makaleyi Yazan – IA,SA; Eleştirel İnceleme – AA; Diğer – SA.

**Çıkar Çatışması:** Yazarların tamamı çıkar çatışması olmadığını belirtmişlerdir.

**Finansal Destek:** Yazarlar, bu çalışma için finansal destek almadığını beyan etmiştir.

**Ethics Committee Approval:** This study was approved by Hacettepe University Health Sciences Research Ethics Committee with GO 23/495 protocol number.

**Informed Consent:** The informed consent forms were obtained from all patients.

**Peer-review:** Externally peer-reviewed.

**Author Contributions:** Concept – IA; Design – IA, SA; Supervision – AA; Resources – AEK; Materials – IA,AEK; Data Collection and/or Processing – IA,AEK; Analysis and/or Interpretation – IA,SA; Literature Search – IA; Writing Manuscript – IA,SA; Critical Review – AA; Other – SA

**Conflict of Interest:** All authors stated that there is no conflict of interest.

**Financial Disclosure:** The authors declared that this study has received no financial support.

---

## REFERENCES

1. Wassmund M. Lehrbuch der praktischen Chirurgie des Mundes und der Kiefer. (No Title). 1935.
2. Anavi Y, Gal G, Silfen R, Calderon S. Palatal rotation-advancement flap for delayed repair of oroantral fistula: a retrospective evaluation of 63 cases. *Oral Surg Oral Med Oral Pathol Oral Radiol Endodont.* 2003;96:527-34.
3. Haas R, Watzak G, Baron M, Tepper G, Mailath G, Watzek G. A preliminary study of monocortical bone grafts for oroantral fistula closure. *Oral Surg Oral Med Oral Pathol Oral Radiol Endodont.* 2003;96:263-6.
4. Hunger S, Krennmair S, Krennmair G, Otto S, Postl L, Nadalini D-M. Platelet-rich fibrin vs. buccal advancement flap for closure of oroantral communications: a prospective clinical study. *Clin Oral Invest.* 2023;27:2713-24.
5. Kwon M-S, Lee B-S, Choi B-J, Lee J-W, Ohe J-Y, Jung J-H, et al. Closure of oroantral fistula: a review of local flap techniques. *J Korean Assoc Oral Maxillofac Surg.* 2020;46:58.
6. Parvini P, Obreja K, Begic A, Schwarz F, Becker J, Sader R, Salti L. Decision-making in closure of oroantral communication and fistula. *International journal of implant dentistry.* 2019;5:1-11.
7. Daif ET. Long-term effectiveness of the pedicled buccal fat pad in the closure of a large oroantral fistula. *J Oral Maxillofac Surg.* 2016;74:1718-22.
8. Abuabara A, Cortez A, Passeri L, De Moraes M, Moreira R. Evaluation of different treatments for oroantral/oronasal communications: experience of 112 cases. *Int J Oral Maxillofac Surg.* 2006;35:155-8.
9. Mårtensson G. Operative method in fistulas to the maxillary sinus. *Acta Oto-Laryngol.* 1957;48:253-4.
10. Shukla B, Singh G, Mishra M, Das G, Singh A. Closure of oroantral fistula: Comparison between buccal fat pad and buccal advancement flap: A clinical study. *National Journal Maxillofac Surg.* 2021;12:404.
11. Park J, Chun B-d, Kim U-K, Choi N-R, Choi H-S, Hwang D-S. Versatility of the pedicled buccal fat pad flap for the management of oroantral fistula: a retrospective study of 25 cases. *Maxillofac Plastic Reconstruct Surg.* 2019;41:1-6.
12. Er N, Tuncer HY, Karaca Ç, Çopuroğlu S. Treatment of oroantral fistulas using bony press-fit technique. *J Oral Maxillofac Surg.* 2013;71:659-66.
13. Ram H, Makadia H, Mehta G, Mohammad S, Singh RK, Singh N, Singh G. Use of Auricular Cartilage for Closure of Oroantral Fistula: A Prospective Clinical Study. *J Maxillofac Oral Surg.* 2016;15:293-9.
14. Yalçın S, Öncü B, Emes Y, Atalay B, Aktaş İ. Surgical treatment of oroantral fistulas: a clinical study of 23 cases. *J Oral Maxillofac Surg.* 2011;69:333-9.
15. Hernando J, Gallego L, Junquera Gutiérrez LM, Villareal Renedo P. Oroantral communications: a retrospective analysis. 2010.
16. Visscher SH, van Minnen B, Bos RR. Closure of oroantral communications: a review of the literature. *J Oral Maxillofac Surg.* 2010;68:1384-91.
17. Bell, G., Howard, L., & Lamont, T. Clinical and radiographic assessment and restoration of maxillary sinus function in relation to oro-antral fistula closure: a systematic review. *Oral Surg Oral Med Oral Pathol Oral Radiol* 2022;134(4), 432-441.
18. Ahmed MS, Askar NA. Combined bony closure of oroantral fistula and sinus lift with mandibular bone grafts for subsequent dental implant placement. *Oral Surg Oral Med Oral Pathol Oral Radiol Endodont.* 2011;111:e8-e14.
19. Watzak G, Tepper G, Zechner W, Monov G, Busenlechner D, Watzek G. Bony press-fit closure of oro-antral fistulas: a technique for pre-sinus lift repair and secondary closure. *J Oral Maxillofac Surg.* 2005;63:1288-94.
20. Jain M, Ramesh C, Sankar K, Babu KL. Pedicled buccal fat pad in the management of oroantral fistula: a clinical study of 15 cases. *Int J Oral Maxillofac Surg.* 2012;41:1025-9.
21. Abdel-Aziz M, Fawaz M, Kamel M, Kamel A, Aljerais T. Closure of oroantral fistula with buccal fat pad flap and endoscopic drainage of the maxillary sinus. *J Craniofac Surg.* 2018;29:2153-5.
22. Pool C, Goyal N, Lighthall JG. Novel Use of the Buccal Fat Pad for Sinocutaneous Fistulae Closure and a Review of Reconstructive Options. *Ann Otol Rhinol Laryngol.* 2022;131:295-302.
23. Nezafati S, Vafaii A, Ghojzadeh M. Comparison of pedicled buccal fat pad flap with buccal flap for closure of oro-antral communication. *Int J Oral Maxillofac Surg.* 2012;41:624-8.
24. Pal U, Mohammad S, Singh R, Singh G, Malkunje LR. Buccal fat pad versus sandwich graft for treatment of oroantral defects: A comparison. *National J Maxillofac Surg.* 2010;1:6.