

Transhepatic endovascular portal vein embolization before hepatectomy

Hepatektomi öncesi transhepatik endovasküler portal ven embolizasyonu

Çetin Murat ALTAY¹, Osman Melih TOPCUOĞLU², Ayhan ALPAR³, Murat Bülent KÜÇÜKAY⁴, Fahrettin KÜÇÜKAY⁵, Tuncer TEMEL⁶

¹Department of Radiology, Karabük University Research and Training Hospital, Karabük

²Department of Interventional Radiology, Yeditepe University Faculty of Medicine, İstanbul

³Department of Radiology, Sancaktepe Regional Hospital, İstanbul

⁴Department of Internal Medicine, Lokman Hekim Hospital, Ankara

⁵Department of Interventional Radiology, ⁶Department of Gastroenterology, Eskişehir Osmangazi University, Faculty of Medicine Eskişehir

Background and Aims: To evaluate the safety and efficacy of transhepatic portal vein embolization with Embosphere, Gelfoam, and Amplatzer vascular plug II before extended hepatectomy in patients with metastatic liver disease. **Materials and Methods:** Between January 2008 and October 2014, patients with metastatic liver disease, who were treated with transhepatic endovascular portal vein embolization before extended hepatectomy to increase the future remnant liver volume, were retrospectively evaluated. Multidetector computed tomography was utilized before and after the hepatectomy to calculate the future remnant liver volume. Ipsilateral portal vein embolization was performed in all patients with a microspheric embolic agent (Embosphere, 700–900 µm), gelatin foam (Gelfoam), and Amplatzer vascular plug II. Primary outcome measures are the increase in the percentage of the future remnant liver volume, procedure-related mortality and morbidity, and both technical and clinical success rates. **Results:** Fourteen (78%) right portal vein and 4 (22%) left portal vein embolizations were performed in a total of 18 patients (12 men and 6 women) with a mean age of 48±10.1 years (range, 32 to 59 years). The mean increase in the future remnant liver volume at 6 weeks was 41.6±6.7% (range, 35% to 45%), which was sufficient for extended hepatectomy, and the clinical success rate was 100%. The technical success rate was 100%, and there was no procedure-related mortality. A self-limited subcapsular hematoma occurred in one patient (5%). There was no recanalization of embolized portal veins during follow-ups. **Conclusion:** Transhepatic portal vein embolization with Embosphere, Gelfoam, and Amplatzer vascular plug II before extended hepatectomy in patients with metastatic liver disease, is a safe and effective procedure.

Key words: Liver, portal vein, embolization, Embosphere, Gelfoam, Amplatzer vascular plug, hepatectomy

INTRODUCTION

Surgical resection is the most effective treatment option in patients with primary or secondary liver malignancies regarding long-term survival (1). However, insufficient future remnant liver (FRL) volume after hepatectomy is the

Giriş ve Amaç: Bu çalışmanın amacı, metastatik karaciğer hastalığında genişletilmiş hepatektomi öncesi transhepatik portal ven embolizasyonu için Embosphere, Gelfoam ve Amplatzer vascular plug II kullanımının etkinlik ve güvenilirliğini araştırmaktır. **Gereç ve Yöntem:** Ocak 2008 ile Ekim 2014 tarihleri arasında, gelecekteki remnant karaciğer hacmini artırmak amacıyla, genişletilmiş hepatektomiden önce transhepatik endovasküler portal ven embolizasyonu yapılan metastatik karaciğer hastalığı olan hastalar, geriye dönük değerlendirildi. Gelecekteki remnant karaciğer hacmini hesaplamak için hepatektomiden önce ve sonra çok detektörlü bilgisayarlı tomografi görüntüleri kullanıldı. Tüm hastalarda ipsilateral portal ven embolizasyonu, mikrosferik embolik ajan (Embosphere, 700-900 µm), jelatin köpük (Gelfoam) ve Amplatzer vascular plug II kullanılarak yapıldı. Primer sonuç ölçütleri, gelecekteki remnant karaciğer hacminin yüzdeler artışı, prosedüre bağlı mortalite ve morbidite, teknik ve klinik başarı oranları olarak belirlendi. **Bulgular:** Ortalama yaşı 48±10.1 yıl (dağılım 32-59 yıl) olan toplamda 18 hastanın (12 erkek ve 6 kadın), 14'ünde (%78) sağ portal ven ve 4'ünde (%22) sol portal ven transhepatik yaklaşımla embolize edildi. Gelecekteki remnant karaciğer hacminde 6 haftada ortalama artış oranı %41.6±6.7 (dağılım %35-45) olup genişletilmiş hepatektomi için yeterli idi ve klinik başarı oranı %100, teknik başarı oranı %100 idi ve prosedüre bağlı mortalite yoktu. Bir hastada karaciğerde kendini sınırlayan subkapsüler hematoma vardı (%5). Embolize edilen portal venlerde takip süresince rekanalizasyon olmadı. **Sonuç:** Metastatik karaciğer hastalığı olan hastalarda genişletilmiş hepatektomiden önce transhepatik portal ven embolizasyonu için Embosphere, Gelfoam ve Amplatzer vascular plug II güvenli ve etkili prosedürdür.

Anahtar kelimeler: Karaciğer, portal ven, embolizasyon, Embosfer, Gelfoam, Amplatzer vascular plug, hepatektomi

main limiting factor for surgical resection. An FRL volume of 25% is generally adequate in patients with normal liver, but an FRL volume below 40% increases mortality and morbidity in patients with cirrhotic liver (1).

Correspondence: Fahrettin KÜÇÜKAY

Department of Interventional Radiology, Osmangazi University, Faculty of Medicine Buyukdere mah. Meşelik kampüsü 22480 Eskişehir, TURKEY
E-mail: fkucukay@hotmail.com

Manuscript: 28.03.2017 • **Accepted:** 01.04.2017

DOI: 10.17941/agd.405337

Portal vein embolization (PVE) can be performed preoperatively to increase FRL volume. In 1920, atrophy of the ipsilateral liver lobe and compensatory hypertrophy of the contralateral liver lobe were first defined in a patient with portal vein thrombosis (2). From 1920 to the present, surgeries with high complication rates, such as portal vein ligation and transileocolic PVE, and interventional techniques, such as percutaneous transhepatic ipsilateral or contralateral PVE, have been developed (1,3-23). Many embolic agents, as gelfoam, glue, polyvinyl alcohol, microspheric particles, coils, Amplatzer vascular plug (AVPIL; AGA Medical, Plymouth, MN), or different combinations of these can be utilized for percutaneous PVE (3-23). The choice of embolic material is pivotal to get sufficient FRL volumes because recanalization of the embolized portal vein diminishes compensatory hypertrophy of the contralateral liver lobe (6). In the literature, many papers define different usage and combinations of embolic agents for PVE; however, a single worldwide robust embolic agent or combination of embolic materials has not yet been accepted worldwide.

In this retrospective study, we aimed to assess the safety and efficacy of transhepatic PVE with Embosphere (Biosphere Medical, Rockland, MA), Gelfoam (Gelfoam, Upjohn, Kalamazoo, MI), and AVPIL before extended hepatectomy in patients with metastatic liver disease.

MATERIALS and METHODS

This study is a single-center retrospective study. Formal consent and informed consent for all individual partic-

ipants included in the survey were obtained. Between January 2008 and October 2014, a total of 18 patients [12 men (66.6%) and 6 women (33.3%)] with a mean age of 48 ± 10.1 years (range, 32-59 years) and with metastatic liver disease (all colorectal cancer liver metastasis) who were treated by transhepatic endovascular PVE before extended hepatectomy, were included in the current study. All patients underwent contrast-enhanced multidetector computed tomography (MDCT) evaluation before both procedures and volume measurements were analyzed with the software. Fourteen (78%) right portal vein and 4 (22%) left portal vein embolizations were performed. There were no patients with cirrhotic liver.

Portal Vein Embolization

All patients tolerated the percutaneous PVE procedure well. The portal vein was punctured under ultrasound guidance in all patients, and ipsilateral portal vein was embolized with microspheric embolic agent (Embosphere, 700-900 μm), gelfoam, and AVPIL. Embosphere was administered until observing flow stasis in the peripheral branches of the portal vein. Thereafter, gelfoam was administered until flow stasis was seen in central parts of portal veins. Last, AVPIL was deployed according to the size of the ipsilateral portal vein (Figure 1). Contralateral PVE was not performed. In all patients, blood flow to the targeted portal vein was totally stopped.

Follow-Ups

Liver function tests and other biochemical data were assessed. All patients were evaluated with contrast-en-

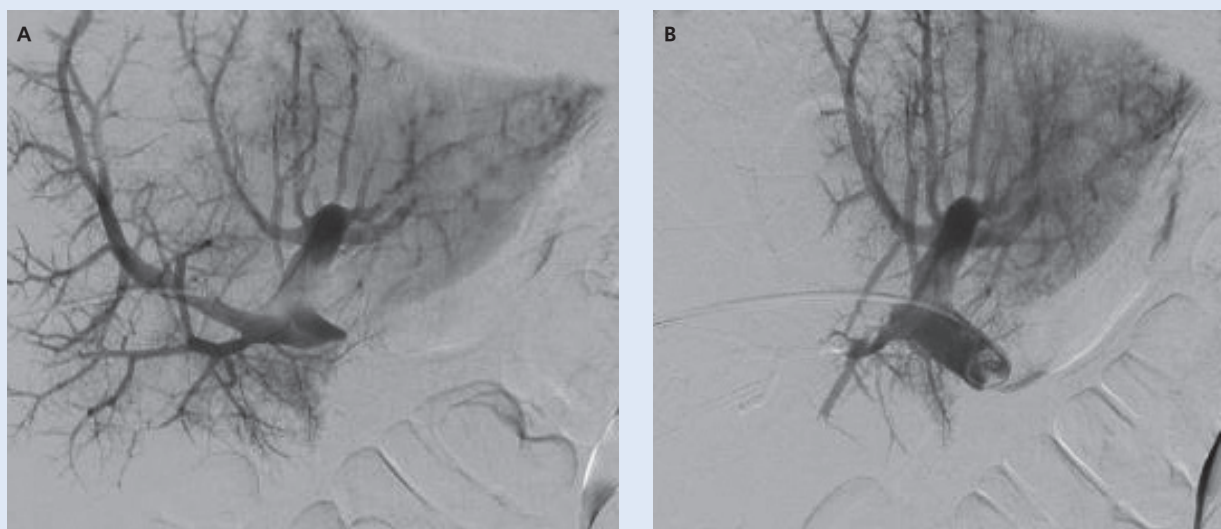


Figure 1. Digital subtraction portal venography images pre- (a) and post-embolization (b) of the portal vein.

hanced MDCT 6 weeks after PVE. Volume measurements were obtained using software. Increases in FRL volumes were discussed, and all patients underwent surgery.

RESULTS

The technical success rate was 100%. There was no procedure-related mortality. Only one patient (5%) had a self-limiting subcapsular hepatic hematoma. An intervention or blood transfusion was not necessary for this particular patient. There were not any other major complications.

The increase in FRL volumes was sufficient to prevent liver failure in the early post-operative period after hepatectomy in all patients. Adequate FRL volumes were achieved at 6 weeks, and the mean increase in FRL volume was $41.6 \pm 6.7\%$ (range, 35% to 45%). Recanalization was not detected in embolized target portal veins during follow-ups. In all patients, extended hepatectomy was performed for surgical treatment of hepatic metastases.

DISCUSSION

In the current study, we discussed the safety and efficacy of pre-operative PVE with a combination of Embosphere, Gelfoam, and AVPII before extended hepatectomy in patients with metastatic liver disease to increase FRL volume. Adequate FRL volume was achieved at 6 weeks, and extended hepatectomy was performed successfully in all patients. The procedure was very safe, and there was no detected liver failure after hepatectomy due to inadequate FRL volume.

The use of PVE has grown to become a standard procedure to raise remnant liver volume before extended hepatectomy (7,8). However; the exact mechanism of atrophy in the liver lobe in which the portal vein was embolized and the hypertrophy of the remnant liver lobe, are not clearly understood. Animal models and post-resection studies have revealed that growth factors stimulated liver regeneration (8). In particular, alterations in portal vein pressure provoke the secretion of nitrous oxide that causes the intrahepatic release of both hepatic growth factor and transforming growth factor alpha and eventually results in the hypertrophy of the remnant liver (8,9).

New embolic agents and embolization techniques are emerging to increase FRL volume with minimal side effects in a very short period of time. There are many embolic materials and different combinations of them for PVE. In a meta-analysis by van Lienden et al., (5) N-Butyl cyanoacrylate (NBCA; TruFill, Cordis, Miami Lakes, FL; Glubran 2, Gem, Viareggio, Lucca, Italy) was found to be the

most utilized embolic agent, and it caused more hypertrophy in the remnant liver compared with 18 different embolic agents. But NBCA can lead to both intense periportal inflammation and fibrosis, which complicate surgical resection (10). This critical disadvantage limits the usage of NBCA in PVE procedures. Another disadvantage of NBCA is non-target embolization of the remnant liver, especially in inexperienced hands. Thus, during the PVE procedure, also with liquid or particular embolic agents, placement of vascular plugs or occlusive balloons at the proximal part of the targeted portal vein is recommended (11,12).

AVP is a relatively new embolic material that is used successfully in the embolization of aneurysms, acquired or congenital arteriovenous malformations, and portal vein (13). Bent et al. (14) reported that AVP usage in conjunction with other embolic agents for PVE reduced the risk of non-target embolization and increased FRL volume as high as 68%. Also, in the current study, non-target embolization was prevented with AVP deployment. However, because AVP occludes the proximal part of the targeted portal vein, it does not hamper the intrahepatic porta-portal collateralization, which leads to decreased FRL volumes (14,15). This is the reason why it is necessary to embolize the portal vein distally also. For this purpose, Embosphere microspheres (700-900 μm) and Gelfoam were used in the current study. Better vascular penetration and fewer surgical hemorrhages are the main advantages of microspheric embolic agents over other embolic materials (16). Madoff et al. (17) found that spherical embolic particles as Embosphere microspheres were more effective than non-spherical embolic particles as polyvinyl alcohol regarding the increase in the amount of FRL volume. Embosphere microspheres are small- (40-120 μm) or large-sized (700-900 μm) particles and the latter were shown to cause less inflammation (18).

Gelfoam is an inexpensive, safe, and effective temporary embolic agent that has already been used for uterine artery embolization for a long time (19). In addition, Gelfoam can easily be injected into the vessel and absorb the fluid within it. So, it can be utilized for the embolization of large portal vein branches (20). However, usage of Gelfoam solely may increase the risk of recanalization, which in the end can cause decreased remnant liver hypertrophy. In other words, Gelfoam can preclude recanalization only when used in combination with permanent embolic agents and vascular plugs (21). To produce a sufficient FRL volume increase, the ideal embolic agent must occlude the portal vein effectively without recanalization and complication rates must be low.

In the current study, we achieved a mean increase of $41.6\% \pm 6.7\%$ (range, 35% to 45%) in the FRL volume. In the literature, there were two comprehensive meta-analyses reporting FRL volume increases as 17.8%-69.4% and 16%-44%, respectively, in patients with PVE (1,5). The wide spectrum of the rise in FRL volumes was probably due to both different embolic materials and combinations used, experience level of interventionalists, coexistence of cirrhosis, and use of chemotherapeutic drugs before PVE. Cirrhosis reduces the amount of hypertrophy in the remnant liver (22). It was found that chemotherapeutic drugs, except those that were platinum-based, did not affect the percentage of liver hypertrophy; however, diabetes mellitus decreased the hypertrophy ratios (1,5,10). However, Giraudo et al. (23) demonstrated that cirrhosis and diabetes mellitus did not decrease the percentages of liver hypertrophy but increased the essential time interval to reach sufficient FRL volumes.

The technical success indicates the feasibility of percutaneous PVE and the clinical success indicates a sufficient increase in the FRL volume to perform hepatectomy after PVE. In a comprehensive meta-analysis, the technical and clinical success rates were found to be 99.3% and 96.1%, respectively (5). In the current study, both the technical and clinical success rates were 100%. The higher percentages of clinical success rates than those reported in literature might be attributed to having no patients with a cirrhotic liver. Another reason might be our small sample size. With a larger number of patients, both the technical and clinical success rates may approach those reported in the literature.

After PVE, some minor complications can be observed such as fever, increase in serum transaminase levels,

pain, ileus, nausea, or vomiting, and the incidence was reported to be 8.9%-14.9% (5,24). In contrast, major complications were rarer and biliary leakage, subcapsular hematoma, portal hypertension, non-target embolization, infection, abscess or transient liver failure might be observed (5,24). Procedure-related mortality in PVE was reported in only one study (23). Hemorrhage could be seen in the form of hemobilia, hemoperitoneum, or subcapsular hematoma, and the most frequent major complication in PVE occurred with an incidence of approximately 2%-4% (24). In our study, there was a self-limiting subcapsular hematoma in only one patient (5%). It was relatively higher compared with that reported in the literature; however, it might be acceptable because there was no need for intervention, blood transfusion, and no permanent morbidity occurred.

The current study had several limitations. First, the low number of patients restricted the statistical analysis. The retrospective design of the study, lack of randomization, and absence of a control group for comparison with other embolic materials were the other limitations. Finally, the patient population did not contain any individuals with cirrhotic liver. Despite all these limitations, the current valuable study was first to report the results of pre-operative percutaneous PVE with a combination of Embosphere, Gelfoam, and AVPII.

In conclusion, transhepatic PVE in combination with Embosphere, Gelfoam, and AVPII to increase the FRL volumes before extended hepatectomy in patients with metastatic liver disease was both a safe and effective procedure with excellent technical success and low complication rates.

*The authors have nothing to disclose.

REFERENCES

1. Abulkhir A, Limongelli P, Healey AJ, et al. Preoperative portal vein embolization for major liver resection: a meta-analysis. *Ann Surg* 2008;247:49-57.
2. Rous P, Larimore LD. Relation of the portal blood to liver maintenance: a demonstration of liver atrophy conditional on compensation. *J Exp Med* 1920;31:609-32.
3. Makuuchi M, Thai BL, Takayasu K, et al. Preoperative portal embolization to increase safety of major hepatectomy for hilar bile duct carcinoma: a preliminary report. *Surgery* 1990;107:521-7.
4. Schnitzbauer AA, Lang SA, Goessmann H, Nadalin S, et al. Right portal vein ligation combined with in situ splitting induces rapid left lateral liver lobe hypertrophy enabling 2-staged extended right hepatic resection in small-for-size settings. *Ann Surg* 2012;255:405-14.
5. van Lienden KP, van den Esschert JW, de Graaf W, et al. Portal vein embolization before liver resection: a systematic review. *Cardiovasc Intervent Radiol* 2013;36:25-34.
6. Geisel D, Malinowski M, Powerski MJ, et al. Improved hypertrophy of future remnant liver after portal vein embolization with plugs, coils and particles. *Cardiovasc Intervent Radiol* 2014;37:1251-8.
7. Abdalla EK, Adam R, Bilchik AJ, et al., Improving resectability of hepatic colorectal metastases: expert consensus statement. *Ann Surg Oncol* 2006;13:1271-80.
8. May BJ, Madoff DC. Portal vein embolization: rationale, technique, and current application. *Semin Intervent Radiol* 2012;29:81-9.
9. Huh CG, Factor VM, Sánchez A, et al. Hepatocyte growth factor/c-met signaling pathway is required for efficient liver regeneration and repair. *Proc Natl Acad Sci USA* 2004;101:4477-82.

10. de Baere T, Roche A, Elias D, et al. Preoperative portal vein embolization for extension of hepatectomy indications. *Hepatology* 1996;24:1386-91.
11. Jaber A, Toor SS, Rajan DK, et al. Comparison of clinical outcomes following glue versus polyvinyl alcohol portal vein embolization for hypertrophy of the future liver remnant prior to right hepatectomy. *J Vasc Interv Radiol* 2016;27:1897-905.
12. Di Stefano DR, de Baere T, Denys A, et al. Preoperative percutaneous portal vein embolization: evaluation of adverse events in 188 patients. *Radiology* 2005;234:625-30.
13. Wang W, Li H, Tam MD, et al. The amplatzer vascular plug: a review of the device and its clinical applications. *Cardiovasc Intervent Radiol* 2012;35:725-40.
14. Bent CL, Low D, Matson MB, et al. Portal vein embolization using a nitinol plug (Amplatzer vascular plug) in combination with histoacryl glue and iodinated oil: adequate hypertrophy with a reduced risk of nontarget embolization. *Cardiovasc Intervent Radiol* 2009;32:471-7.
15. Wilms C, Mueller L, Lenk C, et al. Comparative study of portal vein embolization versus portal vein ligation for induction of hypertrophy of the future liver remnant using a mini-pig model. *Ann Surg* 2008;247:825-34.
16. Laurent A. Microspheres and nonspherical particles for embolization. *Tech Vasc Interv Radiol* 2007;10:248-56.
17. Madoff DC, Abdalla EK, Gupta S, et al. Transhepatic ipsilateral right portal vein embolization extended to segment IV: improving hypertrophy and resection outcomes with spherical particles and coils. *J Vasc Interv Radiol* 2005;16:215-25.
18. Stampfl U, Stampfl S, Bellemann N, et al. Experimental liver embolization with four different spherical embolic materials: impact on inflammatory tissue and foreign body reaction. *Cardiovasc Interv Radiol* 2009;32:303-12.
19. Katsumori T, Kasahara T, Akazawa K. Long-term outcomes of uterine artery embolization using gelatin sponge particles alone for symptomatic fibroids. *AJR Am J Roentgenol* 2006;186:848-54.
20. Kim GC, Bae JH, Ryeom HK. Percutaneous preoperative portal vein embolization using a combination of gelatin sponge and histoacryl glue. *Acta Radiologica* 2009;50:1119-25.
21. Ko HK, Ko GY, Sung KB, et al. Portal vein embolization via percutaneous transsplenic access prior to major hepatectomy for patients with insufficient future liver remnant. *J Vasc Interv Radiol* 2016;27:981-6.
22. Aoki T, Kubota K. Preoperative portal vein embolization for hepatocellular carcinoma: consensus and controversy. *World J Hepatol* 2016;8:439-45.
23. Giraudo G, Greget M, Oussoultzoglou E, et al. Preoperative contralateral portal vein embolization before major hepatic resection is a safe and efficient procedure: a large single institution experience. *Surgery* 2008;143:476-82.
24. Ganeshan DM, Szklaruk J. Portal vein embolization: cross-sectional imaging of normal features and complications. *AJR Am J Roentgenol* 2012;199:1275-82.