



# Outcomes of Reverse Shoulder Arthroplasty in the Management of Proximal Humerus Fractures Following Failed Internal Fixation

Oguzhan Cicek<sup>1</sup>, Evren Karaali<sup>2</sup>, Osman Ciloglu<sup>2</sup>, Firat Seyfettinoglu<sup>2</sup>, Ozhan Pazarci<sup>2</sup>, Ahmet Can Ozsoy<sup>3</sup>

<sup>1</sup>Adana 5 Ocak State Hospital, Department of Orthopedics and Traumatology, Adana, Türkiye

<sup>2</sup>Adana City Training and Research Hospital, Department of Orthopedics and Traumatology, Adana, Türkiye

<sup>3</sup>İskenderun State Hospital, Department of Orthopedics and Traumatology, Hatay, Türkiye

Content of this journal is licensed under a Creative Commons Attribution-NonCommercial-NonDerivatives 4.0 International License.



## Abstract

**Aim:** This research aims to assess the clinical and functional outcomes of reverse shoulder arthroplasty (RSA) in patients with proximal humerus fractures who underwent revision surgery following unsuccessful internal fixation. The influence of fracture classification and the timing of revision surgery on postoperative pain, range of motion (ROM), and functional outcomes was also evaluated.

**Material and Method:** A retrospective analysis was performed on patients aged 65 years or older who sustained fractures due to low-energy trauma, such as simple falls, and underwent RSA due to failed internal fixation of proximal humerus fractures between 2017 and 2020. Patients with intraoperatively identified irreparable rotator cuff tears were included in the study. Functional outcomes were measured using the American Shoulder and Elbow Surgeons (ASES) score, Constant-Murley score, the Disabilities of the Arm, Shoulder, and Hand Score (QuickDASH), and Visual Analog Scale (VAS). Additionally, ROM, including flexion, abduction, internal rotation, and external rotation, was assessed. Statistical comparisons were conducted based on fracture classification (Neer Type 3 vs. Neer Type 4) and the interval between the initial fixation and revision surgery.

**Results:** Patients with Neer Type 4 fractures had poorer functional outcomes and higher pain levels than those with Neer Type 3 fractures. The VAS score was higher ( $3.2 \pm 1.8$  vs.  $0.9 \pm 0.9$ ), and the Constant-Murley score was lower ( $50.7 \pm 10.4$  vs.  $61.8 \pm 9.0$ ) in Neer Type 4 patients. Delayed revision surgery led to greater functional decline, increased pain, and restricted motion. Flexion ( $102.9 \pm 23.1^\circ$ ) and abduction ( $99.4 \pm 19.2^\circ$ ) were better preserved in Neer Type 3 fractures than in Neer Type 4 ( $80.0 \pm 22.8^\circ$  and  $73.3 \pm 22.5^\circ$ ). However, RSA effectively reduced postoperative pain (VAS  $1.5 \pm 1.5$ ) and improved functional scores (ASES  $59.0 \pm 21.3$ ).

**Conclusion:** RSA serves as a reliable reconstructive option for managing complications arising from unsuccessful surgical stabilization of proximal humerus fractures, especially in cases where the rotator cuff damage is beyond repair. Early revision surgery is linked to superior functional recovery, whereas delayed intervention may result in heightened pain and restricted shoulder movement.

**Keywords:** Reverse shoulder arthroplasty, proximal humerus fractures, failed internal fixation, functional outcomes, revision surgery

## INTRODUCTION

Proximal humerus fractures represent one of the most frequently encountered upper limb fractures, especially in older adults and individuals with osteoporosis (1). These fractures typically result from low-energy trauma, especially falls, and can lead to significant functional impairment if not treated appropriately in the early period (2). Treatment options include conservative management, internal fixation (plates, screws, or intramedullary nailing), and arthroplasty (3). However, complications following internal fixation, such as impaired bone healing, mechanical failure of the implant, and loss of vascular supply to the humeral head, may require revision surgery.

In patients requiring revision surgery following failed internal fixation, determining the appropriate surgical strategy is of critical importance. In proximal humerus fractures, particularly when rotator cuff integrity is compromised, traditional hemiarthroplasty has been associated with suboptimal outcomes (4). Unlike conventional prostheses, reverse shoulder arthroplasty (RSA) relies on the deltoid muscle as the primary driver of movement, leading to enhanced clinical outcomes and improved shoulder function in individuals with rotator cuff insufficiency (5). Consequently, RSA has gained prominence as a favored therapeutic approach, especially for individuals with extensive rotator cuff damage following unsuccessful internal fixation (6).

## CITATION

Cicek O, Karaali E, Ciloglu O, et al. Outcomes of Reverse Shoulder Arthroplasty in the Management of Proximal Humerus Fractures Following Failed Internal Fixation. *Med Records*. 2025;7(2):271-8. DOI:1037990/medr.1636986

Received: 10.02.2025 Accepted: 27.02.2025 Published: 05.03.2025

Corresponding Author: Oguzhan Cicek, Adana 5 Ocak State Hospital, Department of Orthopedics and Traumatology, Adana, Türkiye

E-mail: oguzhan.cicek21@hotmail.com

Various studies in the literature have analyzed the clinical effectiveness of RSA, whether implemented as an initial intervention or as a secondary procedure following proximal humerus fractures (7). These studies indicate that RSA is effective in pain control and facilitates a faster return to daily activities. Nevertheless, the effectiveness of RSA may differ based on variables such as patient age, fracture classification, timing of surgery, and the surgical approach utilized. Therefore, evaluating the sustained clinical effectiveness of RSA in cases of failed internal fixation is essential for informing clinical practice and enhancing patient management.

This research aims to assess the clinical and imaging outcomes of RSA in individuals with osteoporotic proximal humerus fractures who experienced complications following internal fixation and were diagnosed with irreparable rotator cuff tears during revision surgery. Furthermore, it explores the practicality and therapeutic efficacy of this surgical approach.

## **MATERIAL AND METHOD**

### **Study Design and Patient Selection**

This retrospective study was conducted at the Orthopedics and Traumatology Clinics of Adana City Training and Research Hospital between January 1, 2017, and November 30, 2020. The study included patients aged 65 years or older who sustained fractures due to low-energy trauma, such as simple falls, and underwent internal fixation for osteoporotic proximal humerus fractures. Patients who subsequently required revision surgery due to complications and had intraoperatively confirmed irreparable rotator cuff insufficiency, necessitating RSA, were evaluated. The selection of the 2017–2020 study period was based on the availability of a sufficiently large and homogenous patient cohort that met the inclusion criteria, ensuring comprehensive and standardized data collection. This timeframe also allowed for a minimum follow-up period of 24 months, enabling a thorough assessment of postoperative functional and clinical outcomes. Ethical approval for the study was obtained from the Adana City Training and Research Hospital Clinical Research Ethics Committee (Approval No. 1122, dated December 16, 2020).

### **Inclusion and Exclusion Criteria**

The inclusion criteria for the study consisted of patients aged 65 years or older who had sustained fractures due to low-energy trauma, such as simple falls, and had undergone internal fixation for osteoporotic proximal humerus fractures. Patients who developed complications necessitating revision surgery and were found to have irreparable rotator cuff tears during revision were included. Additionally, a minimum follow-up period of 24 months was required for inclusion in the study. Patients were excluded if they had a history of open fractures, previous septic arthritis or similar infections in the glenohumeral

joint, multiple fractures in the same extremity, or any neurological deficits. These criteria were established to ensure a homogeneous study population and enhance the reliability of the outcome assessments.

### **Sample Size and Power Analysis**

The sample size was determined based on a moderate effect size difference in parameter means, with an alpha significance level of 0.05 and a power of 95%, resulting in a total sample size of 19 participants. The power analysis was conducted using the PASS 13.0.6 software (NCSS, LLC, USA-2014). The margin of error was set at 5%, with a statistical power of 99% and an effect size of 0.68. During the study period, 28 patients who underwent RSA due to rotator cuff insufficiency following failed internal fixation were identified. After applying exclusion criteria, five patients were excluded, and the final analysis was completed with 23 patients.

### **Surgical Procedure**

All primary and revision procedures were conducted by a single surgical team utilizing the deltopectoral approach. In the primary procedure, patients underwent internal fixation with proximal humerus plates or screws. During revision surgery, patients were placed in the supine position under general anesthesia, and a deltopectoral incision was used for surgical exploration. After careful removal of internal fixation materials, the proximal humerus was assessed, and RSA was performed in cases where the rotator cuff tear was deemed irreparable. This determination was made intraoperatively based on the extent of tendon retraction and its mobilization capacity, as well as the presence of extensive scar tissue preventing reapproximation of the torn edges. Additionally, cases where the deltoid muscle was unable to develop a functional compensatory mechanism were also considered unsuitable for rotator cuff repair, necessitating RSA. Following glenoid preparation and debridement, appropriate prosthetic components were implanted, ensuring stability before closing the joint capsule. In the postoperative period, patients were immobilized with a shoulder sling, and early passive range of motion (ROM) exercises were initiated. The rehabilitation process was individually tailored to optimize functional recovery.

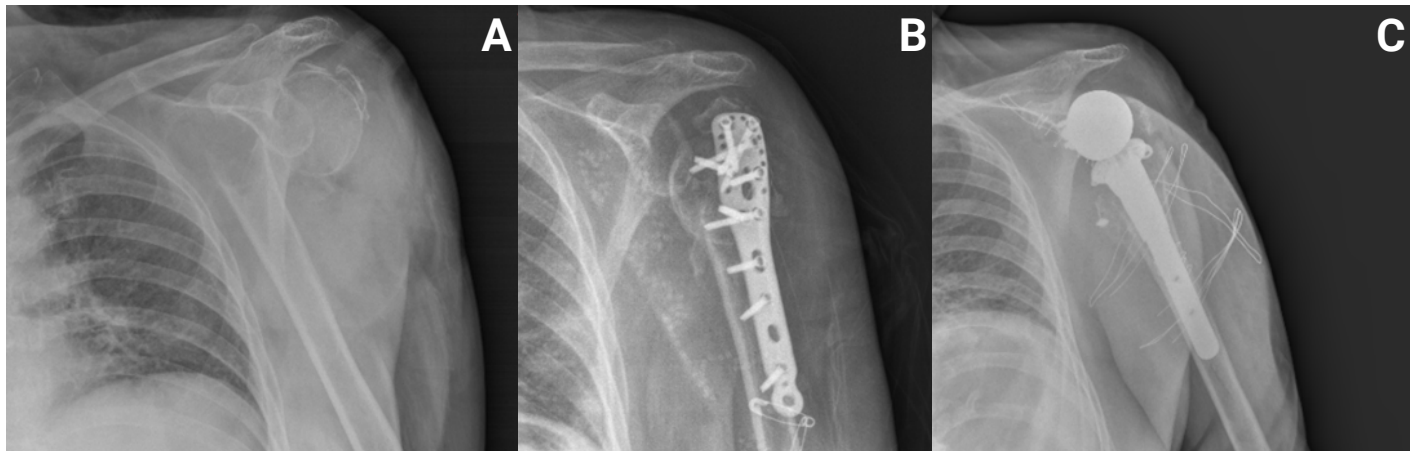
### **Functional and Clinical Assessment**

Postoperatively, patients included in the study were evaluated in terms of functional and clinical outcomes. Functional assessment was conducted using the American Shoulder and Elbow Surgeons (ASES) score, Constant-Murley score, and the Disabilities of the Arm, Shoulder, and Hand Score (QuickDASH). Pain levels were measured using the Visual Analog Scale (VAS). Additionally, ROM was assessed, including flexion, abduction, external rotation, and internal rotation. These evaluations were conducted to determine the impact of RSA on patients' functional recovery and overall clinical outcomes.

## Radiological Assessment

In the period before the internal fixation surgery, direct radiographs taken after the fracture occurred were analyzed to classify the fractures according to the Neer classification system. Patients were categorized as having Neer Type 3 or

Neer Type 4 fractures. In the period following revision surgery with RSA, prosthesis positioning and bone healing were radiologically evaluated, and any potential complications were recorded. The proper placement of the prosthesis and implant stability were also assessed (Figure 1).



**Figure 1.** Sequential radiographs demonstrating the progression of treatment; (A) Preoperative anteroposterior radiograph showing a proximal humerus fracture; (B) Radiograph showing implant failure after internal fixation with a locking plate; (C) Final radiograph after revision surgery with reverse shoulder arthroplasty

## Evaluated Parameters

In this study, patients' demographic data, fracture types, surgical procedures, and postoperative functional outcomes were assessed. Limb laterality was recorded as right or left extremity, and basic demographic characteristics such as age and gender were analyzed. Fracture classification was performed based on the Neer system, categorizing patients as Neer Type 3 or Neer Type 4, while the duration between the primary surgery and revision surgery was examined. The total follow-up period was calculated to assess long-term outcomes. For postoperative functional assessment, the ASES scores were recorded for both the operated and unaffected arms. QuickDASH score was used to evaluate upper extremity functional impairment, and the VAS was utilized to measure pain levels. Overall shoulder function was assessed using the Constant-Murley score. Postoperative ROM was extensively analyzed, including flexion, abduction, external rotation, and internal rotation. These parameters were used to determine movement limitations and evaluate the functional effectiveness of the prosthesis. Based on all these assessments, the clinical and functional efficacy of RSA following failed internal fixation was investigated.

## RESULTS

The mean age of the patients included in the study was  $70.0 \pm 3.1$  years (range: 65–77 years). The average time between the primary surgery and revision was  $71.6 \pm 27.4$  days, while the mean follow-up duration was recorded as  $28.3 \pm 3.1$  months. In functional assessment, the ASES score was found to be  $59.0 \pm 21.3$  for the operated arm and  $94.8 \pm 7.5$  for the unaffected arm. The QuickDASH score,

which indicates upper extremity functional limitation, had a mean value of  $36.7 \pm 19.9$ , while the VAS score for pain assessment was calculated as  $1.5 \pm 1.5$ . The Constant-Murley score, evaluating shoulder function, was found to be  $58.9 \pm 10.4$ . Regarding ROM, the mean flexion was  $97.0 \pm 24.8$  degrees, abduction was  $92.6 \pm 22.8$  degrees, external rotation was  $25.0 \pm 10.3$  degrees, and internal rotation was  $19.8 \pm 7.0$  degrees (Table 1).

**Table 1. Demographic, surgical, and functional outcomes of patients**

	Mean±S.D.
Age (years)	70.0±3.1
Revision Interval (days)	71.6±27.4
Follow-up Duration (months)	28.3±3.1
ASES operated arm	59.0±21.3
ASES healthy arm	94.8±7.5
QuickDASH	36.7±19.9
VAS score	1.5±1.5
Constant-Murley	58.9±10.4
Flexion (degrees)	97.0±24.8
Abduction (degrees)	92.6±22.8
External rotation (degrees)	25.0±10.3
Internal rotation (degrees)	19.8±7.0

The data in the table are presented as mean±standard deviation (Mean±S.D.); ASES: American Shoulder and Elbow Surgeons Score, VAS: Visual Analog Scale, QuickDASH : The Disabilities of the Arm, Shoulder, and Hand Score

In 52.2% of the patients, surgery was performed on the right shoulder, while 47.8% underwent surgery on the left

shoulder. Among the study participants, 69.6% were female, and 30.4% were male. Regarding fracture classification, 73.9% of the patients had Neer Type 3 fractures, whereas 26.1% had Neer Type 4 fractures (Table 2).

**Table 2. Side, gender, and fracture type characteristics of the patients**

		Count	Column N (%)
Side	Right	12	52.2
	Left	11	47.8
Gender	Female	16	69.6
	Male	7	30.4
Fracture type	Neer type 3	17	73.9
	Neer type 4	6	26.1

The data in the table are presented as count (percentage)

The mean age of female patients was calculated as  $69.8 \pm 2.9$  years, while for male patients, it was  $70.6 \pm 3.7$  years, with no statistically significant difference between the two groups ( $p=0.570$ ). The mean duration between primary surgery and revision was  $76.1 \pm 28.5$  days in female patients and  $61.1 \pm 23.1$  days in male patients, but this difference was not statistically significant ( $p=0.198$ ). In functional assessment, the ASES score for the operated arm was  $56.0 \pm 22.2$  in female patients and  $65.7 \pm 19.1$  in male patients. The QuickDASH score was  $39.5 \pm 20.2$  in females and  $30.5 \pm 19.3$  in males, with no statistically significant

difference between the groups ( $p=0.222$ ). The VAS score, used for pain assessment, was  $1.8 \pm 1.7$  in females and  $0.7 \pm 0.8$  in males, but the difference was not statistically significant ( $p=0.154$ ). Regarding ROM, the mean flexion was  $93.8 \pm 25.0$  degrees in female patients and  $104.3 \pm 24.4$  degrees in male patients, with no statistically significant difference ( $p=0.376$ ). Similarly, abduction was measured as  $88.1 \pm 23.7$  degrees in females and  $102.9 \pm 18.0$  degrees in males ( $p=0.159$ ). External and internal rotation values also did not show a statistically significant difference between the groups (Table 3).

**Table 3. Gender-based comparison of demographic, surgical, and functional outcomes**

	Female (n=16)	Male (n=7)	p value
	Mean $\pm$ S.D.	Mean $\pm$ S.D.	
Age (years)	$69.8 \pm 2.9$	$70.6 \pm 3.7$	0.570 <sup>a</sup>
Revision interval (days)	$76.1 \pm 28.5$	$61.1 \pm 23.1$	0.198 <sup>b</sup>
Follow-up duration (months)	$27.8 \pm 2.9$	$29.4 \pm 3.2$	0.198 <sup>b</sup>
ASES operated arm	$56.0 \pm 22.2$	$65.7 \pm 19.1$	0.278 <sup>b</sup>
ASES healthy arm	$94.4 \pm 8.5$	$95.7 \pm 4.5$	0.922 <sup>b</sup>
QuickDASH	$39.5 \pm 20.2$	$30.5 \pm 19.3$	0.222 <sup>b</sup>
VAS score	$1.8 \pm 1.7$	$0.7 \pm 0.8$	0.154 <sup>b</sup>
Constant-Murley	$56.7 \pm 10.9$	$63.9 \pm 7.7$	0.131 <sup>a</sup>
Flexion (degrees)	$93.8 \pm 25.0$	$104.3 \pm 24.4$	0.376 <sup>b</sup>
Abduction (degrees)	$88.1 \pm 23.7$	$102.9 \pm 18.0$	0.159 <sup>a</sup>
External rotation (degrees)	$23.1 \pm 9.3$	$29.3 \pm 12.1$	0.249 <sup>b</sup>
Internal rotation (degrees)	$18.7 \pm 6.7$	$22.1 \pm 7.6$	0.341 <sup>b</sup>

The data in the table are presented as mean  $\pm$  standard deviation (Mean $\pm$ S.D.); Mann-Whitney U test is denoted by b, while a represents the Independent Samples t-test. ASES: American Shoulder and Elbow Surgeons Score, VAS: Visual Analog Scale, QuickDASH: The Disabilities of the Arm, Shoulder, and Hand Score

No statistically significant differences were observed between the two groups regarding age, time between primary and revision surgery, follow-up duration, ASES Healthy Arm score, QuickDASH score, and ASES Operated Arm score ( $p=0.172$ ,  $p=0.609$ ,  $p=0.919$ ,  $p=0.201$ ,  $p=0.117$ ,

$p=0.135$ , respectively). In functional assessment, the VAS score, which indicates pain levels, was significantly higher in Neer Type 4 patients ( $3.2 \pm 1.8$ ) compared to Neer Type 3 patients ( $0.9 \pm 0.9$ ) ( $p=0.010$ ). Similarly, the Constant-Murley score was significantly lower in the Neer Type 4 group

(50.7±10.4) compared to the Neer Type 3 group (61.8±9.0) (p=0.021). Regarding ROM, flexion was significantly reduced in Neer Type 4 patients (80.0±22.8°) compared to Neer Type 3 patients (102.9±23.1°) (p=0.002). Likewise, abduction was lower in Neer Type 4 patients (73.3±22.5°) compared to Neer Type 3 patients (99.4±19.2°) (p=0.012).

External rotation was also significantly lower in Neer Type 4 patients (17.5±6.9°) compared to Neer Type 3 patients (27.6±10.2°) (p=0.030). Similarly, internal rotation was significantly lower in Neer Type 4 patients (15.0±4.5°) compared to Neer Type 3 patients (21.5±7.0°) (p=0.047) (Table 4).

**Table 4. Fracture type-based comparison of demographic, surgical, and functional parameters**

	NEER type 3 (n=17)	NEER type 4 (n=6)	p value
	Mean±S.D.	Mean±S.D.	
Age (years)	69.5±3.2	71.5±2.2	0.172 <sup>a</sup>
Revision interval (days)	69.6±28.4	77.0±25.9	0.609 <sup>b</sup>
Follow-up duration (months)	28.1±2.4	28.8±4.7	0.919 <sup>b</sup>
ASES operated arm	63.4±18.7	46.3±25.0	0.135 <sup>b</sup>
ASES healthy arm	96.8±3.9	89.2±12.0	0.201 <sup>b</sup>
QuickDASH	33.0±17.5	47.2±24.2	0.117 <sup>b</sup>
VAS score	0.9±0.9	3.2±1.8	<b>0.010<sup>b</sup></b>
Constant-Murley	61.8±9.0	50.7±10.4	<b>0.021<sup>a</sup></b>
Flexion (degrees)	102.9±23.1	80.0±22.8	<b>0.002<sup>b</sup></b>
Abduction (degrees)	99.4±19.2	73.3±22.5	<b>0.012<sup>a</sup></b>
External rotation (degrees)	27.6±10.2	17.5±6.9	<b>0.030<sup>b</sup></b>
Internal rotation (degrees)	21.5±7.0	15.0±4.5	<b>0.047<sup>b</sup></b>

Mann-Whitney U test is denoted by b, while a represents the Independent Samples t-test; the data in the table are presented as mean±standard deviation (Mean±S.D.); statistically significant p-values are indicated in bold; ASES: American Shoulder and Elbow Surgeons Score, VAS: Visual Analog Scale, QuickDASH : The Disabilities of the Arm, Shoulder, and Hand Score

A strong negative correlation was found between revision interval and both ASES Operated Arm score and Constant-Murley score, indicating that as the revision interval increased, these scores decreased (r=-0.784, p<0.001 and r=-0.866, p<0.001, respectively). A strong positive correlation was observed between the revision interval and QuickDASH score, showing that longer revision intervals were associated with higher QuickDASH scores, indicating greater upper extremity functional impairment (r=0.808, p<0.001). Similarly, a

moderate positive correlation was detected between the revision interval and VAS score, suggesting that longer revision times were associated with higher pain levels (r=0.455, p=0.029). Regarding ROM, significant negative correlations were found between the revision interval and flexion, abduction, external rotation, and internal rotation, demonstrating that longer revision times resulted in reduced joint mobility (r=-0.818, p<0.001; r=-0.802, p<0.001; r=-0.638, p=0.001; r=-0.739, p<0.001, respectively) (Table 5).

**Table 5. Correlation between revision interval and functional outcomes**

	Revision interval (r)	p value
ASES operated arm	-0.784	<b>&lt;0.001</b>
QuickDASH	0.808	<b>&lt;0.001</b>
VAS	0.455	<b>0.029</b>
Constant-Murley	-0.866	<b>&lt;0.001</b>
Flexion (degrees)	-0.818	<b>&lt;0.001</b>
Abduction (degrees)	-0.802	<b>&lt;0.001</b>
External rotation (degrees)	-0.638	<b>0.001</b>
Internal rotation (degrees)	-0.739	<b>&lt;0.001</b>

The data in the table are presented as correlation coefficients (r) and p-values; statistically significant p-values are indicated in bold; ASES: American Shoulder and Elbow Surgeons Score, VAS: Visual Analog Scale, QuickDASH : The Disabilities of the Arm, Shoulder, and Hand Score

## DISCUSSION

In this study, the functional status and treatment results of individuals who underwent RSA after unsuccessful internal fixation were assessed. The findings indicated that patients with Neer Type 4 fractures experienced greater pain and had lower functional scores compared to those with Neer Type 3 fractures. Additionally, ROM was significantly more restricted in Neer Type 4 patients. Furthermore, a prolonged interval between the initial surgery and revision was associated with a marked decline in both functional capacity and ROM. Delayed revision surgery may contribute to increased degenerative changes in the shoulder joint and weakening of muscle function. Notably, pain levels and losses in joint mobility appeared to be directly influenced by the timing of revision surgery. These findings suggest that early intervention with RSA may improve functional outcomes and that Neer Type 4 fractures may require a more aggressive surgical approach for optimal management.

Proximal humerus fractures constitute nearly 6% of all adult fractures, with osteoporosis and advanced age being significant risk factors (8,9). The Neer classification is commonly utilized to evaluate proximal humerus fractures (10,11). With the growing prevalence of osteoporosis, the occurrence of proximal humerus fractures is anticipated to rise as well (12). Treating these fractures presents challenges for orthopedic surgeons due to patients' demographic characteristics and associated comorbidities, with nearly half of these fractures classified as displaced and requiring surgical intervention (13,14).

In recent years, RSA has been increasingly employed as a surgical solution for managing complicated proximal humerus fractures in osteoporotic patients (15). Originally designed to address extensive rotator cuff deficiencies, this prosthesis has gradually broadened its indications, yielding favorable outcomes in proximal humerus fractures, arthroplasty revisions, and cases of unsuccessful internal fixation (16,17). Compared to hemiarthroplasty, RSA offers significant advantages, including improved joint stability by shifting the biomechanical center of the shoulder inferiorly and medially, as well as enhancing deltoid muscle function (18,19). Hemiarthroplasty remains a viable option in select cases, particularly in patients with preserved rotator cuff integrity, minimal glenoid erosion, and sufficient bone stock. Additionally, younger patients with good healing potential or those requiring future revision surgery may benefit from hemiarthroplasty due to its bone-preserving nature. While RSA is the preferred choice in most complex cases, surgical decisions should be tailored to individual patient factors.

In our study, the post-surgical functional performance of individuals who received RSA was found to align with findings from similar studies in the literature. Prior research analyzing individuals undergoing primary RSA and those requiring revision surgery due to unsuccessful internal fixation has indicated comparable functional

results without statistically meaningful variation (20). Likewise, individuals diagnosed with Neer Type 2, 3, and 4 fractures who underwent RSA exhibited functional scores comparable to those documented in previous studies (21,22).

When assessing the post-surgical functional performance of individuals undergoing RSA after unsuccessful internal fixation, the Constant-Murley scores reported in prior studies were found to be consistent with those in our research (23,24). Comparisons between RSA and hemiarthroplasty indicate that RSA provides better functional outcomes and lower complication rates (25). Consistent with these findings, our study also demonstrated that patients with Neer Type 4 fractures experienced greater functional loss and higher pain levels.

When assessing ROM, the mobility levels of individuals who received RSA were observed to be comparable to findings documented in previous studies (21-23,26). In a study by Wright et al., individuals who received primary RSA demonstrated improved ROM compared to those who underwent revision surgery after unsuccessful internal fixation (27). However, the alignment of post-revision functional outcomes in our research with previously published findings supports the notion that RSA serves as a viable treatment approach for this patient population (28). Research comparing RSA with hemiarthroplasty in the management of proximal humerus fractures has indicated that both procedures yield comparable ASES scores (29). Although individuals who received RSA due to glenohumeral instability exhibited slightly greater flexion, external rotation, and abduction values compared to those in our study, the achieved outcomes are deemed satisfactory (30).

When assessing pain levels, the VAS scores of individuals who received RSA for rotator cuff degeneration or arthroplasty revision were observed to be comparable to those in our study (31). Some studies have reported higher VAS scores (32). However, in our study, postoperative pain levels were found to be within acceptable limits. Nevertheless, functional performance and joint mobility were reduced among revision patients compared to those who underwent primary RSA. This may be related to deficiencies in the rehabilitation process or the inability to achieve optimal shoulder function after the initial surgery. The prolongation of the interval between primary surgery and revision is considered a negative factor affecting functional outcomes, which aligns with findings reported in other studies in the literature (33). While our results suggest that earlier revision leads to improved functional outcomes, further research is required to define an optimal time frame for intervention.

### Study Limitations

This study has some limitations. First, since it has a retrospective design, there may be certain constraints in the data collection process. To obtain stronger evidence, prospective and randomized controlled studies would be

beneficial. Second, the sample size is relatively limited. As our study focuses on a specific patient group, future studies with larger populations would help confirm these findings. Third, while the follow-up period is sufficient for evaluating mid-term outcomes, longer follow-up is necessary to determine long-term results. The durability of the prosthesis and the sustainability of functional improvements could be better assessed in future long-term studies. Fourth, detailed data on the rehabilitation process are not available. Postoperative physical therapy programs may vary among individuals, potentially affecting functional outcomes. Further studies investigating the impact of rehabilitation would provide more insights into this aspect. Finally, the lack of a comparative control group restricts the ability to directly contrast the findings with those of patients undergoing initial reverse shoulder replacement or alternative operative approaches. Nevertheless, this research offers important perspectives on the clinical and functional results observed in this particular patient group. Despite these limitations, our study contributes important findings regarding the evaluation of functional and clinical outcomes in patients undergoing RSA following failed internal fixation. Subsequent research involving larger patient populations and extended follow-up durations could offer more in-depth insights into this topic.

## CONCLUSION

The findings of this research highlight that individuals who undergo RSA due to irreparable rotator cuff failure following unsuccessful surgical stabilization of osteoporotic proximal humerus fractures experience substantial functional gains. While prolonged revision intervals were associated with decreased functional outcomes and increased pain levels, early intervention may contribute to better postoperative recovery. Moreover, individuals with Neer Type 4 fractures demonstrated greater restrictions in joint mobility and higher pain levels when compared to those with Neer Type 3 fractures. The results emphasize the significance of early detection and sound surgical decision-making in improving patient outcomes. Subsequent research involving larger cohorts and extended follow-up durations is suggested to confirm these findings and enhance treatment approaches for this patient group.

**Financial disclosures:** *The authors declared that this study has received no financial support.*

**Conflict of interest:** *The authors have no conflicts of interest to declare.*

**Ethical approval:** *Ethical approval for this study was obtained from the Clinical Research Ethics Committee of Adana City Training and Research Hospital (Approval Date: 16.12.2020, Approval Number: 1122). Informed consent was obtained from all patients included in the study. This study adheres to the ICMJE Recommendations and STROBE guidelines. Sex and gender considerations were addressed in accordance with the SAGER guidelines, and the manuscript follows the EASE Guidelines for Authors and Translators.*

## REFERENCES

- Jacobs AN, Umlauf JA, Kniss JR. Proximal humerus fracture following arthroscopic biceps tenodesis. *J Orthop Sports Phys Ther.* 2020;50:649.
- Koeppel J, Stolberg-Stolberg J, Fischhuber K, et al. The incidence of proximal humerus fracture-an analysis of insurance data. *Dtsch Arztebl Int.* 2023;120:555-6.
- Rudran B, Little C, Duff A, Poon H, Tang Q. Proximal humerus fractures: anatomy, diagnosis and management. *Br J Hosp Med (Lond).* 2022;83:1-10.
- Marigi EM, Bartels DW, Aibinder WR, Cofield RH, Sperling JW, Sanchez-Sotelo J, et al. Hemiarthroplasty for proximal humerus fractures and for fracture sequelae: did not differ in their outcomes. *JSES Int.* 2023;7:239-46.
- Chawla H, Gamradt S. Reverse total shoulder arthroplasty: technique, decision-making and exposure tips. *Curr Rev Musculoskelet Med.* 2020;13:180-5.
- Luster TG, Dean RS, Trasolini NA, et al. Predictive factors influencing internal rotation following reverse total shoulder arthroplasty. *J Shoulder Elbow Surg.* 2024;33:1200-8.
- Galvin JW, Kim R, Ment A, et al. Outcomes and complications of primary reverse shoulder arthroplasty with minimum of 2 years' follow-up: a systematic review and meta-analysis. *J Shoulder Elbow Surg.* 2022;31:e534-44.
- Perritt S, Roberts M. Flexural-slip structures in the bushveld complex, South Africa?. *Journal of Structural Geology.* 2007;29:1422.
- Brorson S, Rasmussen JV, Olsen BS, et al. Reverse shoulder arthroplasty in acute fractures of the proximal humerus: a systematic review. *Int J Shoulder Surg.* 2013;7:70-8.
- Neer CS 2nd. Displaced proximal humeral fractures. I. Classification and evaluation. *J Bone Joint Surg Am.* 1970;52:1077-89.
- Lanting B, MacDermid J, Drosdowech D, Faber KJ. Proximal humeral fractures: a systematic review of treatment modalities. *J Shoulder Elbow Surg.* 2008;17:42-54.
- Palvanen M, Kannus P, Niemi S, Parkkari J. Update in the epidemiology of proximal humeral fractures. *Clin Orthop Relat Res.* 2006;442:87-92.
- García-Fernández C, Lopiz Y, Rizo B, et al. Reverse total shoulder arthroplasty for the treatment of failed fixation in proximal humeral fractures. *Injury.* 2018;49:S22-6.
- Dezfuli B, King JJ, Farmer KW, et al. Outcomes of reverse total shoulder arthroplasty as primary versus revision procedure for proximal humerus fractures. *J Shoulder Elbow Surg.* 2016;25:1133-7.
- Savin DD, Zamfirova I, Iannotti J, et al. Survey study suggests that reverse total shoulder arthroplasty is becoming the treatment of choice for four-part fractures of the humeral head in the elderly. *Int Orthop.* 2016;40:1919-25.
- Familiari F, Rojas J, Nedim Doral M, et al. Reverse total shoulder arthroplasty. *EFORT Open Rev.* 2018;3:58-69.
- Patel DN, Young B, Onyekwelu I, et al. Reverse total shoulder arthroplasty for failed shoulder arthroplasty. *J Shoulder Elbow Surg.* 2012;21:1478-83.

18. Juhan T, Stone M, Jalali O, et al. Irreparable rotator cuff tears: current treatment options. *Orthop Rev (Pavia)*. 2019;11:8146.
19. Farshad M, Gerber C. Reverse total shoulder arthroplasty from the most to the least common complication. *Int Orthop*. 2010;34:1075-82.
20. Kristensen MR, Rasmussen JV, Elmengaard B, et al. High risk for revision after shoulder arthroplasty for failed osteosynthesis of proximal humeral fractures. *Acta Orthop*. 2018;89:345-50.
21. Obert L, Saadnia R, Tournier C, et al. Four-part fractures treated with a reversed total shoulder prosthesis: Prospective and retrospective multicenter study. Results and complications. *Orthop Traumatol Surg Res*. 2016;102:279-85.
22. Grubhofer F, Wieser K, Meyer DC, et al. Reverse total shoulder arthroplasty for acute head-splitting, 3- and 4-part fractures of the proximal humerus in the elderly. *J Shoulder Elbow Surg*. 2016;25:1690-8.
23. Grubhofer F, Wieser K, Meyer DC, et al. Reverse total shoulder arthroplasty for failed open reduction and internal fixation of fractures of the proximal humerus. *J Shoulder Elbow Surg*. 2017;26:92-100.
24. Cacak N, Klobucar H, Medancic N. Reverse shoulder arthroplasty in acute fractures provides better results than in revision procedures for fracture sequelae. *Int Orthop*. 2015;39:343-8.
25. Shannon SF, Wagner ER, Houdek MT, et al. Reverse shoulder arthroplasty for proximal humeral fractures: outcomes comparing primary reverse arthroplasty for fracture versus reverse arthroplasty after failed osteosynthesis. *J Shoulder Elbow Surg*. 2016;25:1655-60.
26. Constant CR, Murley AH. A clinical method of functional assessment of the shoulder. *Clin Orthop Relat Res*. 1987;160-4.
27. Wright JO, Ho A, Kalma J, et al. Uncemented reverse total shoulder arthroplasty as initial treatment for comminuted proximal humerus fractures. *J Orthop Trauma*. 2019;33:e263-9.
28. Sebastia-Forcada E, Lizaur-Utrilla A, Cebrian-Gomez R, et al. Outcomes of reverse total shoulder arthroplasty for proximal humeral fractures: primary arthroplasty versus secondary arthroplasty after failed proximal humeral locking plate fixation. *J Orthop Trauma*. 2017;31:e236-40.
29. Boileau P, Seeto BL, Clowez G, et al. SECEC Grammont Award 2017: the prejudicial effect of greater tuberosity osteotomy or excision in reverse shoulder arthroplasty for fracture sequelae. *J Shoulder Elbow Surg*. 2020;29:2446-58.
30. Wolfensperger F, Grüniger P, Dietrich M, et al. Reverse shoulder arthroplasty for complex fractures of the proximal humerus in elderly patients: impact on the level of independency, early function, and pain medication. *J Shoulder Elbow Surg*. 2017;26:1462-8.
31. Pastor MF, Kieckbusch M, Kaufmann M, et al. Reverse shoulder arthroplasty for fracture sequelae: Clinical outcome and prognostic factors. *J Orthop Sci*. 2019;24:237-42.
32. Nielsen KP, Amundsen A, Olsen BS, Rasmussen JV. Good long-term patient-reported outcome after shoulder arthroplasty for cuff tear arthropathy. *JSES Int*. 2022;6:40-3.
33. Anakwenze OA, Zoller S, Ahmad CS, Levine WN. Reverse shoulder arthroplasty for acute proximal humerus fractures: a systematic review. *J Shoulder Elbow Surg*. 2014;23:e73-80.