

Colonic lymphoma presented as acute abdomen: A case report and review of literature

Akut karına sebep olan kolonik lenfoma; Olgu sunumu ve literatür derlemesi

İlyas Kudaş¹, Abdullah Şişik²

¹ Department of General Surgery, Tekman State Hospital, Erzurum, Turkey

² Department of General Surgery, University of Health Science, Umraniye Education and Research Hospital, Istanbul, Turkey

Abstract

The primary gastrointestinal tract (GIS) lymphomas constitute approximately 1% of all GIS tumors. Primary GIS involvement in Hodgkin lymphoma is extremely rare. In this study, we aimed to present a case of colonic lymphoma that grows rapidly in young adult patients and causes acute abdomen. A 20-year-old woman presented with complaints of nausea, vomiting and diarrhea. Ultrasonography revealed mass and free fluid in the right lower quadrant. A 9cm diameter solid mass was observed in the cecum with tomography. As a result of these findings and clinical evaluation, emergency laparotomy was decided. A 10 cm diameter mass terminal ileum and cecum was seen and right hemicolectomy was performed. Because the age of the presented patient is young and the complaints are faint, no diagnosis has been made until the 9cm size is reached. It should be kept in mind that such situations may be met and further testing should be avoided if necessary.

Keywords: Hodgkin lymphoma, Acute abdomen, Colon tumor

Öz

Primer gastrointestinal sistem (GİS) lenfomaları tüm GİS tümörlerinin yaklaşık %1'ini oluşturmaktadır. Hodgkin lenfomada primer GİS tutulumu son derece nadirdir. Bu çalışmada genç yetişkin hastada hızla büyüyen ve akut karın tablosuna sebep olan kolonik lenfoma olgusunu sunmayı amaçladık. 20 yaşında kadın bulantı, kusma ve ishal şikayetleriyle başvurdu. Ultrasonografi incelemesinde sağ alt kadranda kitle ve serbest sıvı görüldü. Tomografide Çekumu içinde alan pericekal 9cm çaplı solid kitle görüldü. Bu bulgular ve klinik değerlendirme sonucunda acil laparotomiye karar verildi. Laparotomide terminal ileum ve çekumu içine almış 10cm çaplı kitle görüldü ve sağ hemikolektomi yapıldı. Sunulan hastanın yaşının genç olması ve şikayetlerinin silik olması nedeniyle 9cm boyutuna ulaşılan kadar tanısı konulamamıştır. Bu tür durumlar ile karşılabileceği akılda tutulmalı ve gereğinde ileri tetkikten kaçınılmamalıdır.

Anahtar kelimeler: Hodgkin lenfoma, Akut karın, Kolon tümörü

Introduction

Primary gastrointestinal tract (GIS) lymphomas constitute approximately 0.9% of all lymphomas [1]. Primer GIS lymphoma was first described by Billroth in 1871 [2]. Dawson criteria are used most frequently in the definition of primary GIS lymphoma [3]. The most common organ in the gastrointestinal tract is the stomach (50-70%) followed by small intestines (20-35%), esophagus (5% - 10%) and esophagus (<1%). Primary colon lymphomas constitute approximately 0.1-0.5% of malignant tumors originating from the colon [4].

Primary colon involvement in the Hodgkin's lymphoma (HL) is extremely rare and only isolated cases have been reported in the literature. These cases were mostly treated with modalities based on basic surgery [5,6]. Complications can be various in colonic tumors, and first presentation as a complication has not been evaluated earlier [5,7].

In this study, our aim is to emphasize the importance of early diagnosis and surgical treatment of colon lymphoma due to complications caused by diagnostic delays, and is to perform a review of literature.

Corresponding author / Sorumlu yazar:
İlyas Kudaş

Address / Adres: Genel Cerrahi Kliniği, Tekman Devlet Hastanesi, Tekman, Erzurum, Türkiye
e-Mail: ilyaskudas@hotmail.com

Informed Consent: The author stated that the written consent was received from the patient who was presented in this study.

Hasta Onamı: Yazar çalışmada sunulan hastadan yazılı onam alındığını ifade etmiştir.

Conflict of Interest: No conflict of interest was declared by the authors.

Çıkar Çatışması: Yazarlar çıkar çatışması bildirmemişlerdir.

Financial Disclosure: The authors declared that this study has received no financial support.
Finansal Destek: Yazarlar bu çalışma için finansal destek almadıklarını beyan etmişlerdir.

Received / Geliş tarihi: 05.03.2018

Accepted / Kabul tarihi: 10.03.2018

Published / Yayın tarihi: 11.03.2018

Copyright © 2018 The Author(s)

Published by JOSAM

This is an open access article distributed under the terms of the Creative Commons Attribution-NonCommercial-NoDerivatives License 4.0 (CC BY-NC-ND 4.0) where it is permissible to download, share, remix, transform, and buildup the work provided it is properly cited. The work cannot be used commercially without permission from the journal.



Case presentation

A 20-year-old woman applied to her emergency clinic with complaints of nausea, vomiting and diarrhea. On the physical examination, the mass was palpated in the lower right quadrant. Laboratory examination was normal except for leucocyte count (11,000 /mm³) and lactate dehydrogenase level (518 U/L). Ultrasonography revealed mass and free fluid in the right lower quadrant. In the cecum, a mass of 9 cm diameter solid mass was found and free air was seen around the perforation in tomography study (Figure 1). As a result of these findings and clinical evaluation, emergency laparotomy was decided. In laparotomy, a 10 cm diameter mass in terminal ileum and cecum was seen, and right hemicolectomy was performed. The patient also came in earlier postoperative periods and stated that they had temporary abdominal pain and nausea complaints. No acute abdomen was detected, and medical treatment was continued. The patient was discharged on the 6th day without any problems. Pathologic examination revealed diffuse high grade B cell lymphoma of the sigmoid origin. Patients was informed and followed by oncology for oncologic treatment.

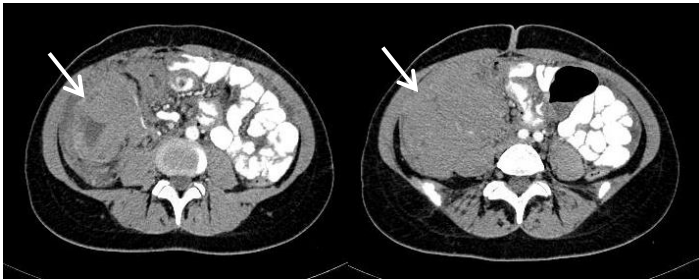


Figure 1: Abdominal computed tomography shows a mass (arrow)

Discussion

Primary colorectal lymphomas account for 6% to 12% of all gastrointestinal tract lymphomas. It is usually seen between the 4th and 7th decades of life and the average age at diagnosis is 55 [8]. Inflammatory bowel diseases (Crohn's disease, ulcerative colitis) and immunosuppression are important risk factors. The most common symptom is abdominal pain followed by loss of appetite and weight loss. In lesser proportions, mass in the abdomen, rectal bleeding, change in bowel habits may be seen. Bowel obstruction and perforation are rare [9].

Since histological diagnosis is very difficult, diagnosis can be achieved by immunophenotypic and genotypic studies of the surgically removed target. Non-Hodgkin's Lymphomas originate from T cells, B cells or histiocytes. The type of cell the tumor originates from is usually determined based on the phenotypic and molecular characteristics of the tumor cells, 80% to 85% of the B cell origin and the remaining 10% to 15% of the T cell tumors. The cell type has been shown to have a worse prognosis than the B cell type [10-13]. The reason for this difference cannot be explained.

Diagnostic colonoscopy, computed tomography and double contrast colonography are frequently used. In double contrast barium studies and computed tomography examinations, polypoid, infiltrative, mesenteric dilated endoexoenteric cavity masses, thickening of mucosal nodules and cornea may be seen [1,2]. Occasionally, focal lumen narrowing, aneurysmal dilatation, or fistula formation in an ulcerative form may be

observed. Colonoscopy is very useful both for macroscopic evaluation of the kitten and for microscopic evaluation by biopsy.

The rare occurrence of this disease complicates clinical trials and the most appropriate treatment method cannot be identified. Most authors suggest surgical treatment methods used in colorectal carcinomas without chemotherapy or with chemotherapy [12,13]. Surgical intervention plays an important role in the treatment of the disease. Curative intentional surgery may be recommended for those with localized disease, palliative surgical procedures may be used to correct obstruction and other symptoms. However, surgical treatment is also important in patients with perforation, bleeding, and fistulae [9,14]. In a multicenter study conducted, only patients with chemotherapy showed that the outcome was worse than with chemotherapy or without chemotherapy [14]. However, this result can be explained by the fact that the majority of patients receiving chemotherapy have a T-cell type that is worse prognostic [14,15]. One of the reported complications of chemotherapy used in gastrointestinal tract lymphomas is tumor necrosis which causes bowel perforation [16,17]. A transmural tumor that invades and weakens the intestinal wall may lead to necrosis and bowel perforation after chemotherapy [18,19]. There is still no consensus on the timing of combined chemotherapy and surgical treatment. In a study conducted by Kim et al. [20], none of the 23 patients with colorectal lymphoma who received only chemotherapy as treatment had perforation during chemotherapy. Therefore, there is no strong correlation between chemotherapy and bowel perforation. Evidence that primary surgery is the treatment of primary colorectal lymphomas is not strong. Chemotherapy can be considered as a primary treatment if surgical treatment is at high risk, if the patient does not want surgical treatment and if it accepts a small risk of perforation during chemotherapy. The limitations of our study are small number of patients and retrospective. The rarity of the disease makes it difficult to perform a prospective study. A meta-analysis study to be done will help in this regard.

In conclusion, primary colon lymphoma is a rare disease. It is still unclear whether the surgeon or chemotherapy will be offered first. Many controversial issues are still uncertain and further work is needed. Early laparotomy may have a positive effect on surgical morbidity, mortality and survival time in colon lymphomas due to rapid clinical course.

References

1. Busch E, Rodrigez-Bigas M, Mamounas E, et al. Primary colorectal non-Hodgkin's lymphoma. *Ann Surg Oncol.* 1994;1:222-28.
2. Billroth T. Multiple lymphome. Erfolgreiche behandlung mitarsenik. *Wien Med Wochenschr.* 1871;21:1066.
3. Orangio RG. Nonepithelial colorectal tumors, in: Fazio WV (ed). *Current Therapy in Colon and Rectal Surgery.* Mosby Comp, Philadelphia; 2005. p. 409-14.
4. Stanojević G, Stojanović M, Jovanović M, et al. Primary colorectal lymphomas. *Vojnosanit Pregl.* 2009;66:295-301.
5. Cai S, Cannizzo F Jr, Bullard Dunn KM, Gibbs JF, Czuczman M, Rajput A. The role of surgical intervention in non-Hodgkin's lymphoma of the colon and rectum. *Am J Surg.* 2007;193:409-12.
6. Çalışkan YK. Ten years ago, what was the main etiology of intestinal obstructions? Historical perspective: A retrospective cohort study. *J Surg Med.* 2017;1(2):21-3.

7. Kilic A, Hasbahceci M, Alimoglu O, Basak F, Sisik A, Canbak T. Colonic cancers fistulised to other segments of the gastrointestinal tract. Case series and review of literature. *Arch Clin Exp Med*. 2016;1(1):8-10.
8. Shepherd NA, Hall PA, Coates PJ, Levison DA. Primary malignant lymphoma of the colon and rectum. A histopathological and immunohistochemical analysis of 45 cases with clinicopathological correlations. *Histopathology*. 1988;12:235-52.
9. Amer MH, el-Akkad S. Gastrointestinal lymphoma in adults: clinical features and management of 300 cases. *Gastroenterology*. 1994;106:846-58.
10. Lee HJ, Han JK, Kim TK, et al. Peripheral T-cell lymphoma of the colon: double-contrast barium enema examination finding in six patients. *Radiology*. 2001;218:751-56.
11. Gonzalez QH, Heslin MJ, Dávila-Cervantes A, et al. Primary colonic lymphoma. *Am Surg*. 2008;74:214-6.
12. Campo E, Gaulard P, Zucca E, et al. Report of the European task force on lymphomas: workshop on peripheral T-cell lymphomas. *Ann Oncol*. 1998;9:835-43.
13. Chan JK. Peripheral T-cell and NK-cell neoplasms: an integrated approach to diagnosis. *Mod Pathol*. 1999;12:177-99.
14. Wang MH, Wong JM, Lien HC, et al. Colonoscopic manifestations of primary colorectal lymphoma. *Endoscopy*. 2001;33: 605-09.
15. Hwang WS, Yao JC, Cheng SS, Tseng HH. Primary colorectal lymphoma in Taiwan. *Cancer*. 1992;70:575-80.
16. Meyers PA, Potter VP, Wollner N, Exelby P. Bowel perforation during initial treatment for childhood non-Hodgkin's lymphoma. *Cancer*. 1985;56:259-61.
17. McDermott EW, Cassidy N, Heffernan SJ. Perforation through undiagnosed small bowel involvement in primary thyroid lymphoma during chemotherapy. *Cancer*. 1992;69:572-3.
18. Ara C, Coban S, Kayaalp C, Yilmaz S, Kirimlioglu V. Spontaneous intestinal perforation due to non-Hodgkin's lymphoma: evaluation of eight cases. *Dig Dis Sci*. 2007;52:1752-6.
19. Stanojevic GZ, Nestorovic MD, Brankovic BR, et al. Primary colorectal lymphoma: An overview. *World J Gastrointest Oncol*. 2011 Jan 15;3(1):14-8.
20. Kim YH, Lee JH, Yang SK, et al. Primary colon lymphoma in Korea: a KASID (Korean Association for the Study of Intestinal Diseases) study. *Dig Dis Sci*. 2005;50:2243-7.