

Primary bilateral non-refluxing non-obstructive megaureter in an adult: An extremely rare case

Erişkinde iki taraflı primer reflüksif ve obstrüktif olmayan megaüreter: Çok nadir bir olgu

Ibrahim Keles¹, Mustafa Karalar¹, Nazan Okur², Emre Kacar², Yigit Akin³, Mutlu Ates¹

1Department of Urology, Afyonkocatepe University School of Medicine, 03300, Afyonkarahisar, Turkey.

2Department of Radiology, Afyonkocatepe University School of Medicine, 03300, Afyonkarahisar, Turkey.

3Department of Urology, Izmir Katip Celebi University School of Medicine, 35400, Izmir, Turkey.

Corresponding author

Yigit Akin, MD

Department of Urology, Izmir Katip Celebi University School of Medicine, 35400, Erzincan/Turkey Mobile :

+90 (506) 533 49 99 e-mail : yigitakin@yahoo.com

Geliş tarihi / Received: 08.12.2016

Kabul tarihi / Accepted: 24.03.2017

Abstract

Non-refluxing and non-obstructive megaureter is usually diagnosed in neonates. It is very rare in adults. Herein we presented a 45 year-old man with macroscopic hematuria. He was diagnosed primary non-refluxing non-obstructive megaureter after clinical evaluations. In addition we reviewed current literature in the light of this very rare condition.

Keywords: Adults, Ureter, Vesico Ureteral Reflux, Ureteral Obstruction

Öz

Reflüksif ve obstrüktif olmayan megaürter genellikle yeni doğanlarda teşhis edilir. Yetişkinlerde çok nadirdir. Bu olgu sunumunda makroskopik hematüri ile başvuran 45 yaşındaki bir erkek hasta sunuldu. Klinik değerlendirmelerden sonra primer reflüksif ve obstrüktif olmayan megaüreter teşhisi kondu. Buna ek olarak, bu çok ender vaka eşliğinde mevcut literatürü gözden geçirdik.

Anahtar Kelimeler: Erişkin, Üreter, Vezikoüreteral reflü, Üreteral obsrüksion

Introduction

Megaureter is described as diameter of ureter is larger than 8 mm (1). This abnormality is usually described in neonates and children. Twenty-three % of hydronephrosis in prenatal period are diagnosed as megaureter in follow-up (2). Moreover megaureter is diagnosed in one-quarter of children with obstructive uropathy (1). However all of megaureters are not non-obstructive and also non-refluxing, these are 6-10% of all megaureters (3). When megaureter comes into question, investigations for differential diagnosis should be performed. Furthermore if evidence of refluxing and obstruction can be excluded, it is named as non-refluxing and non-obstructive megaureter. However this condition is usually diagnosed in early years of life, in this case report we presented a primary bilateral non-refluxing non-obstructive megaureter in an adult.

Case Report

A 45-year-old man admitted our outpatient clinic with chief symptom of macroscopic hematuria. Up to date, he had no co-morbidity except history of left kidney stone, which was incidentally diagnosed 2 years ago. He had not received any treatment for kidney stone before. Physical examination and blood analyses were normal. There was microscopic hematuria in urinary analysis. Radiology revealed bilateral grade 2-3 kidney dilatation and a 8 mm hyperechogenicity compatible with left renal calculi were diagnosed in ultrasonography (US). In intravenous urography (IVU) there was bilateral uretero-hydronephrosis (Fig. 1).

After IVU, non-enhanced computed tomography (CT) was performed for investigating non-opaque bilateral distal ureter stones. In CT, bilateral both distal ureters were dilated (Fig. 1). Diameter of left ureter and right ureter was 16 mm and 18 mm, respectively.

Scintigraphy with diuretic was performed with Mercurio-acetyltriglycine (MAG 3) for excluding secondary causes of megaureter. MAG 3 renogram revealed that renal function in the right and in the left was 48% and 52%, respectively. However there was no sign of obstruction in upper urinary system, we investigated for refluxing in ureter as well as in lower urinary tract system. In uroflowmetry, maximum flow was 32 ml/sec and voided volume was 420 ml. Residual urine was 20 cc. In addition he underwent cystoscopy and bilateral ureteric orifices were normal. Moreover we investigated for refluxing. There was no pathology in voiding cystourethrography (VCUG) (Fig. 1).

In the light of these findings, patient was diagnosed as primary non-refluxing and non-obstructive megaureter with left kidney stone. He underwent extracorporeal shock wave lithotripsy (ESWL). After 2nd session in

ESWL, he was stone free. Now, the patient is in follow-up, in urology outpatient clinic.

Discussion

Megaureter which is usually diagnosed in neonates, was first described in 1923 by Caulk (3). After description of megaureter, there had been a complexity in diagnosis. Therefore Smith et al classified megaureter in 4 groups; refluxing, obstructed, refluxing and obstructed, non-refluxing and non-obstructed, respectively (4). Primary non-refluxing and non-obstructed megaureter is diagnosed after excluding obstruction, reflux and secondary causes of dilatation. Thus, this is an extremely rare condition in advancing age. Pathophysiology and etiologies are still not clear. However there are some theories such as increased urine in fetal period, and similar like in diabetes insipidus, increased compliance in fetal ureters, delayed development of normal peristalsis in ureter, it

seems like multifactorial etiologies (5). In children, when non-refluxing and non-obstructive megaureter is diagnosed, active surveillance by antibiotic prophylaxis and US examinations are recommended (6). Most of megaureters resolve spontaneously with age (6). Surgical treatment options may be performed when deterioration in renal functions, recurrent pyelonephritis, unamended pain (6). There had not been any management recommendations in adults for primary non-refluxing and non-obstructive megaureters.

Diagnostic tools were advanced by developing technologies. Megaureter is usually diagnosed in prenatal period by US (7). Additionally this may be asymptomatic in new-borns. When megaureter is diagnosed in an adult, secondary causes usually come to mind first. Therefore, additional diagnostic tests such as IVU which is helpful for viewing urinary anatomy and evaluating functions; VCUG which is used for evaluating reflux;

cystoscopy which is used for excluding pathologies in urethra, bladder neck, bladder, ureteric orifices, should be performed for differential diagnosis. Scintigraphic tests may be also used for evaluating obstruction in upper urinary tract (8). In our case, we performed all of diagnostic tests for differential diagnosis. Outcomes of all tests above showed that there was no sign of refluxing and obstruction. In literature there are few reports about bilateral primary non-obstructive and non-refluxing megaureter in an adult. According to our knowledge this case is the first from east of Europe, Asia and Middle East, in literature.

Hamilton and Fitzpatric reported 11 patients with non-obstructive megaureters with pain (9). In our case, major symptom was macroscopic hematuria which was appeared only once. Of course the reason was kidney stone. But rarely, it may be a sign of megaureter without kidney stone. Fraser et al described a rare case like this (10). However,

rare conditions may be presented with clinical symptoms, detailed clinical investigations which were described above, should be performed for differential diagnosis. On the other hand, secondary causes of megaureters are diagnosed more than primary. At that time, when secondary causes of megaureter are diagnosed, treatment options should be performed. If treatments are not performed, irreversible pathologies like worsening in renal functions may occur (6). Our case was 45-year-old and only

kidney stone was treated by ESWL. Megaureter did not need to be treated and it is in follow-up, in urology outpatient clinic.

In the light of literature and our case, primary non-refluxing and non-obstructive megaureter is extremely rare in adults. In adults, there is still no exact management guide. It seems like treatment options depend on clinical situations as in our case. ESWL may be performed for kidney calculi. Follow-up period should be performed in out-patient clinics.

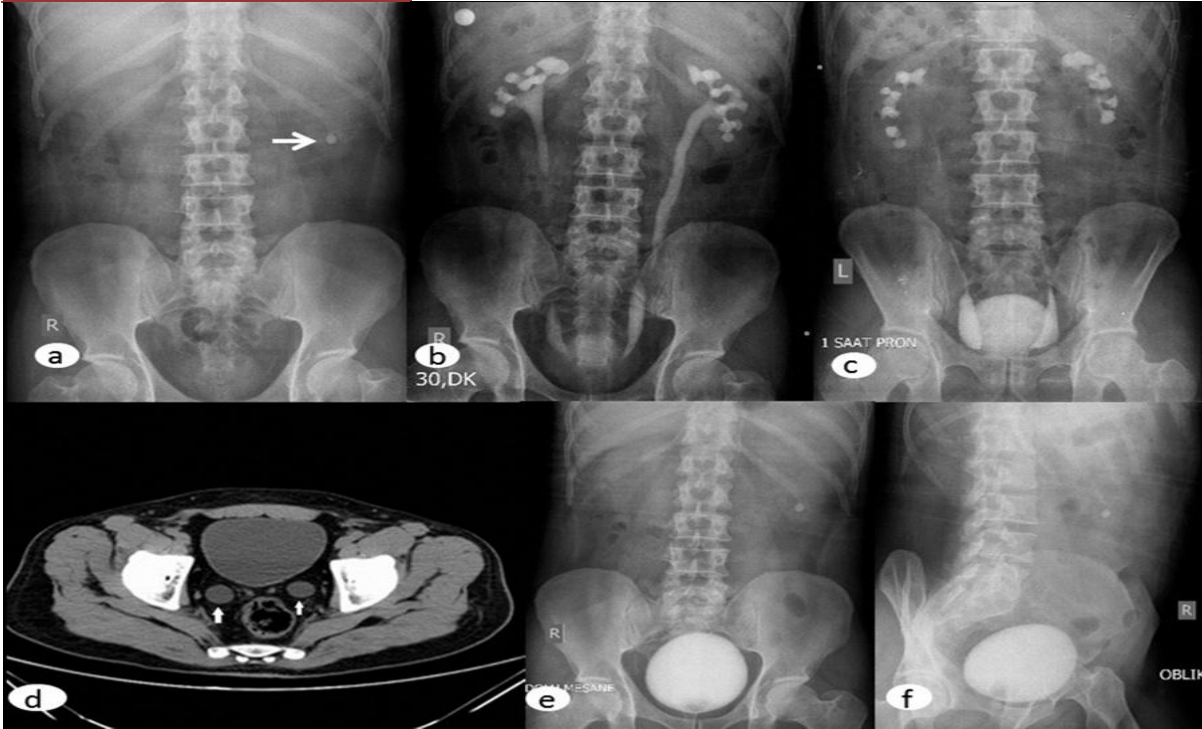


Fig. 1 Radiological evaluations of patients with megaureter. a. Kidney ureter bladder x-ray, there is a 8 mm stone in the lower pole of left kidney (arrow). b. Intravenous urography of patient at the 30rd minutes. Dilated calices and ureters in figure. c. In prone position, dilated calices and ureter are still in figure, after 1 hour of intravenous urography. d Non-enhanced computed tomography. There are bilateral dilated distal ureters (arrows). Diameter of left ureter is 16 mm and right ureter is 18 mm. e. Voiding cystourethrogram of patient in anterior-posterior. f. There was no refluxing in oblique voiding cystourethrogram.

References

- Hodges SJ, Werle D, McLorie G, Atala A: Megaureter. *Scientific World Journal* 2010 (Apr 13); 10: 603-612.
- Brown T, Mandell J, Lebowitz RL: Neonatal hydronephrosis in the era of sonography. *AJR AM J Roentgenol* 1987; 148(5) : 959-963.
- Caulk JR: Megaureter:the importance of the ureterovesical valve. *J Urol* 1923; 9 (2): 315-319.
- Smith ED, Cussen LJ, Glenn J: Report of working party to establish an international nomenclature for the large ureter. *Birth Defects Orig Artic Ser* 1977; 13 (5): 3-8.
- Simoni F, Vio L, Pizzini C, Benini D, Fanos V: Megaureter: classification, pathophysiology, and management. *Pediatr Med Chir* 2000; 22 (1): 15-24.
- Baskin LS, Zderic SA, Snyder HM: Primary dilated megaureter: long term follow up. *J Urol* 1994; 152 (2 Pt 2): 618-621.
- Rickwood AM, Jee LD, Williams MP, Anderson PA: Natural history of obstructed and pseudo-obstructed megaureters detected by prenatal ultrasonography. *Br J Urol* 1992; 70 (3): 322-325.
- Türkölmez S, Ors D, Korkmaz M: Megaureter visualization on Tc-99m DMSA scintigraphy. *Ann Nucl Med* 2005; 19 (5): 421-423.
- Hamilton S, Fitzpatrick JM: Primary non-obstructive megaureter in adults. *Clin Radiol* 1987; 38 (2): 181-185.
- Fraser L, Khan MH, Ross M, Patterson PJ: Rare case of non-refluxing non-obstructive megaureter in an adult. *Int Urol Nephrol* 2007; 39 (2): 421-423.