

Comorbid Retroperitoneal and Mediastinal Fibrosis in a Case of Periaortitis

Periaortitli Hastada Retroperitoneal ve Mediastinal Fibrozis Birlikteliği: Olgu Sunusu

Mustafa Resorlu, Canan Akgün Toprak, Muhsin Özgün Öztürk

Department of Radiology, Canakkale Onsekiz Mart University, Faculty of Medicine, Canakkale, Turkey

Corresponding author

Mustafa RESORLU, MD

Çanakkale Onsekiz Mart University, Terzioğlu Yerleşkesi, Barbaros Mh, 17100, Çanakkale, Turkey

+90 505 454 8722 / +90 286 2180393 E-mail: mustafaresorlu77@gmail.com

Geliş tarihi / Received: 19.12.2016 **Kabul tarihi / Accepted:** 02.04.2017

ABSTRACT

Chronic periaortitis is a rare condition. Middle-aged males comprise a large proportion of patients. An association has been proposed with idiopathic retroperitoneal fibrosis, perianeurysmal fibrosis and inflammatory abdominal aortic aneurysm, and autoimmunity has been implicated in the pathophysiology. Comorbidity of retroperitoneal fibrosis, which is frequently idiopathic, and mediastinal fibrosis, which is particularly associated with infectious processes, is rare. The purpose of this study was to report a case of comorbid retroperitoneal and mediastinal fibrosis in a patient with periaortitis, together with imaging findings.

Key words: Retroperitoneal fibrosis, Mediastinal fibrosis, Periaortitis

ÖZ

Kronik periaortit daha sık orta yaş erkekleri etkilemekte ve nadir olarak görülmektedir. Patofizyolojisinde otoimmünitenin etkili olduğu ve idiyomatik retroperitoneal fibrozis, perianevrizmal fibrozis, enflamatuar abdominal aort anevrizması ile ilişkili olduğu ileri sürülmektedir. Retroperitoneal fibrozis olgularının büyük kısmı idiyopatiktir. Mediastinal fibrozis ise sıklıkla enfeksiyöz süreçle ilişkilidir. Bu iki patolojik tablonun birlikteliği ise oldukça nadirdir. Biz bu çalışmamızda periaortiti olan bir hastamızda eşlik eden retroperitoneal ve mediastinal fibrozis birlikteliğini sunmayı amaçladık

Anahtar kelimeler: Retroperitoneal fibrozis, mediastinal fibrozis, periaortit

INTRODUCTION

Following the case reported by Comings et al. in 1967, multisystem fibrosis, known as multifocal fibrosclerosis, has been presented as case reports in the literature (1). However, comorbid mediastinal and retroperitoneal fibrosis are rare. Retroperitoneal fibrosis, characterized by fibrosis and inflammation in the retroperitoneum, is a rare disease causing compression of retroperitoneal structures, particularly the ureters (2). Mediastinal fibrosis is a rare condition that can cause compression in large vessels, swallowing difficulty associated with esophageal compression and asthma-like symptoms (3). Idiopathic retroperitoneal fibrosis exhibits similar histopathological characteristics to perianeurysmal fibrosis and inflammatory abdominal aortic aneurysms, and chronic periaortitis is related to these disease groups (4). This study reports a case of comorbid retroperitoneal fibrosis and mediastinal fibrosis in a patient with periaortitis.

CASE REPORT

A 50-year-old male patient presented with dyspnea and cough. He had no history of surgery or chronic disease, but had smoked for 25 years. Enlargement of the left hilum was determined at chest radiography, and computed tomography (CT) was performed. This revealed homogeneous soft tissue density around the arcus aortae, and particularly the main aortic branches. Concentric periaortic soft tissue was present beginning from the thoracic level and continuing at the abdominal level (Figure 1). Fibrotic soft tissue densities compatible with retroperitoneal fibrosis were observed in the retroperitoneal area, and particularly the perirenal area (Figure 2). Two renal arteries extending from the aorta to the left kidney were present, and we determined narrowing in the anterior branch at the outflow level. No pathology other than a mild increase in white blood cells was identified at routine biochemistry and hemogram. Mediastinal and

retroperitoneal fibrosis occurring in the processes of periaortitis were diagnosed based on the imaging findings. The patient was given medical treatment with steroids and subject to annual follow up.

DISCUSSION

Chronic periaortitis is a rare condition comprising idiopathic retroperitoneal fibrosis, perianeurysmal fibrosis and inflammatory abdominal aortic aneurysms, all with similar histopathological characteristics (5). Common features in all three conditions include atherosclerosis in the aorta, retroperitoneal fibrosis and adventitial inflammation (5). While it is more common in the middle age group and in males, it can also more rarely be seen in the elderly population and in children (6).

Various hypotheses have been proposed regarding the pathophysiology. Some authors have suggested immune response developing to atherosclerotic plaque

antigens. However, the presence of systemic clinical findings and comorbidity with autoimmune diseases cast doubt upon this hypothesis (3,4,6). Inflammatory aortic aneurysm, malignancy, smoking, drug use and exposure to asbestos are factors involved in the etiology. Another factor in the etiology is IgG4-related diseases presenting with an increase in serum IgG4, fibrosis and obliterative phlebitis (3). It may also accompany some rheumatic diseases involving autoimmunity; acute phase reactant levels may increase in these cases, or autoantibodies may be positive (5). Our patient was a 50-year-old male, and these demographic characteristics were compatible with the literature. He had no autoimmune disease, exposure to asbestos or vascular aneurysm, but chronic smoking, atherosclerotic changes in the aorta and increased emphysematous aeration were noted.

Retroperitoneal fibrosis is a rare disease characterized by fibrosis/inflammation in retroperitoneal tissue, and 2/3 cases are regarded as idiopathic. It is characterized by hard fibrous plaques surrounding vascular structures and the ureters in the retroperitoneal region (5,7). Gilkeson et al. reported an incidence of less than 1 in 100,000 (7). An underlying cause may be identified in only 1/3 cases. These include malignities, drugs, particularly ergot alkaloids and methysergide, aortic aneurysm, Crohn's disease, radiotherapy and periaortitis (2,6). A diffuse desmoplastic response to retroperitoneal metastases occurs in malignity-related retroperitoneal fibrosis (7). Clinical findings frequently appear due to compression of retroperitoneal structures. Soft tissue surrounding the aorta compatible with periaortitis and extending from the thoracic to the abdominal levels was present in our case.

Mediastinal fibrosis is a pathology characterized by proliferation of fibrotic tissue in the visceral compartment compressing mediastinal structures such as the major vessels, airways and esophagus. Infections, particularly involving histoplasma capsulatum, and mediastinal irritation can also lead to this condition (3). Mediastinal fibrosis may occur through transdiaphragmatic passage in cases of primary retroperitoneal fibrosis. Light reported comorbidity of retroperitoneal fibrosis and mediastinal fibrosis in two cases (8). Cases of comorbidity of these two rare conditions suggest that autoimmune mechanisms and similar pathophysiological processes are involved in predisposed individuals (9).

Diagnosis of chronic periaortitis is based on imaging techniques. Isolated periaortitis appears as a soft tissue mass surrounding the aorta at CT, frequently similar in density to that of muscle tissue. At MRI, periaortitis is hypointense on T1W series and hyperintense

on T2W series (5). Retroperitoneal fibrosis may be observed as a frequently lobulated contoured mass with distinct margins, hypoechoic or anechoic in character, surrounding the aorta at USG, although the sensitivity is low (5,10). Fibrosis appears as a mass lesion with distinct margins, located in the retroperitoneal area and exhibiting contrast at CT and MRI. Contrast enhancement varies depending on the character of the fibrotic tissue. There may be

little or no contrast enhancement in the chronic period (10).

The underlying malignancy, infection or predisposing factors such as drug use must be eliminated during treatment. Additionally, a significant proportion of such cases benefit from steroid therapy. Immunosuppressive agents such as medroxyprogesterone acetate and tamoxifen are used in refractory cases (11).

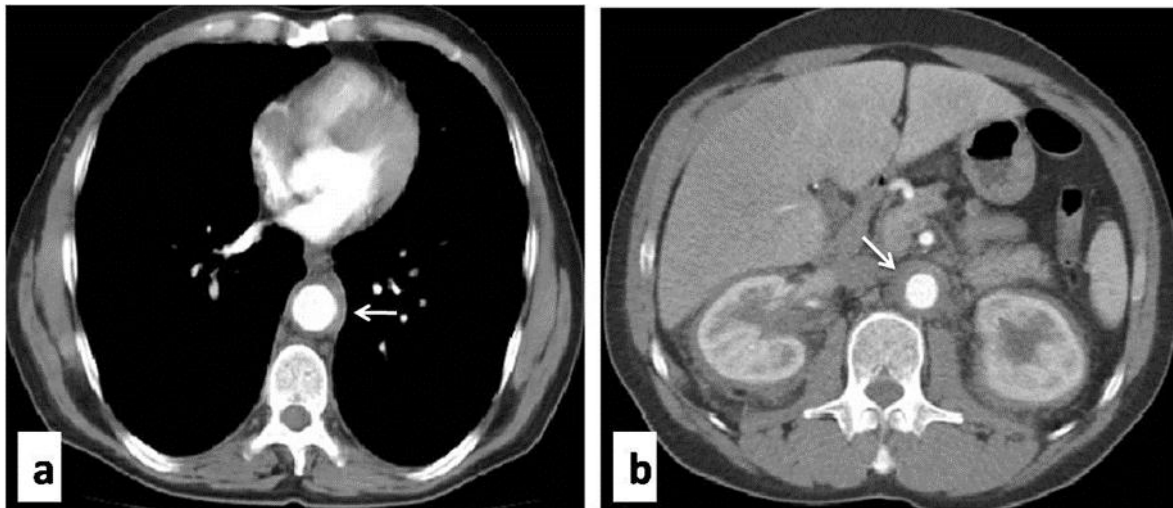


Figure 1: Axial thoracic and abdominal sections showing perivascular soft tissue density

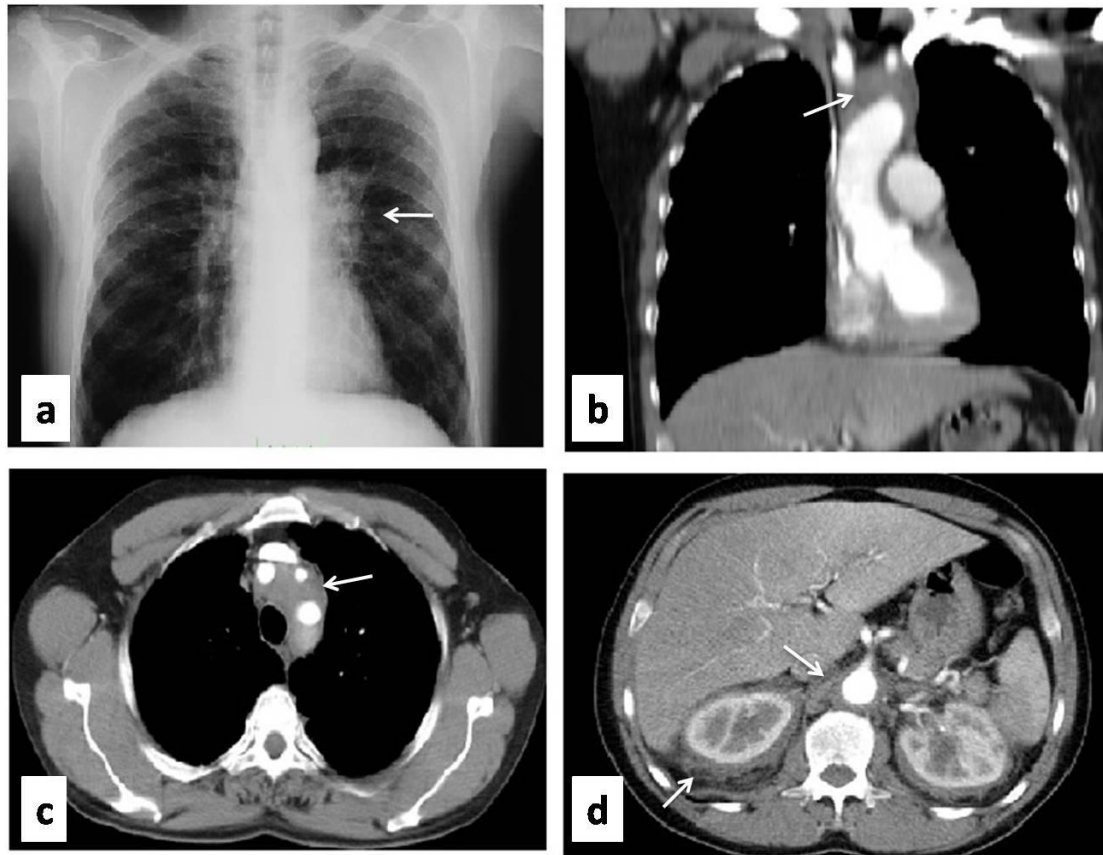


Figure 2: Enlargement of the left hilum at PA chest radiography (a), fibrosis in the superior mediastinum on coronal (b) and axial (c) sections at CT and retroperitoneal fibrosis in abdominal sections (d)

REFERENCES

- 1) Comings DE, Skubi KB, Van Eyes J, Motulsky AG. Familial multifocal fibrosclerosis: findings suggesting that retroperitoneal fibrosis, mediastinal fibrosis, sclerosing cholangitis, Riedel's thyroiditis, and pseudotumor of the orbit may be different manifestations of a single disease. *Ann Intern Med* 1967; 166 (5): 884-92.
- 2) Labidi J, Ariba YB, Chargui S, Bousetta N, Louzir B, Othmani S. Retroperitoneal fibrosis: A retrospective review of clinical presentation, treatment and outcomes. *Saudi J Kidney Dis Transpl* 2015;26 (4):816-22.
- 3) Kato T, Minamino E, Nakane E, Miyamoto S, Izumi T, Haruna T, Nohara R, Inoko M. The differential diagnosis of two cases of chronic periaortitis. *Case report Radiol.* 2013;2013:282067.
- 4) Vaglio A, Buzio C. Chronic periaortitis: a spectrum of diseases. *Curr Opin Rheumatol* 2005;17(1):34-40.
- 5) Zeina AR, Gleb S, Naschitz JE, Loberman Z, Barmeir E. Isolated periaortitis: clinical and imaging characteristics. *Vasc Health Risk Manag* 2007;3:1083-6.
- 6) Vaglio A, Coraddi D, Manenti L et al. Evidence of autoimmunity in chronic periaortitis: a prospective study. *Am J Med* 2003;114(6):454-62
- 7) Gilkeson GS, Allen NB: Retroperitoneal fibrosis: a true connective tissue disease. *Rheum Dis Clin North Am* 1996;22(1): 23-38
- 8) Light AM. Idiopathic fibrosis of mediastinum: a discussion of three cases and review of the literature. *J Clin Pathol* 1978;31(1):78-79
- 9) Cadenas Menendez S, Escudero Bueno C, Gonzalez Budino T. Chylothorax associated with idiopathic mediastinal and retroperitoneal fibrosis. *Arch Bronconeumol* 2009;45(10):527-8.
- 10) Cronin CG, Lohan DG, Blake MA, Roche C, McCarthy P, Murphy JM. Retroperitoneal fibrosis: a review of clinical features and imaging findings. *AJR Am J Roentgenol* 2008;191(2):423-31.
- 11) Elinav H, Hershko A, Leibovitch G, Naparstek Y. Retroperitoneal fibrosis-clinical response to steroid treatment. *Harefuah* 2003;142(3):166-9