



## Early fasciotomy due to compartment syndrome with gradual recovery of nerve function

### Kompartman sendromu nedeniyle erken fasiotomi yapılan hastada sinir fonksiyonlarının kademeli iyileşmesi

Kevser Tural,<sup>1</sup> Aykut Uyanık,<sup>2</sup> Zeynep Bilgi<sup>3</sup>

<sup>1</sup>Department of Cardiovascular Surgery, Kafkas University Faculty of Medicine, Kars, Turkey

<sup>2</sup>Department of Emergency Medicine, Pamukkale University Faculty of Medicine, Denizli, Turkey

<sup>3</sup>Department of Thoracic Surgery, Kars Harakani State Hospital, Kars, Turkey

#### Abstract

The incidence of gunshot wounds reported in the literature is higher than those reported for motor vehicle accidents, sports injuries, or industrial accidents. Vascular trauma of the lower extremities may lead to acute arterial insufficiency which requires rapid diagnosis and treatment. Compartment syndrome following vascular injury may also further complicate the process, increasing the risk of limb loss. In this article, we present the successful surgical treatment of a traumatic left anterior tibial artery complicated by compartment syndrome and eventual resolution of neural sequela. All effort should be made to minimize ischemia time in acute arterial injuries. Compartment syndrome may follow surgical repair even when ischemia time is low and the pulses were palpable during the entire clinical course. Clinical diagnosis and surgical exploration may be preferable instead of compartmental pressure recordings and observation in selected cases.

**Keywords:** Acute artery injury; gunshot wound; Drop foot; compartment syndrome.

The overall incidence of arterial injury following penetrating injury to the extremities is approximately 10%.<sup>[1]</sup> Lower extremity artery injuries may lead to adverse outcomes like pseudoaneurysm, arteriovenous fistula, dissection, thromboemboli, stenosis. If not properly managed, these injuries can cause compartment syndrome, eventual limb loss or death.<sup>[2]</sup>

In this article, we present the successful surgical treatment of a traumatic left anterior tibial artery (ATA) complicated by compartment syndrome despite rapid diagnosis/surgical treatment and eventual resolution of neural sequela.

#### Özet

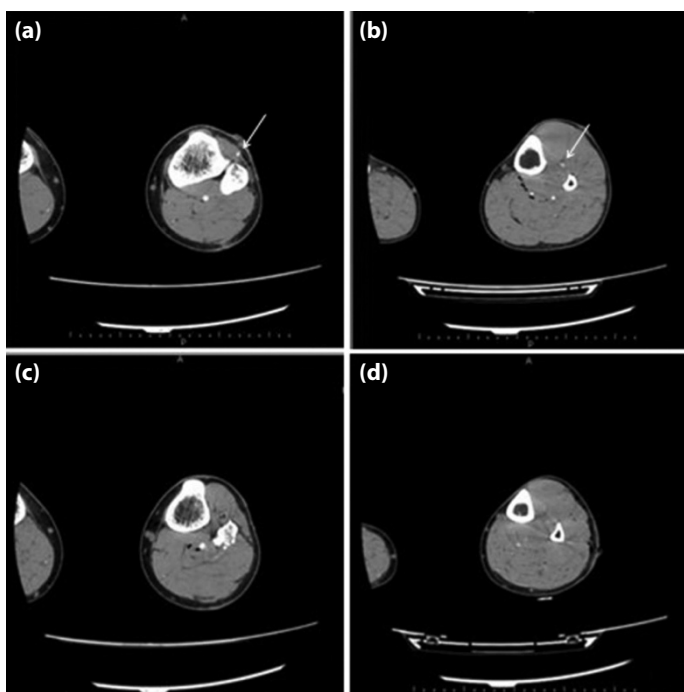
Literatürde bildirilen ateşli silah yaralanmalarının insidansı motorlu araç kazaları, spor yaralanmaları veya endüstriyel kazalar için bildirilenlerden daha yüksektir. Alt ekstremitelerin vasküler travması, hızlı tanı ve tedavi gerektiren akut arteriyel yetersizliğe neden olabilir. Vasküler yaralanmayı takiben kompartman sendromu da prosedürü daha komplike hale getirebilir ve ekstremitte kaybı riskini arttırır. Bu makalede, kompartman sendromu ile komplike olan travmatik bir sol ön tibial arterin başarılı cerrahi tedavisini ve sonuçta nöral sekelin çözümünü sunuyoruz. Akut arteriyel yaralanmalardaki iskemi süresini en aza indirmek için çaba göstermeliyiz. Kompartman sendromu, iskemi süresi düşükken bile cerrahi onarımı takip edebilir ve tüm klinik seyir boyunca nabızlar palpabl olabilir. Seçilmiş vakalarda kompartman basınç ölçümü yerine klinik tanı ve cerrahi eksplorasyon tercih edilebilir.

**Anahtar Sözcükler:** Akut arter hasarı; ateşli silah yaralanması; düşük ayak; kompartman sendromu.

#### Case Report

A 35-year-old male patient was admitted to Emergency Department with a one hour history of left lower extremity pain and paresthesia following a penetrating gunshot wound. A large, tense hematoma below the knee joint and bullet tract close to the anterior tibial artery were apparent in the clinical exam, however all lower extremity pulses were normal. Motor and sensory examinations were also normal. Within the first hour of observation, the lower extremity swelling progressed. Lower-extremity computed tomographic (CT) angiography showed ATA injury approximately 15 cm distal to the knee joint (Figure 1a–d).





**Figure 1.** (a) Bullet entry site. (b) Damaged fibular head. (c) Intact anterior and posterior tibial arteries after popliteal bifurcation. (d) Bullet exit site, muscular damage and absent ATA, intact posterior tibial artery. Vascular structure (arrows) which is seen in A and B was not observed in C and D.

Decision for surgical repair was made after appropriate informed consent. ATA was exposed through a longitudinal incision over the gunshot holes via retraction of the tibialis anterior and extensor digitorum longus muscles anteriorly. Proximal and distal control of the ATA was obtained and primary repair was performed.

Clinical examination in postoperative 4th hour revealed increased pain and rigidity in the involved extremity with new motor (drop foot) and sensory defect. Compartment syndrome was determined clinically and lower extremity fasciotomy was performed (Figure 2) after appropriate informed consent. Patient was discharged on postoperative day 7 after primary closure of fasciotomy defects. First week Doppler ultrasound revealed normal arterial flow, electromyography showed no conduction in peroneal nerve. At 6th month control electromyography was concurrent with partial chronic axonal damage in the peroneal nerve and the patient was doing well with complete resolution of drop foot on the involved side.

## Discussion

Lower extremity vascular trauma is a major risk factor for lower leg compartment syndrome. The diagnosis and decision to perform a fasciotomy procedure is still done largely on clinical basis as there is no consensus for threshold intracompartmental pressure.<sup>[3]</sup> Pressures over 30 mmHg



**Figure 2.** Fasciotomy defect and congested muscle tissue in postoperative day 1.

are considered critical for collapse of capillary perfusion, leading to nerve and muscle necrosis.<sup>[4-6]</sup> Some reports are more permissive for this occurrence like 40 mmHg in<sup>[7]</sup> and 50 mmHg in.<sup>[8]</sup>

Palpable pulses never rule out compartment syndrome as shown in the study of Mubarak et al, with all but one patient demonstrated palpable pulses and capillary refill, since the compartment pressures rarely rise above levels that would occlude a major artery.<sup>[6]</sup> Therefore, clinical examination (pain worsening with passive stretch, motor/sensory deficits, swelling, etc.) and intracompartmental pressure recordings are important in regards to diagnosis.

Speedy diagnosis and surgical treatment for compartment syndrome is necessary as the timing is shown to be a strong predictor of long lasting sequel and function loss.<sup>[9]</sup> The complete settlement of clinical picture usually results in tissue loss and inferior prognosis.<sup>[10]</sup> Fasciotomies executed within 12 hours of clinical symptoms are considered "early fasciotomies" and eventual normalization of extremity functions were demonstrated in 68% of the patients, whereas late fasciotomies only 8% of patients were able to gain normal functions. Serious complications, including bone and soft tissue infections, amputation, renal failure were seen in 4.5% and 54% in early vs late fasciotomies, respectively.<sup>[11]</sup>

In this case, compartment syndrome was unlikely, owing to the small size of the arterial injury, early diagnosis and an uncomplicated primary repair. Compartment syndrome was diagnosed clinically, fasciotomy and postoperative physical therapy/rehabilitation resulted in complete recovery of the motor functions at 6th month of surgery.

The aim of vascular injury repairing must be not only to save limbs, but also to decrease compartment syndrome and additional morbidities. All effort should be made to minimize ischemia time and all patients should be monitored for further complications. Clinical diagnosis and surgical exploration may be preferable instead of compartmental pressure recordings and observation in selected cases.

To conclude, low clinical suspicion threshold for complications is essential for treating limb/life threatening situations. Neural damage can be alleviated for minimal functional loss in the long term if the diagnosis/treatment were done in a timely fashion.

**Conflict of interest:** There are no relevant conflicts of interest to disclose.

**Financial Disclosure:** The authors declared that this study received no financial support.

## References

1. Rowe VL, Yellin AE, Weaver FA. Vascular Injuries of the Extremities. In: Rutherford RB, editor. *Vascular Surgery*. 7th ed. Philadelphia: Elsevier Saunders; 2010.
2. Finkelstein JA, Hunter GA, Hu RW. Lower limb compartment syndrome: course after delayed fasciotomy. *J Trauma* 1996;40:342–4.
3. Elliott KG, Johnstone AJ. Diagnosing acute compartment syndrome. *J Bone Joint Surg Br* 2003;85:625–32.
4. Byrnie J. Acute limb ischemia. In: Hallett JW, Mills JL, Earnshaw JJ, Reekers TW, editors. *Comprehensive Vascular and Endovascular Surgery*. 2nd ed. Philadelphia: Mosby; 2009. p. 282.
5. Hargens AR, Akeson WH, Mubarak SJ, Owen CA, Evans KL, Garetto LP, et al. Fluid balance within the canine anterolateral compartment and its relationship to compartment syndromes. *J Bone Joint Surg* 1978;60:499–505.
6. Mubarak SJ, Owen CA, Hargens AR, Garetto LP, Akeson WH. Acute compartment syndromes: diagnosis and treatment with the aid of the wick catheter. *J Bone Joint Surg Am* 1978;60:1091–5.
7. Koman LA, Hardaker WT Jr, Goldner JL. Wick catheter in evaluating and treating compartment syndromes. *South Med J* 1981;74:303–9.
8. Gelberman RH, Szabo RM, Williamson RV, Hargens AR, Yaru NC, Minter-Convery MA. Tissue pressure threshold for peripheral nerve viability. *Clin Orthop Relat Res* 1983;178:285–91.
9. Özbek S, Bozkurt C. Fasciotomy in the Lower Extremity: Its Indications and Technique [Article in Turkish]. *Uludağ Üniversitesi Tıp Fakültesi Dergisi* 2003;29:41–4.
10. Frykberg ER. Popliteal vascular injuries. *Surg Clin North Am* 2002;82:67–89.
11. Sheridan GW, Matsen FA 3rd. Fasciotomy in the treatment of the acute compartment syndrome. *J Bone Joint Surg Am* 1976;58:112–5.