

## Brunner's gland adenoma: A rare case report

Brunner gland adenomu: Olgu Sunumu

Şehmus ÖLMEZ<sup>1</sup>, Bünyamin SARITAŞ<sup>2</sup>, Süleyman SAYAR<sup>3</sup>, İbrahim ARAS<sup>4</sup>

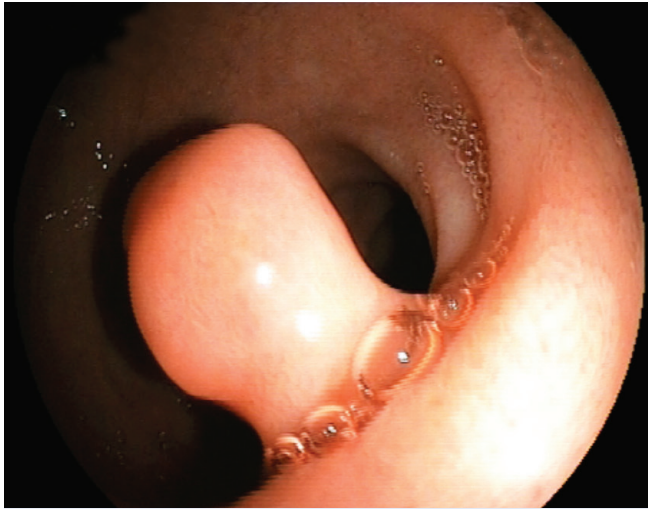
Yüzüncü Yıl University, School of Medicine, <sup>1</sup>Departments of Gastroenterology, <sup>4</sup>Pathology, Van Muş State Hospital, <sup>2</sup>Department of Gastroenterology, Muş Dr. Ersin Aslan State Hospital, <sup>3</sup>Department of Gastroenterology, Gaziantep

*Brunner's gland adenoma is a rare, benign lesion of the duodenum that is usually small in size and asymptomatic. Here we report a case treated with endoscopic polypectomy following adrenaline injection.*

**Key words:** Brunner's gland adenoma

### INTRODUCTION

Brunner's gland adenoma (BGA), also known as Brunneroma or Brunner's gland hamartoma, is a rare, benign lesion developing mostly in the posterior wall of the duodenum. It is usually small in size and asymptomatic. Endoscopic polypectomy is the first choice of treatment of small or pedunculated lesions (1). We report on a patient with a BGA who was successfully treated with endoscopic polypectomy following injection therapy with adrenaline solution.




**Figure 1.** Endoscopic view of the pedunculated polyp in postbulbar duodenum

*Brunner gland adenomu duodenumun nadir görülen benign lezyonlarından- dır. Genellikle küçük ve asemptomatiktir. Endoskopik polipektomi küçük veya saplı lezyonların tedavisinde ilk seçenektir. Burada adrenalin enjeksiyonu sonrası polipektomi yaptığımız bir olguyu sunuyoruz.*

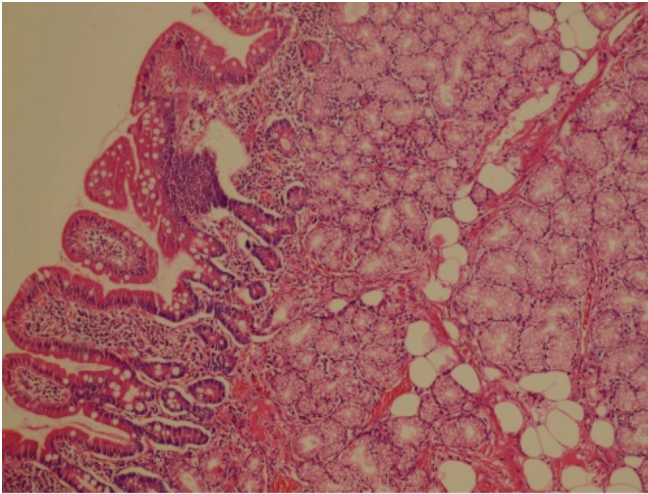
**Anahtar kelimeler:** Brunner gland adenomu

### CASE

A 51-year-old man was admitted to our hospital with dyspeptic symptoms for 3 months prior to admission. On admission, the patient's physical examination and routine laboratory tests were normal. Endoscopy revealed a pedunculated polyp the size of 15 mm in the postbulbar duodenum (Figure 1). The polyp was successfully removed with endoscopic polypectomy following injection therapy with 1:10000 adrenaline solution (Figure 2). The final histopathological diagnosis of this polyp was BGA (Figure 3).



**Figure 2.** View of the excised polyp



**Figure 3.** Histological examination revealing Brunner's gland's hyperplasia within adipous tissue in the duodenal submucosa (H&E stain, X100).

## DISCUSSION

BGA is a very rare benign tumor of the duodenum that was first described by Cruveillhier in 1835. At present, fewer than 200 cases have been reported in the medical English

literature (2). The patients are usually asymptomatic or may have nonspecific complaints such as nausea, bloating or vague abdominal pain; generally the tumor is discovered incidentally during endoscopy. Some patients with BGA may present with gastrointestinal bleeding or obstructive symptoms (1,2). BGA's are mostly benign and only two cases of carcinoma arising from BGA have been reported in the literature (3,4).

Diagnosis of BGA is not always easy. Endoscopy of pinching biopsies are usually nondiagnostic. Since it has malignant potential (1,2), total excision of the suspected BGA is recommended both to confirm the diagnosis as well as to avoid potential complications such as obstruction and bleeding (5). Endoscopic or surgical removal is the treatment of choice. Endoscopic resection of BGA is less invasive and more cost effective than surgery (1,2,5). Endoscopic removal can be done in most cases and surgical intervention is rarely needed. In our case, diagnosis was made by total excision of the lesion and no complications related to endoscopic polypectomy were observed.

In conclusion, endoscopic polypectomy is simple, effective, safe and a minimally invasive method to treat pedunculated lesions that are suspected BGAs.

## REFERANSLAR

1. So CS, Jang HJ, Choi YS, et al. Giant Brunner's gland adenoma of the proximal jejunum presenting as iron deficiency anemia and mimicking intussusceptions. *Clin Endosc* 2013;46:102-5.
2. Rocco A, Borriello P, Compare D, et al. Large Brunner's gland adenoma: case report and literature review. *World J Gastroenterol* 2006;12:1966-8.
3. Christie AC. Duodenal carcinoma with neoplastic transformation of the underlying Brunner's glands. *Br J Cancer* 1953;7:65-7.
4. Fujimaki E, Nakamura S, Sugai T, Takeda Y. Brunner's gland adenoma with a focus of p53-positive atypical glands. *J Gastroenterol* 2000;35:155-8.
5. Lee WC, Yang HW, Lee YJ, et al. Brunner's gland hyperplasia: treatment of severe diffuse nodular hyperplasia mimicking a malignancy on ancreatic-duodenal area. *J Korean Med Sci* 2008;23:540-3.