

Rectus sheath hematoma after abdominal trauma with snowball: A case report

Kartopu ile karın travması sonrası rektus kılıf hematomu: Olgu sunumu

Yasemin Kayadibi¹, Deniz Esin Tekcan Şanlı², Emel Ure Esmerer³, Suna Ors¹

¹ Van Training and Research Hospital,
Department of Radiology, Edremit, Van,
Turkey

² Kahramanmaraş Necip Fazıl State
Hospital, Department of Radiology,
Dulkadiroğlu, Kahramanmaraş, Turkey

³ Cerrahpaşa Medical Faculty,
Department of Radiology,
Kocamustafapasa, İstanbul, Turkey

ORCID ID of the authors

YK: 0000-0003-1590-5382

DETS: 0000-0002-6545-5757

EUE: 0000-0002-8273-976X

SO: 0000-0001-5027-186X

Corresponding author / Sorumlu yazar:

Yasemin Kayadibi

Address / Adres: Van Eğitim ve Araştırma
Hastanesi, Radyoloji Anabilim Dalı, Edremit,
Van, Türkiye
e-Mail: ysmnkayadibi@gmail.com

Informed Consent: The author stated that the
written consent was obtained from the patient
presented in the study.

Hasta Onamı: Yazar çalışmada sunulan hastadan
yazılı onam alındığını ifade etmiştir.

Conflict of Interest: No conflict of interest was
declared by the authors.

Çıkar Çatışması: Yazarlar çıkar çatışması
bildirmemişlerdir.

Financial Disclosure: The authors declared that
this study has received no financial support.
Finansal Destek: Yazarlar bu çalışma için finansal
destek almadıklarını beyan etmişlerdir.

Received / Geliş tarihi: 06.06.2018

Accepted / Kabul tarihi: 26.09.2018

Published / Yayın tarihi: 12.11.2018

Copyright © 2018 The Author(s)

Published by JOSAM

This is an open access article distributed under the terms of the Creative
Commons Attribution-Non Commercial-NoDerivatives License 4.0 (CC
BY-NC-ND 4.0) where it is permissible to download, share, remix,
transform, and buildup the work provided it is properly cited. The work
cannot be used commercially without permission from the journal.



Abstract

The rectus sheath hematoma (RSH) is the most common benign disease of the rectus abdominis muscle (RAM), but is one of the rare causes of acute abdominal pain. Mostly it is misdiagnosed with other causes of acute abdomen. A 65-year-old man admitted to our emergency service with complaints of localized abdominal pain and swelling after snowball playing and he had no anticoagulant drug history. He was diagnosed as RSH by computed tomography (CT) imaging. In elderly patient population, the clinician should be awake about RSH if the patient presented with local abdominal pain and infra abdominal mass. Early diagnosis by CT imaging is very important for exact diagnosis for prevention from unnecessary surgical procedures.

Keywords: Computer tomography, Rectus sheath hematoma, Snowball

Öz

Rektus kılıfı hematomu (RKH) rektus abdominis kasının (RAK) en sık benign hastalığı olmakla birlikte akut karın ağrısının nadir bir nedenidir. Genellikle diğer akut batın patolojileri ile karışır. Antikoagülan ilaç öyküsü olmayan 65 yaşında erkek hasta kartopu oynadıktan sonra batında şişlik ve karın ağrısı şikayeti ile hastanemizin acil servisine başvurdu. Bilgisayarlı tomografi (BT) görüntülemesi ile RKH tanısı konuldu. Lokal karın ağrısı ve infra abdominal kitle ile başvuran yaşlı hastalarda klinisyen RKH açısından dikkatli olmalıdır. Gereksiz cerrahi tedaviden kaçınmak için BT inceleme ile erken teşhis önemlidir.

Anahtar kelimeler: Bilgisayarlı tomografi, Rektus kılıfı hematomu, Kartopu

Introduction

The rectus sheath hematoma (RSH) is the most common benign disease of the rectus abdominis muscle (RAM). Hematoma may occur either by bleeding into the sheath secondary to inferior or superior epigastric artery injury or by primary RAM rupture [1,2]. RSH is usually seen in older women, but younger case reports have also been reported [3]. The most common predisposing factor is the usage of anticoagulant drugs in these elderly patients with cardiac comorbidities. Local trauma, hypertension, atherosclerosis, chronic cough, epigastric vessel injury during trocar insertion are other reported etiologies [4]. Herein we report a very interesting case of RSH caused by throwing a snowball which has not been reported yet.

Case presentation

A 65-year-old man referred to our clinic with complaints of left-paramedian sided swelling and pain. In his history, it was learned that the one day before, when he was playing snowball a sudden pain and following swollen in his abdominal wall was occurred. The patient had no known chronic disease and there was no such thing as anticoagulant use or bleeding diathesis. On physical examination, there was a swelling in the left mid-lower quadrant of his abdomen. The laboratory findings were within normal limits. Abdominal computed tomography (CT) scans showed relatively hyperdense hematoma in his left rectus sheath which was extending to transverse and oblique abdominal muscles. In addition, extravasation of contrast material posteriorly in the left rectus sheath was also noted after contrast injection (Figure 1-3). The patient was diagnosed with type 2 RSH and followed conservatively. In his daily following sonographic imagines the decrease in hematoma size was revealed.

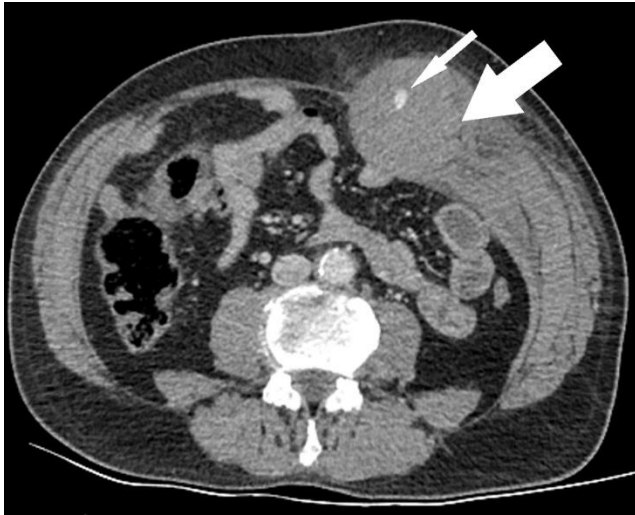


Figure 1: Axial contrast-enhanced abdominopelvic CT shows relatively hyper dense left sided RSH that extending to transverse and oblique abdominal muscles and fascias (thick arrow). Note the contrast extravasation (thin arrow)

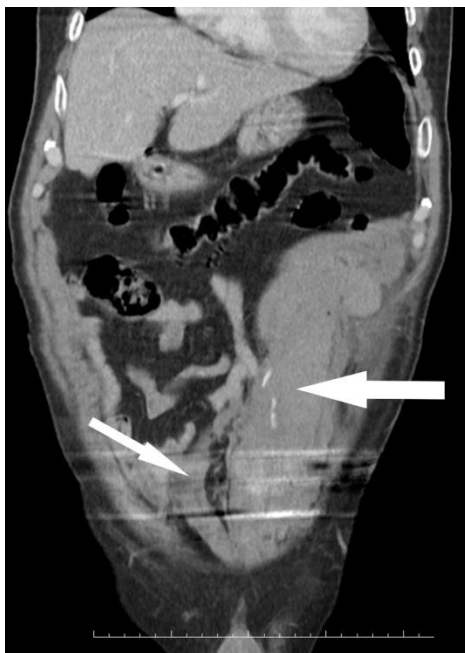


Figure 2: Coronal CT image shows left-sided infra-arcuate line located RSH and contrast extravasation (thick arrow). Right rectus abdominis is in normal size (thin arrow)

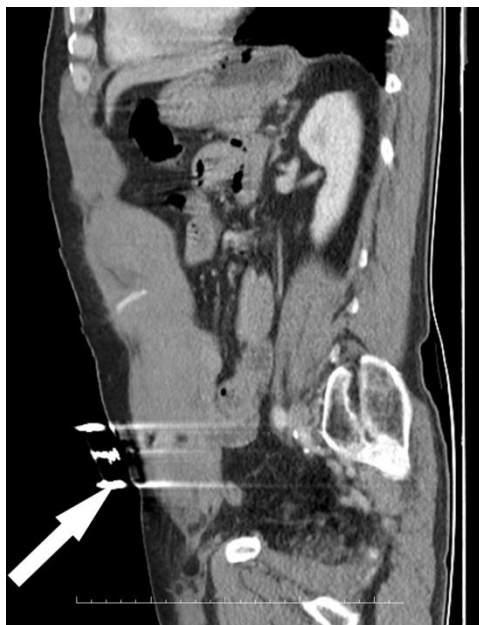

Figure 3: Sagittal CT image shows the extension of RSM to the level below the umbilicus (arrow).

Discussion

RSH usually presents with acute local abdominal pain and swelling. If the measures of the hematoma are above 5 cm, the pain affects general abdomen, thus RSH could be misdiagnosed as other acute abdominal clinics [4]. Except for abdominal pain, abdominal wall swelling, ecchymosis, fever, nausea, vomiting, distension, and cramps could be other presenting symptoms. Abdominal wall swelling is the most important finding in clinical examination. Fothergill and Carnet sign may be helpful in understanding whether the stiffness is caused from by the abdominal wall or from the intraabdominal pathologies. If the swelling doesn't change with RAM's flexion and doesn't extend to cross, this is probably a positive finding for RSH (Fothergill sign). Another clinical finding is the increase of abdominal pain and sensitivity with RAM contraction (Carnet sign). Additionally, there would be no general condition disorder in patients with RSH unlike other acute abdominal pathologies [5]. RAM is divided into two main parts by arcuate line. Above the arcuate line, rectus sheath is supported by aponeurosis of oblique and transversal abdominal muscles. Below the arcuate line, this aponeurosis continues with the anterior part of the sheath but the posterior part of the sheet supported only by the layer from the transverse abdominal muscle. For this reason, the sheath is relatively weak in the posterior part below the arcuate line. Inferior and superior epigastric arteries provide an intensive vascular network by anastomosing at the umbilicus level. The hematoma usually occurs in the lower and posterior part of the sheath. In addition, strong muscle contractions are more susceptible to damage arterial structures because of their better adhesion to the muscle at this level [2].

Three types of RSH are described according to CT findings. Type 1: intramuscular and unilateral, type 2: bilateral intramuscular with extension to transverse fascia, type 3: intra- or extra-muscular, with perivesicular or intraperitoneal extension [6].

Hemoglobin value and patients clinic usually stay stable in type 1 RSH while in type 2 hematoma minor changes seen in hemoglobin value. Hematologic instability usually develops in Type 3 hematomas [6]. If the patient is stable, type 1 and 2 rectus sheath hematomas can be followed by supportive treatment such as resting, analgesia, anticoagulation, and transfusion. If the patient is unstable, surgical operation and ligation of the arterial supply should be considered. Percutaneous arterial embolization may be performed if hemorrhage is recurring. Removal of the hematoma is not always necessary as it may deactivate the tamponade effect and cause uncontrolled hemorrhage [2].

USG is the first choice imaging method in the patient presenting with abdominal pain; because it is easy, inexpensive and x-ray- free. However, USG is insufficient in an intraabdominal or extraabdominal distinction of the mass [5]. Due to the higher sensitivity and specificity, CT scan is the gold standard in the diagnosis of RSM. It has relatively hyperdense mass appearance relative to the muscle leading to expansion. Active bleeding can be seen with contrast injection. The detection of fluid densities in the abdomen is suspicious for intraperitoneal rupture. Follow-up ultrasound can also be used for patients requiring long-term follow-up [3]. Hypovolemic shock, infection, abdominal compartment syndrome,

myonecrosis, acute renal failure, small bowel infarction, and death have been reported complications of RSH [2].

The prevalence of RSH which was rarely seen in the past is rapidly increasing, due to the increased usage of anticoagulants in the elderly population. For the clinician to be awake for the patients who are suffering from swelling and pain on the abdominal wall and choose CT scan first is very important for exact diagnosis.

References

1. Lambroza A, Tighe MK, DeCosse JJ, Dannenberg AJ. Disorders of the rectus abdominis muscle and sheath: a 22-year experience. *Am J Gastroenterol.* 1995;90:1313e7.
2. Fitzgerald JE, Fitzgerald LA, Anderson FE, Acheson AG. The changing nature of rectus sheath haematoma: case series and literature review. *Int J Surg.* 2009 Apr;7(2):150-4.
3. Matalon SA, Askari R, Gates JD, Patel K, Sodickson AD, Khurana B. Don't Forget the Abdominal Wall: Imaging Spectrum of Abdominal Wall Injuries after Nonpenetrating Trauma. *Radiographics.* 2017 Jul-Aug;37(4):1218-35.
4. Salemis NS, Gourgiotis S, Karalis G. Diagnostic evaluation and management of patients with rectus sheath hematoma. A retrospective study. *Int J Surg.* 2010;8(4):290-3.
5. Topaloğlu S, Aras D, Kaya V, Çağlı K, Özcan F, Korkmaz Ş. Enoksaparine Bağlı Rektus Kılıfı Hematomu. *Türkiye Klinikleri Cardiovascular Sciences.* 2006:94-6.
6. Berna JD, Garcia-Medina V, Guirao J, Garcia-Medina J. Rectus sheath haematoma: diagnostic classification by CT. *Abdom Imaging.* 1996;21:62-4.