

## Relationship Between Epicardial Adipose Tissue Thickness and Fragmented QRS



Ali Rıza Akyüz, Selim Kul, Muhammet Raşit Sayın, Turhan Turan, Levent Korkmaz

University of Health Sciences, Ahi Evren Chest and Cardiovascular Surgery Training and Research Hospital, Clinic of Cardiology, Trabzon, Turkey

### ABSTRACT

**Introduction:** Fragmented QRS (fQRS) on a 12-lead electrocardiogram (ECG) has been demonstrated as a marker of myocardial fibrosis. The main purpose of present study was to investigate the association between epicardial adipose tissue (EAT) and fQRS.

**Patients and Methods:** Study population consisted of 151 patients had fQRS detected on a routine 12-lead ECG and 114 controls without fQRS. EAT was assessed by measuring epicardial fat thickness with echocardiography. fQRS was defined by the presence of various RSR' patterns included an additional R wave (R), notching of the R wave, notching of the downstroke or upstroke of the S wave, or the presence of > 1 R in 2 contiguous leads corresponding to a major coronary artery territory.

**Results:** Patients with fQRS had higher EAT values than those without fQRS ( $5.9 \pm 2.7$ ,  $3.8 \pm 2.3$ ,  $p < 0.001$ ). Univariate analyses demonstrated significant association between fQRS and EAT ( $p < 0.001$ ), hypertension ( $p = 0.015$ ). Binary logistic regression analysis revealed EAT (95% confidence interval [CI] 1.053-1.938,  $p = 0.022$ ) and total cholesterol (95% CI: 1.001-1.030,  $p = 0.037$ ) as independent determinants of fQRS.

**Conclusion:** In the present study, we found higher amounts of EAT in subjects with fQRS. In addition, presence of fQRS was independently associated with EAT.

**Key Words:** fQRS; epicardial adipose tissue; myocardial fibrosis

### Epikardiyal Yağ Dokusu Kalınlığı ve Parçalı QRS Arasındaki İlişki

#### ÖZET

**Giriş:** On iki kanallı elektrokardiyografi (EKG)'de tespit edilen parçalı QRS (pQRS)'nin miyokart fibrozunun bir belirtici olduğu gösterilmiştir. Bu çalışmanın amacı epikardiyal yağ dokusu kalınlığı (EYK) ile pQRS arasındaki ilişkiyi incelemektir.

**Hastalar ve Yöntem:** Çalışmaya kardiyojloji polikliniğimize müracaat edip rutin elektrokardiyografik incelemede pQRS'si olan 151 hasta ve kontrol grubu olarak pQRS'si olmayan 114 hasta alındı. EYK ekokardiyografide hesaplandı. Parçalanmış QRS birbirini takip eden iki EKG derivasyonunda ilave R dalgası (R') veya R veya S dalgasında çentiklenme veya bölünme varlığı olarak alındı.

**Bulgular:** pQRS olan hastalarda EYK değerleri daha yüksekti ( $5.9 \pm 2.7$ ,  $3.8 \pm 2.3$ ,  $p < 0.001$ ). Tek değişkenli analiz EYK ile pQRS ( $p < 0.001$ ) ve hipertansiyon ( $p = 0.015$ ) arasında anlamlı bir ilişki olduğunu göstermiştir. Binary lojistik regresyon analizi, EYK [%95 güven aralığı (GA) 1.053-1.938,  $p = 0.022$ ] ve total kolesterolü (%95 GA: 1.00-1.030,  $p = 0.037$ ) pQRS'nin bağımsız bir belirleyicisi olarak ortaya koydu.

**Sonuç:** Bu çalışmada, pQRS'li hastalarda EYK'yi artmış olarak tespit ettik. Buna ek olarak EYK, pQRS'nin güçlü ve bağımsız bir belirtici olarak bulunmuştur.

**Anahtar Kelimeler:** Parçalı QRS; epikardiyal yağ dokusu; miyokardiyal fibrozis

### INTRODUCTION

Fragmented QRS (fQRS) has been defined by the presence of various RSR patterns with or without a Q wave and included an additional R wave (R), notching of the R wave, notching of the downstroke or upstroke of the S wave, or the presence of > 1 R without a typical bundle-branch block in two contiguous leads, corresponding to a major coronary artery territory<sup>(1)</sup>. Several studies have demonstrated that fQRS on a routine 12-lead ECG signifies a myocardial scar in different clinical situations. In addition, fQRS represents conduction delay from inhomogeneous activation of the ventricles because of myocardial scarring<sup>(2-4)</sup>.

### Correspondence

Ali Rıza Akyüz

E-mail: dralirizaakyuz@gmail.com

Submitted: 19.11.2016

Accepted: 17.01.2017

© Copyright 2017 by Koşuyolu Heart Journal.  
Available on-line at  
www.kosuyoluheartjournal.com

Epicardial adipose tissue (EAT) is true visceral fat deposit that presents on the cardiac surface between the visceral pericardium and myocardium, and it covers more than three quarters of the cardiac surface<sup>(5)</sup>. Because of its paracrine and endocrine activity, secreting proinflammatory and anti-inflammatory chemokines and cytokines, including interleukin-6, interleukin-1 $\beta$ , tumor necrosis factor- $\alpha$ , and monocyte chemoattractant protein-1, it causes both structural and ultrastructural changes in the myocardium, such as increased LV mass, development of coronary atherosclerosis, atrial enlargement, and diastolic dysfunction<sup>(5-8)</sup>, which may lead to the development of fQRS. However, the relationship between EAT and fQRS has not been investigated. Thus, the purpose of present study was to investigate this association in patients without known structural heart disease.

## PATIENTS and METHODS

### Patients

Study population consisted of 151 patients had fQRS detected on a routine 12-lead ECG and 114 controls without fQRS. Exclusion criteria were the presence of structural heart disease including known coronary artery disease (previous myocardial infarction, percutaneous coronary intervention coronary bypass and angina pectoris), heart failure (ejection fraction < 50%), dilated or hypertrophic cardiomyopathy, moderate and severe valvular disease, valve replacement, and poor echocardiographic imaging. Patients were defined as hypertensive when blood pressure was > 140/90 mmHg or if they used antihypertensive medications. Demographic data, biochemical blood tests, and ECG were obtained from the entire study population. Informed consent was obtained from all participants and the study protocol was approved by the Ethics Committee of the Trabzon Kanuni Training and Research Hospital.

### Electrocardiography

All standard 12-lead ECGs were obtained simultaneously using a recorder set at a 25 mm/s paper speed and a voltage calibration of 1 mV/cm (Nihon Kohden-Cardiofax S ECG-1250 K, filter range 0.5-150 Hz, alternating current filter 60 Hz). All examinations were carried out in a quiet room during spontaneous breathing, following 10 min of rest in the supine position. ECGs were each numbered and presented to the analyzing investigators who were blind both to patient name and group information. ECG assessments were made by two medically qualified observers blind to the patient name and group. fQRS was defined by the presence of various RSR' patterns included an additional R wave (R), notching of the R wave, notching of the downstroke or upstroke of the S wave, or the presence of > 1 R' in 2 contiguous leads corresponding to a major coronary artery territory.

### Measurement of EAT

EAT thickness was evaluated by transthoracic echocardiography. Two-dimensional transthoracic echocardiography in the left lateral decubitus position was performed by a Vivid S5 cardiovascular ultrasound system (GE Healthcare, Wauwatosa, WI, USA). Measurements were performed by an experienced physician who was unaware of the subjects' clinical and demographic data. Epicardial fat was defined as an echo-free space in front of the RV free wall between the outer wall of the myocardium and the pericardial layer. Epicardial fat thickness was measured perpendicularly on the RV free wall at end diastole. Aortic annulus was used as anatomical reference to standardize the measurement point. All measurements were performed for three consecutive cardiac cycles and an average value was obtained. For the parasternal short-axis view, epicardial adipose tissue thickness was measured on the RV free wall along the midline of the ultrasound beam, 2 cm from the ventricular septum (Figure 1).

### Statistical Analysis

Continuous variables were expressed as mean  $\pm$  standard deviation, and categorical variables were expressed as percentage. An analysis of normality of the continuous variables was performed with the Kolmogorov-Smirnov test. A comparison of the categorical variables between the groups was performed using a chi-square test. Continuous variables were compared using independent t-test and Mann-Whitney U-test. Binary logistic regression analysis was performed to find the independent determinant of fQRS. A  $p < 0.05$  (two-tailed) was considered significant. Statistical analysis was carried out using SPSS 17.0 statistical software. (SPSS Inc., Chicago, Illinois, USA).

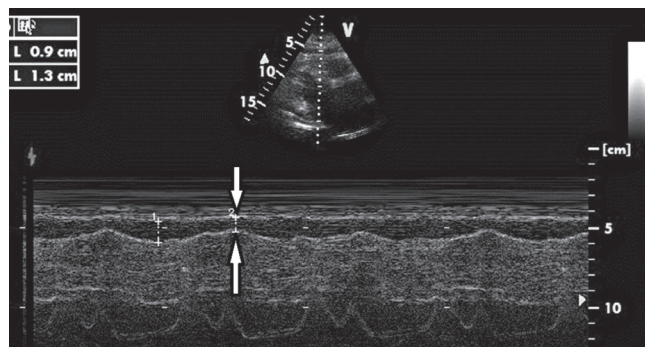
## RESULTS

A comparison of the clinical and laboratory characteristics between subjects with and without fQRS is shown in Table 1. Patients with fQRS had higher EAT values than those without fQRS ( $5.9 \pm 2.7$ ,  $3.8 \pm 2.3$ ,  $p < 0.001$ ) (Figure 2). In addition, in univariate analyses, there was significant association between fQRS and EAT ( $p < 0.001$ ), hypertension ( $p = 0.015$ ). Binary logistic regression analysis revealed EAT (95% confidence interval [CI] 1.053-1.938,  $p = 0.022$ ) and total cholesterol (95% CI: 1.001-1.030,  $p = 0.037$ ) as an independent determinant of fQRS (Table 2).

## DISCUSSION

In the present study, we found increased epicardial fat thickness in subjects with fQRS as compared to controls. It was also shown that EAT was independently associated with presence of fQRS.

fQRS on ECG has been regarded as a marker of myocardial fibrosis or scarring in different diseases and independent predictor of cardiac events in patients with coronary artery disease<sup>(9-11)</sup>.



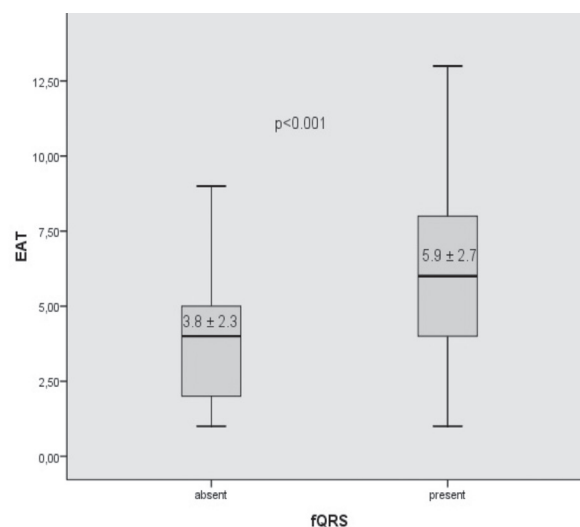
**Figure 1.** Measurement of epicardial fat by echocardiography.

Several studies have showed that the region of a myocardial fibrosis is associated with inhomogeneous activation of the left ventricle, leading to terminal conduction delays or fQRS<sup>(12,13)</sup>. Another study demonstrated that the fQRS complex on ECG is

**Table 1.** Comparison of clinical and laboratory characteristics between subjects with and without fragmented QRS

	fQRS absent (n= 114)	fQRS present (n= 151)	p
Age, years	53 ± 15	56 ± 13	0.027
Sex, F/M	59/55	82/69	0.68
BMI (kg/m <sup>2</sup> )	28.4 ± 5.1	29.1 ± 5	0.27
Diabetes mellitus, n (%)	7 (6)	18 (12)	0.11
Hypertension, n (%)	47 (41)	85 (56)	0.015
Dyslipidemia, n (%)	23 (20)	56 (37)	0.003
Current smokers, n (%)	13 (11)	18 (12)	0.89
Cardiovascular medications			
ACE inhibitors or ARB, n (%)	18 (16)	49 (32)	0.002
Calcium channel blockers, n (%)	8 (7)	14 (9)	0.51
β-Blockers, n (%)	11 (9)	14 (9)	0.91
Cholesterol-lowering drugs, n (%)	8 (7)	14 (9)	0.51
Oral antidiabetic drugs n (%)	6 (5)	18 (12)	0.06
Biochemical parameters			
Glucose (mg/dL)	94 ± 15	105 ± 46	0.048
Total cholesterol (mg/dL)	197 ± 48	212 ± 47	0.026
HDL-c (mg/dL)	49 ± 12	48 ± 12	0.64
LDL-c (mg/dL)	127 ± 37	130 ± 36	0.49
Triglyceride (mg/dL)	144 ± 77	168 ± 104	0.05
Serum creatinine (mg/dL)	0.75 ± 0.16	0.76 ± 0.21	0.84
Epicardial fat (mm)	3.8 ± 2.3	5.9 ± 2.7	<0.001

Data are expressed as no. (%) or mean ± standard deviation. ACE: Angiotensin-converting enzyme, ARB: Angiotensin receptor blocker, BMI: Body mass index, HDL-c: High-density lipoprotein cholesterol, LDL-c: Low-density lipoprotein cholesterol.



**Figure 2.** Epicardial adipose tissue thickness in subjects with and without fQRS.

**Table 2.** Binary logistic regression analysis showing independent factors associated with fragmented QRS

Variables	Variables 95% CI	p
Age	0.984-1.032	0.517
Hypertension	0.575-2.09	0.78
Diabetes	0.578-5.804	0.304
EAT	1.053-1.938	0.022
Total cholesterol	1.001-1.030	0.037
Triglyceride	0.996-1.004	0.928
LDL-c	0.968-1.000	0.053

EAT: Epicardial adipose tissue, LDL-c: Low-density lipoprotein cholesterol.

a highly sensitive and specific marker of myocardial scarring as detected by regional perfusion abnormalities on a nuclear stress test<sup>(1)</sup>. In addition, fQRS on a standard 12-lead ECG can be used in the detection of myocardial scar with higher sensitivity and negative predictive value than Q wave. Furthermore, simultaneous occurrence of fQRS and Q wave on 12-lead ECG improves the predictive value in predicting the presence of myocardial scar<sup>(14)</sup>.

EAT is visceral fat, which has a close interaction with the myocardium and coronary arteries. EAT also plays an important role in the inflammatory process in the cardiovascular system via its endocrine and paracrine activity<sup>(6,15)</sup>. Several studies showed that EAT is associated with a variety of disorders such as atherosclerosis, xanthelasma palpebrarum, hypertension, arterial stiffness, enlarged atrial and ventricular dimensions, ventricular premature beats, atrial fibrillation, and increased LV mass<sup>(16-20)</sup>.

Some potential mechanisms can be proposed to explain relationship between EAT and fQRS. EAT cause both structural and ultrastructural changes in the myocardium, which might be

considered as a possible mechanism. Iacobellis et al showed that EAT is associated with structural and ultrastructural myocardial changes, including myocardial fibrosis<sup>(20,21)</sup>. EAT also releases proinflammatory cytokines, including TNF- $\alpha$ , IL1- $\beta$ , and IL-6, and it has been supposed to influence both structural and ultrastructural change in myocardium including myocardial fibrosis<sup>(5,6,20)</sup>. Myocardial remodeling and fibrosis may produce some changes in action potential characteristics and predispose the fQRS on surface ECG.

#### Limitations of the Study

First, our study population was relatively small. Second, no evaluation of magnetic resonance imaging or computed tomography was performed to assess EFT. Third, detailed echocardiographic assessment including diastolic parameters, wall thickness and hypertrophy were not obtained. Earliest studies showed this association<sup>(20,21)</sup>. Finally, our study is a case-control study, and this study type has some limitations concerning matching methodology.

#### CONCLUSION

In the present study, we found higher amounts of EAT in subjects with fQRS. In addition, EAT was found to be independently associated with presence of fQRS. EAT thickness may be a new mechanism to explain fQRS pathogenesis. Further studies are required to explain the pathophysiological mechanism in fQRS and EAT.

#### CONFLICT of INTEREST

The authors reported no conflict of interest related to this article.

#### AUTHORSHIP CONTRIBUTIONS

*Concept/Design:* AA, SK, MS

*Analysis/Interpretation:* AA, TT, LK

*Data Acquisition:* AA, TT

*Writing:* AA, LK, SK

*Critical Revision:* SK, LK

*Final Approval:* All authors

#### REFERENCES

- Das MK, Khan B, Jacob S, Kumar A, Mahenthiran J. Significance of a fragmented QRS complex versus a Q wave in patients with coronary artery disease. *Circulation* 2006;113:2495-501.
- Jain R, Singh R, Yamini S, Das MK. Fragmented ECG as a risk marker in cardiovascular diseases. *Curr Cardiol Rev* 2014;10:277-86.
- Take Y, Morita H. Fragmented QRS: What is the meaning? *Indian Pacing Electrophysiol J* 2012;12:213-25.
- Ağaç MT, Korkmaz L, Bektas H, Acar Z, Erkan H, Kurt IH, et al. Increased frequency of fragmented QRS in patients with severe aortic valve stenosis. *Med Princ Pract* 2014;23:66-9.
- Bertaso AG, Bertol D, Duncan BB, Foppa M. Epicardial fat: definition, measurements and systematic review of main outcomes. *Arq Bras Cardiol* 2013;101:e18-e28.
- Talman AH, Psaltis PJ, Cameron JD, Meredith IT, Seneviratne SK, Wong DT. Epicardial adipose tissue: far more than a fat depot. *Cardiovasc Diagn Ther* 2014;4:416-29.
- Taguchi R, Takasu J, Itani Y, Yamamoto R, Yokoyama K, Watanabe S, et al. Pericardial fat accumulation in men as a risk factor for coronary artery disease. *Atherosclerosis* 2001;157:203-9.
- Iacobellis G, Ribaudo MC, Zappaterreno A, Iannucci CV, Leonetti F. Relation between epicardial adipose tissue and left ventricular mass. *Am J Cardiol* 2004;94:1084-7.
- Ma X, Duan W, Poudel P, Ma J, Sharma D, Xu Y. Fragmented QRS complexes have predictive value of imperfect ST-segment resolution in patients with STEMI after primary percutaneous coronary intervention. *Am J Emerg Med* 2016;34:398-402.
- Schuller JL, Olson MD, Zipse MM, Schneider PM, Aleong RG, Wienberger HD, et al. Electrocardiographic characteristics in patients with pulmonary sarcoidosis indicating cardiac involvement. *J Cardiovasc Electrophysiol* 2011;22:1243-8.
- Oner E, Erturk M, Birant A, Kalkan AK, Uzun F, Avci Y, et al. Fragmented QRS complexes are associated with left ventricular systolic and diastolic dysfunctions in patients with metabolic syndrome. *Cardiol J* 2015;22:691-8.
- Flowers NC, Horan LG, Thomas JR, Tolleson WJ. The anatomic basis for high-frequency components in the electrocardiogram. *Circulation* 1969;39:531-9.
- Friedman PL, Fenoglio JJ, Wit AL. Time course for reversal of electrophysiological and ultrastructural abnormalities in subendocardial Purkinje fibers surviving extensive myocardial infarction in dogs. *Circ Res* 1975;36:127-44.
- Dabbagh Kakhki VR, Ayati N, Zakavi SR, Sadeghi R, Tayyebi M, Shariati F. Comparison between fragmented QRS and Q waves in myocardial scar detection using myocardial perfusion single photon emission computed tomography. *Kardiol Pol* 2015;73:437-44.
- Matloch Z, Kotulak T, Haluzik M. The role of epicardial adipose tissue in heart disease. *Physiol Res* 2016;65:23-32.
- Aslanabadi N, Salehi R, Javadrashid A, Tarzamni M, Khodadad B, Enamzadeh E, et al. Epicardial and pericardial fat volume correlate with the severity of coronary artery stenosis. *J Cardiovasc Thorac Res* 2014;6:235-9.
- Akyüz AR, Ağaç MT, Turan T, Şahin S, Kul S, Korkmaz L, et al. Xanthelasma is associated with increased amount of epicardial adipose tissue. *Med Princ Pract* 2016;25:187-90.
- Korkmaz L, Cırakoglu OF, Ağaç MT, Erkan H, Korkmaz AA, Acar Z, et al. Relation of epicardial adipose tissue with arterial compliance and stiffness in patients with hypertension. *Angiology* 2014;65:691-5.
- Kırış A, Turan OE, Kırış G, İter A, Öztürk M, Aydın M, et al. The relationship between epicardial fat tissue thickness and frequent ventricular premature beats. *Kardiol Pol* 2015;73:527-32.
- Iacobellis G, Ribaudo MC, Zappaterreno A, Iannucci CV, Leonetti F. Relation between epicardial adipose tissue and left ventricular mass. *Am J Cardiol* 2004;94:1084-7.
- Iacobellis G, Leonetti F, Singh N, M Sharma A. Relationship of epicardial adipose tissue with atrial dimensions and diastolic function in morbidly obese subjects. *Int J Cardiol* 2007;115:272-3.