

A Case of Meningocele in an Akkaraman Lamb

Murat Tanrisever^{1*}, Emine Unsaldi¹

¹ Department of Surgery, Faculty of Veterinary, Firat University, Elazig, Turkey

*Corresponding Author

E-mail:mtanrisever@firat.edu.tr

Abstract

A meningocele case has been observed on a one-day-old male Akkaraman lamb, brought to the Surgery Clinic, Animal Hospital and University of Firat. When we examined the animal, there was a fluctuating mass about 15 cm diameter size in the occipital area. We decided to surgical operating to this case of meningocele which is rare and usually does not respond favorably to treatment. Under a general anesthesia firstly liquid was drained out from the mass by using cannula. Then the excess skin piece was removed with the incision in a controlled manner. Approximately 2 mm diameter hole was closed which opened into the medullary canal by using sutures. At the same time, processus spinosus of first cervical vertebrae was seen that the 2 cm longer than normal. After cutting the excess bone part, the head skin was sutured with using 2-0 suture. The patient received parenteral antibiotics for 5 days. After 2 months the operation, it was observed that he continued his life in a very healthy. This case was thought to report because it is a rarely seen type of anomaly in lamb and respond favorably to the operation in this case.

Keywords: Meningocele, Lamb, Surgery

INTRODUCTION

Structural and functional disorders that develop in the offspring due to various causes in the fetal and embryonic period are called birthing anomalies (1). Although the causes of congenital anomalies seen in ruminants cannot be determined precisely, it has been reported that these anomalies are caused by genetic factors, mutations, chromosome anomalies, infectious agents, environmental factors and mineral salts and vitamin (A, D, E) deficiency, hormonal factors and physical reasons or combinations of these factors (2-4) Although congenital anomalies are few in number, they are of great importance because they lead to significant economic losses and are genetically transferred to new generations (5).

Meningocele is the protrusion of fluidfilled meninges through a defect in the cranium (crania bifida) (6,7). Also the herniation of cranium meninges if it contains brain tissue together, it is called meningoencephalocele(8-10). Meningocele is a rare case of central nervous system anomalies are rarely found in cattle and cows, but pigs and cat are so rarely encountered (11).

Most of the defects in animals are under the control of autosomal recessive genes (12, 13). Recessive genes are transmitted from generation to generation through normal-looking parents (14). So that reason, even if they live, congenital anomaly animals and their parents should not be used as for breeding and must remove from the herd (15).

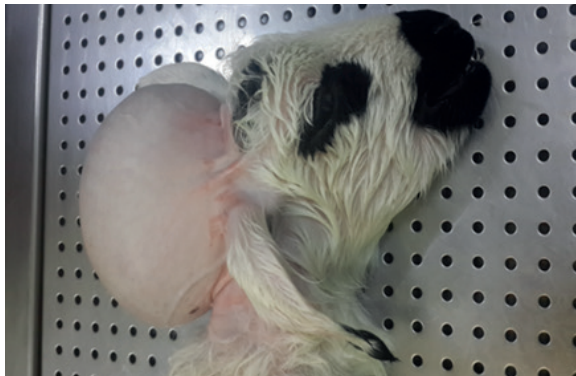

Figure 2. Side view of the case

MATERIALS AND METHODS

The study material was a one-day-old male Akkaraman lamb, brought to the Surgery Clinic, Animal Hospital, and University of Firat. In the general examination, the vital parameters of the lamb were normal. The lamb could not hold the head in the normal position but there was no any standing problem in the lamb.



Figure 1. Front view of the case

When we examined the animal, there was a fluctuating mass about 15 cm diameter size in the occipital area and we decided to take the operation with the approval of the patient's owner. The lamb's physical examination was suitable for the operation. The general anesthesia of the lamb was given by injections of xylazine HCl (0.1 mg / kg, im) and ketamine HCl (4 mg / kg, im). After the shaving of the mass it was sterilized with 10% povidone iodine before the operation. The lamb was placed in lateral recumbency and the needle was inserted through the skin into the fluctuating mass. The fluid was drained slowly and intermittently for prevent to the sudden decline of the increased cerebrospinal fluid pressure.

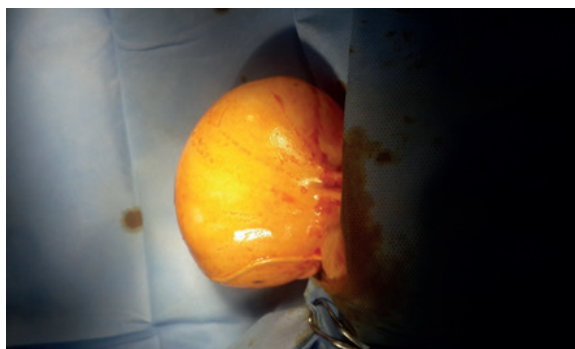


Figure 3. Pre-operative appearance of the mass

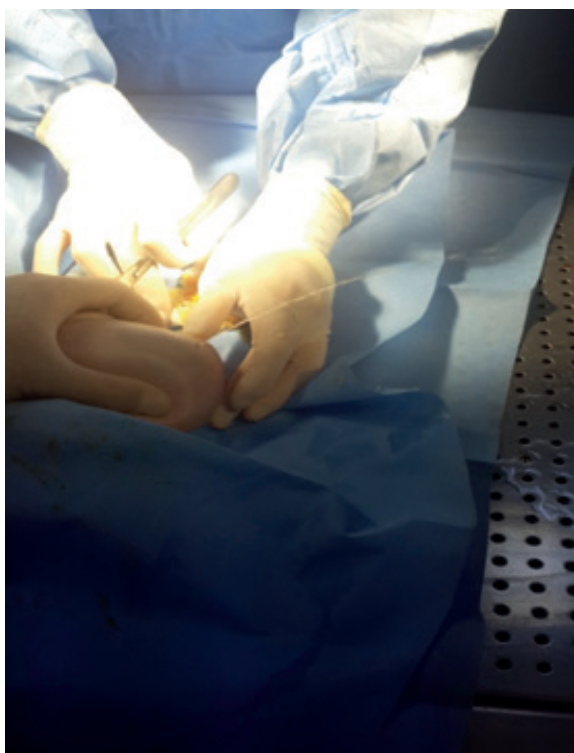


Figure 4. Drainage of the cerebrospinal fluid

After the draining of the fluid the sac was removed from the skull by using incision. And then there was an approximately 2 mm diameter hole was seen which is opened into the medullary canal. This hole was closed with sutures using polyglactin 2/0 suture material.

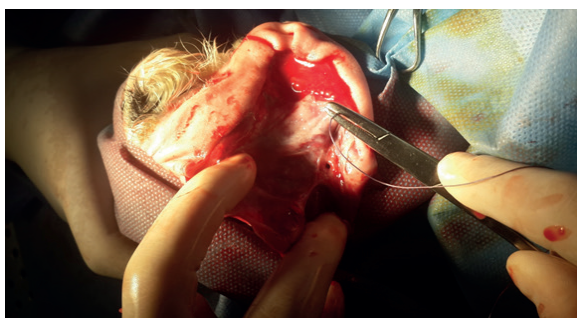


Figure 5. Closure of the hole which is opened into the medullary canal by using suture

At the same time, processus spinosus of first cervical vertebrae was seen that the 2 cm longer than normal. After cutting the excess bone part, the head skin was sutured with using 2-0 suture. The patient received parenteral antibiotics for 5 days. After 2 months the operation, it was observed that he continued his life in a very healthy. This case was report because it is a rarely seen type of anomaly in lamb and respond positive to the operation in this case.

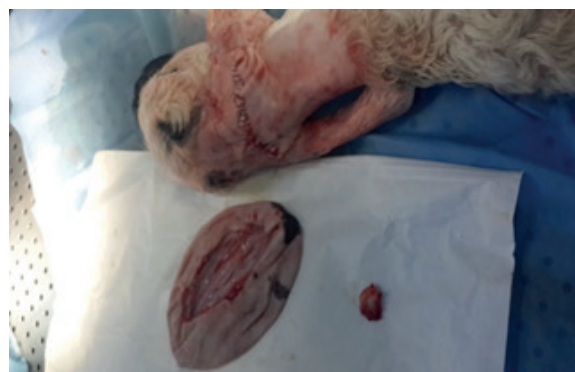

Figure 6. The excess skin and bone part

DISCUSSION

Yedegari and friends (7) reported that meningocele case a three days old male lamb was brought to their clinic with a large fluid-filled swelling at mid-parietal region having cyst-like consistency. And the size of the swelling was approximately 6cm×8cm and the overlying skin was normal. But they reported that they didn't treat this animal due to the lack of an expert surgeon, surgical treatment applied to the lamb failed.

Özaydın and friends (15) reported that meningocele case one day old male Morkaraman lamb brought to their clinic with 14 cm height sac that covered by hairs on the cranium. And they reported that they operated this case and lamb has no operative or postoperative complication. In our case we decided to surgical operating to this meningocele and the patient respond positive to the operation in this case.



Figure 7. Photo taken 1 month after surgery, sucking his mother



Figure 8. Two month after surgery from the back and front sides

RESULT AND CONCLUSION

There were no complications observed in both operative and postoperative periods, it was concluded that positive results could be obtained from operatively treated meningocele cases.

REFERENCES

1. Doğan H, Şındak N. 2013. Nizip ve köylerindeki buzağı, kuzu ve oğlaklarda anomalilerin insidansı ve bu olgularda bazı biyokimyasal değerlerin belirlenmesi. *Harran Üniv Vet Fak Derg*, 2: 61-66.
2. Noh DH, Jeong WI, Lee CS, et al. 2003. Multiple congenital malformations in a Holstein calf. *J Comp Path*, 129: 313-315.
3. Newman SJ, Bailey TL, Jones JC, Di Grassie WA, Whittier WD. 1999. Multiple congenital anomalies in a calf. *J Vet Diagn Invest*, 11: 368-371.
4. Dennis, S.M. and H.W. Leipold, 1986. Congenital and inherited defects in sheep. In: D.A. Morrow. Ed. *Current Therapy in Theriogenology* 2nd edn. W.B. Saunders Company, Philadelphia. pp: 864-867.
5. Belge A, Gönenci R, Biricik HS, Ormancı S. 2000. Buzağılarda doğumsal anomali olguları. *YYÜ Vet Fak Derg*, 11(2), 23-26.
6. Jubb, K.V.F. and Huxtable, C.R. 1993. *Crania Bifida and Related Defects*, In: *Pathology of Domestic Animals*, Jubb, K.V.F., Kennedy P.C. and Palmer N. (editors), Vol. 1, 4th ed., Academic Press, San Diego, pp: 273-274.
7. Yadegari M, Dehkordi SN, Dehkordi EV, Jafariyan M, Khamesipour F. 2013. Cranium bifidum with meningocele in a lamb: A case report. *Res. Opin. Anim. Vet. Sci.*, 3(11), 387-390.
8. Dennis, S.M. 1993. Congenital defects of sheep. *Vet. Clin. North Am. Food Anim. Pract*, 9, 203-217.
9. Urman, H.K. 1983. *Evcil Hayvanların Özel*

Patolojik Anatomisi. Ankara Üniversitesi Basımevi, Ankara.

10. Şen İA, İpek V, Demirel AA, Salcı H. 2016. Kıvrıkcık Irkı Bir Kuzuda Meningosel ve Unilateral Serebellar Hipoplazi. *Uludağ Univ. J. Fac. Vet. Med.* 35 (2): 61-64
11. Aslanbey D, Öcal MK, Kutsal O, Unsaldi E. 1989. İki kuzuda rastlanan meningocele ve menigoencephalocel olguları, A.Ü. Vet. Fak. Derg. 36 (2) 379-389.
12. Schunk KL. 1992. Disorders of the Spinal Cord. In Morgan RV (Ed): *Handbook of Small Animal Practice*, 2nd Ed. Churchill Livingstone Inc. 278.
13. Dennis SM. 1993. Congenital defect of Sheep. *Vet. Clin. North America* 9(1): 203-217.
14. Alkan İ, Bakır B, Dilek FH, Belge A. 1995. İki akkaraman kuzuda Meningoensefalosel Olgusu. *YYÜ Sağlık Bilimleri Derg.* 1(1): 71-75.
15. Özaydın İ, Okumuş Z, Baran V, Kılıç E. 1996. Meningoselli bir morkaraman kuzuda kranioplasti. *Kafkas Üniv. Veteriner Fak. Derg.* 2(1): 103-109.