

Nadir Bir Anüri Nedeni; Sağ Renal Arter Stenozu ile Eşzamanlı Sol Böbrek ve Üreter Taşı

A Rare Cause Of Anuria; Right Renal Artery Stenosis And Concurrent Left Kidney And Ureteral Stone

Şahin Kılıç¹, Aşkın Eroğlu¹

¹Muğla Fethiye Devlet Hastanesi, Üroloji Kliniği

Yazışma Adresi:

Uzm. Dr. Şahin KILIÇ

Muğla Fethiye Devlet Hastanesi, Üroloji Kliniği

Tel: 05072407186

E-mail:

sahinkilic84@hotmail.com

Özet

Üriner sistem obstrüksiyonlarına bağlı anüri gelişimi sıklıkla komplet infravezikal obstrüksiyonlarda görülmektedir. Bir taraf renal arter stenozu ile eş zamanlı diğer taraf komplet üreter obstrüksiyonuna bağlı anüri oldukça nadir karşılaşılabilecek bir durumdur. Sağ renal arter stenozu ile eşzamanlı sol böbrek ve sol üreter taşına bağlı gelişen anüri nedeniyle başvuran 78 yaşında kadın hasta ve tedavi yönetimi sunulmaya çalışıldı. Anüri ile başvuran özellikle yaşlı ve kalp damar hastalıkları açısından risk faktörleri taşıyan hastalarda, renal arter stenozu gibi prerenal anüri nedenlerinin de akılda tutulması gerekliliği sonucuna varıldı.

Anahtar Kelimeler: anüri, üreter taşı,renal arter stenozu

Abstract

Anuria due to urinary tract obstruction is often seen in complete infravesical obstruction. Anuria due to renal artery stenosis at one side and a concurrent complete ureteral obstruction on the other side is a very rare event. In this study we aim to present a seventy-eight year old female patient who applied with anuria due to right renal artery stenosis and concurrent left kidney and left ureteral stone and her treatment management. It was concluded that the prerenal causes of anuria, such as renal artery stenosis, should be kept in mind especially in elderly patients who applied with anuria and have risk factors for cardiovascular diseases.

Key words: anuria, ureteral stone, renal artery stenosis

Introduction

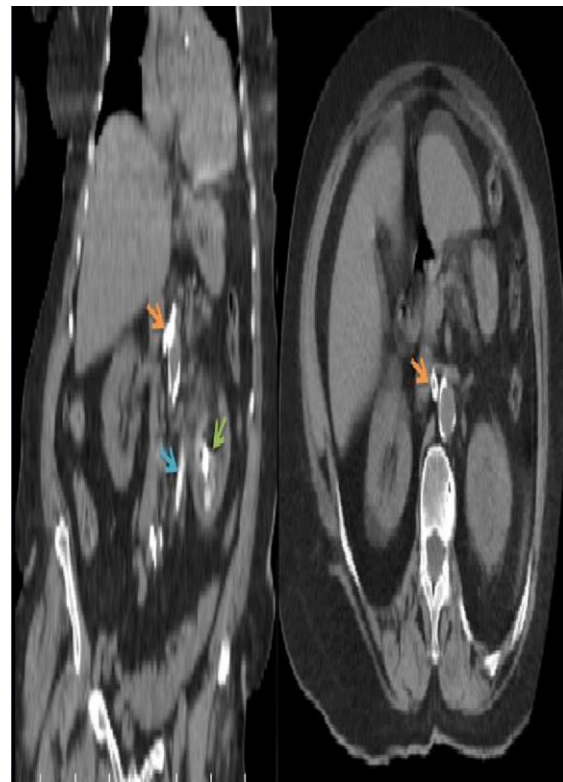
Anuria is defined as passage of less than 100 milliliters of urine in a day (1). Anuria can be a sign of acute renal failure however anuria associated with obstruction can also be the cause of acute renal failure. In practice of urology, anuria commonly develops due to urinary tract obstructions and urinary tract stone disease is a common cause of obstruction (2).

Renal artery stenosis (RAS) is a vascular pathology that may cause hypertension and renal dysfunction. There is only one case of anuria due to unilateral RAS in a patient with solitary kidney reported in the literature (3). Anuria due to bilateral RAS is very less likely possible (4). However, renal artery stenosis at one side and a concurrent anuria due to complete ureteral obstruction on the other side is a very rare condition to develop. A patient, who applied to the emergency service of our hospital with anuria due to right renal artery stenosis and a concurrent left kidney and left ureteral stone, is presented in this paper.

Case Report

A seventy-eight year old female patient applied with the complaint of severe left flank pain, absence of urine output and fatigue that persisted for one day. She had coronary artery disease, hyperlipidemia, hypertension and urinary tract stone disease in her history. She had left costovertebral angle tenderness, her arterial blood pressure measured as 180/120 mmHg, there was no additional condition observed in her physical examination and her creatinine was 3.2 mg/dl. As a result of the non-contrast abdominal CT scan, it was identified that

the patient had grade 2 hydronephrosis at her left kidney, a 31 mm stone extending from the left renal pelvis to the lower pole, a stone with a 19 mm long axis at the left proximal ureter and a calcified atheroma plaque measuring 22 mm extending to 1/3 proximal renal artery from the level of right renal artery ostium, which was suspected to obstruct the renal artery. No obstructive pathology was identified at the urinary tract of the right kidney (Figure 1).



Orange arrows: The atheroma plaque that obstructing the right renal artery
Blue arrow: The ureteric stone that obstructing the left ureter
Green arrow: The left kidney stone

A left double J ureteral stent was immediately inserted under local anesthesia and polyuria developed during the follow-up. Her creatinine level decreased down to 0.96 mg/dl. After the arterial blood pressure of the patient was stabilized within the normal limits with antihypertensive treatment, color Doppler ultrasound was taken to assess the renal

artery and right renal artery resistive index (RI) was found 0.86 and thus the value was considered as significant in terms of RAS. An intervention was not considered for the right renal artery of the patient given her age and clinical presentation, after assessing her present condition in consultation with the tertiary interventional radiology service. Left endoscopic ureteral stone treatment and left percutaneous nephrolithotomy (PNL) was applied to the patient under elective conditions. The patient is now at her postoperative month 10 and the glomerular filtration rate of the patient is 58 ml/min and her creatinine level is still under 1 mg/dl.

Discussion:

Anuria is a clinical condition that may develop due to prerenal, renal and postrenal causes. It can be a sign of acute renal failure (ARF) however anuria associated with obstruction can also be the cause of acute renal failure. ARF and anuria have high mortality rates and sepsis is known to be the most common etiologic factor (5). Whereas in practice of urology, most common cause of anuria is obstruction related factors. Postrenal anuria can be classified as supravescical and infravescical based on the level of urinary obstruction. Supravescical anuria develops as a result of the complete obstruction of both ureters or the obstruction of the ipsilateral ureter in patients with solitary kidney. Urinary tract stone disease is the most common cause of obstructive uropathy and a common cause of postrenal anuria (2).

While incidence rate of RAS in healthy elderly is 6.8%, this rate may increase up to 33% in those with diabetes mellitus and hypertension. Most common

cause of RAS in the elderly population is atherosclerotic plaques (6,7). Development of acute anuria only due to RAS is not very likely. A case of anuria, which developed due to acute arterial obstruction of the left renal artery atheroma plaque following extracorporeal shock wave lithotripsy applied for the pancreatic stone treatment of a patient with left solitary kidney (3) and a case of RAS associated anuria, which developed after initiation of angiotensin converting enzyme (ACE) inhibitor treatment in a patient ended up in solitary kidney following nephrectomy and later diagnosed during the follow-up (4) were reported in the literature. A case of anuria due to renal artery stenosis at one side and a concurrent complete ureteral obstruction on the other side has not yet been reported. Although it is possible in terms of physiopathology, this is a very rare condition to develop given the difference in the age groups where urinary tract stone disease and atherosclerotic RAS are most commonly observed. On the other hand, it is challenging to diagnose RAS in clinical practice. It may lead to a suspicion only when the patient is old and hypertensive and has the risk factors for cardiovascular diseases. Our patient had these mentioned findings. Whereas, the most important finding was that the calcified atheroma plaque was clearly observed at the right renal artery of the patient during the non-contrast abdominal CT scan. In case no stenosis was identified at the right renal artery of the patient, we could have waited for the improvement of ARF through intravenous fluid therapy and caused worsening of ARF due to delaying left ureteral stenting procedure and thus resulted in development of additional complications.

In conclusion; although causes of postrenal anuria are most commonly observed in practice of urology, besides the postrenal causes, other potential causes of prerenal anuria such as renal artery stenosis should also be considered in particular in the elderly and anuric patients having risk factors for cardiovascular diseases.

References

1. Yeniçerioglu Y. Oligüri-Anüri: Temel Yaklaşım ve Tedavi Türkiye Klinikleri J Surg Med Sci. 2007;3(20):9-15.
2. Halle MP, Toukep LN, Nzuobontane SE, Ebana HF, Ekane GH, Priso EB. The profile of patients with obstructive uropathy in Cameroon: case of the Douala General Hospital. Pan Afr Med J. 2016;23:67.
3. Cecere N, Goffette P, Deprez P, Jadoul M, Morelle J. Renovascular acute renal failure precipitated by extracorporeal shock wave lithotripsy for pancreatic stones. Clin Kidney J. 2015;8:426-9.
4. Woittiez KJ, Van Buren M, Kesecioglu J. Renal artery stenosis: a classic presentation, a rare cause. BMJ Case Rep. 2012;13;2012.
5. Choi HM, Kim SC, Kim MG, Jo SK, Cho WY, Kim HK. Etiology and outcomes of anuria in acute kidney injury: a single center study. Kidney Res Clin Pract. 2015;34:13-9.
6. Hansen K, Edwards M, Craven T. Prevalence of renovascular disease in the elderly: a population-based study. J Vasc Surg. 2002;36:443-51.
7. Postma CT, Klappe EM, Dekker HM, Thien T. The prevalence of renal artery stenosis among patients with diabetes mellitus. Eur J Intern Med. 2012;23:639-42.

