

Serous Cystadenoma in 12 Years Old Girl Presenting with Severe Anemia

Şiddetli Anemi ile Başvuran 12 Yaş Kız Olguda Seröz Kistadenom

Mustafa Tekin¹, Adem Küçük², Şule Yıldırım¹, Naci Topaloğlu¹, Muhammed Kasım Arık³, Betül Kızıldağ⁴

¹ Çanakkale Onsekiz Mart Üniversitesi Çocuk Sağlığı ve Hastalıkları ABD

² Çanakkale Onsekiz Mart Üniversitesi Çocuk Cerrahisi ABD

³ Çanakkale Onsekiz Mart Üniversitesi Genel Cerrahi ABD

⁴ Çanakkale Onsekiz Mart Üniversitesi Radyoloji ABD

Yazışma adresi: Şule Yıldırım, Çanakkale Onsekiz Mart Üniversitesi Çocuk Sağlığı ve Hastalıkları ABD, Çanakkale Onsekiz Mart Üniversitesi Tıp Fakültesi Hastanesi, Cumhuriyet Mahallesi Sahil Yolu No 5 Kepez / Çanakkale/Türkiye Tel: +90 505 828 07 07. Fax: +90 286 263 59 56. E-mail: sulesln@yahoo.com

Geliş tarihi / Received: 04.02.2014

Kabul tarihi / Accepted: 04.06.2014

Abstract

A 12-year-old girl presented with anemia for eight months and abdominal pain for three months. She was prescribed iron supplements for eight months. She was admitted to our hospital with treatment-resistant anemia and abdominal pain. In physical examination she was found to have a mass in right lumbar area. An ultrasound and magnetic resonance imaging scans suggested a large cystic mass that fulfill the almost all of midline of the abdomen, pushing intra-abdominal organs laterally and superiorly. She had a successful excision of the tumor and the final pathology was serous cystadenoma. It is important to investigate the etiology of anemia in adolescent girls although the most common etiology is iron deficiency anemia.

Keywords: abdominal mass, cystadenoma, iron deficiency anemia, ovary

Özet

12 yaşında kız hasta 8 aydır demir tedavisine rağmen devam eden anemi ve son 3 aydır karın ağrısı yakınması ile başvurdu. Hastanın fizik muayenesinde sağ lomber bölgede kitle palpe edildi. Ultrasonografi ve manyetik rezonans görüntüleme hemen hemen tüm orta hattı dolduran ve intraabdominal organları lateral eve yukarı iten büyük kistik bir kitle varlığı rapor edildi. Kitle başarılı bir şekilde çıkarıldı ve patolojik olarak seröz kistadenomla uyumlu idi. Adölesan kızlarda en sık anemi etyolojisi demir eksikliği olsa da bu yaş grubunda da tedavi öncesi etyolojik araştırma yapmak önemlidir.

Anahtar kelimeler: Abdominal kitle, kistadenom, demir eksikliği anemisi, over

Introduction

Anemia is the most common considered cause in patients presenting with paleness and weakness. Most common cause of anemia in childhood is iron deficiency anemia. Iron deficiency can be due to

inadequate intake, inadequate absorption or blood loss due to various causes (1). The most common cause of iron deficiency anemia especially in early childhood is nutritional. Though, in adolescent girls the most common cause is menstrual irregularity and

menorrhagia (1).

In girls, physiological menstrual irregularity can be seen in early menarche period (2). In fact, most parents can concern about this situation and refer to a physician. Generally no more investigation is necessary in these patients but if this situation causes anemia, the treatment should not be arranged before the exact cause is enlightened.

Case Report

A 12 year-old girl referred to our clinic with severe anemia (hemoglobin of 5,4 g/dl), paleness and weakness. She was followed up and had medications for anemia at primary care. Her menstruation began approximately 1 year ago and she had also complaint of menstrual irregularity and long duration of menstrual cycles. On physical examination she had 116 bpm, cardiovascular 2/6 systolic murmur, respiratory, head and neck and extremity examinations were normal. On abdominal examination abdomen was distended, there was an image of pregnancy (figure 1). When the abdominal distension was questioned, it was thought due to weight gain by the family and the patient. Her complete blood count showed severe microcytic hypochromic anemia with hemoglobin of 4,7 g/dl, hematocrit %16,4, MCV 60,9 fL; MCH 17,5 pg; MCHC 28,7 g/dl; thrombocytosis and normal leukocyte count. Kidney function tests, liver enzymes, ALP, uric acid, glucose, electrolytes, and thyroid function tests were normal. C reactive protein (CRP) was 0,14 mg/dl and erythrocyte sedimentation rate (ESR) was 43 mm/h. In hormonal examination; FSH 0,12 mIU/ml, LH 0,58 mIU/ml, cortisol 19,14 µg/dl, prolactin 11,62 ng/ml and estradiol 73 pg/ml. Urine microscopy showed 18 leukocyte and a lot of erythrocytes, she had menstrual cyclus at the time of examination. Abdominal X-ray was non-

specific.

Blood samples for alfa-fetoprotein, CA15.3, CA125, CA 19.9 were taken. The results were in normal limits.

Abdominal ultrasound could not clearly distinguish but suggested a possible right adnexial or mesenchymal cystic mass that fulfill almost all of midline of the abdomen, pushing intra-abdominal organs laterally and superiorly. The mass was cystic and thick septated. In the Doppler examination minimal vascularization of septa was shown.

Magnetic resonance imaging (MRI) with contrast was similar with the ultrasonographic findings; there was a lesion with thin septa interior and approximately 22x10x23 cm in size, T1 hypointense, T2 hyperintense, and after contrast wall and septa were enhancing. There was perihepatic, perisplenic and intestinal free fluid. However, it could not be clearly distinguished if it originates from ovary or mesenchyme.

In the light of current clinical and radiological findings it was decided to intervene cystic mass surgically in an emergent manner. Due to the fact that it was a very huge cystic mass and the origin could not be detected exactly it was decided to intervene with open surgery.

In the course of operation it was detected that the cystic mass was originating from right ovary. Firstly, ovary-sparing surgery was planned but the ovarian tissue and the cyst could not be differentiated exactly. Therefore, surgical resection of the mass and the right ovary was performed. The left ovary was normal. She recovered uneventfully. A cystic mass measuring 24 cm in diameter was found to arise from the right ovary (figure 2). Histology revealed a serous cystadenoma.

In the sixth month of postoperative period her anemia improved (hemoglobin 12,8 g/dl, hematocrit %37,4,

MCV 87,9 fL; MCH 28,9 pg; MCHC 32,7 g/dl), menstrual cycles became regular and general appearance improved. In pelvic ultrasonography left ovary was well.

Discussion

Once the irregularities of menstrual cycles are common in adolescent girls as an etiologic factor of iron deficiency anemia, there is a tendency to begin treatment directly without identification of the exact cause in this age group. In our case there was the same situation and she had treatment but the treatment was not effective.

In such cases careful history should be taken and a complete physical examination should be done to exclude a number of possible pathological causes. Especially menstrual problems causing iron deficiency anemia should be more carefully examined not to miss more serious causes.

Sometimes abdominal masses that grow progressively can be falsely perceived as weight gain by parents or patients as in our case. Therefore

in routine examinations abdominal distensions should be carefully evaluated. These masses can be benign pathologies such as organomegalies as well as malignant pathologies that can be life-threatening.

Fortunately, our patient with anemia and abdominal mass resulted as serous cystadenoma that is a benign cystic mass. The serous cystadenoma is a benign ovarian tumor that can grow up rapidly and cause clinical signs. Estrogen that is released from this tumor is not under the control of hypothalamo-pituitary axis so its levels can be continuously high in blood. As a result this can cause endometrial hypertrophy, abnormal uterine bleedings and prominent secondary sex characteristics. Also, rapidly growing tumor can give rise to ovarian torsion (3, 4)

Consequently in adolescent girls to investigate the etiology of anemia is important. We wish to emphasize that the ovarian tumors can be remembered as an etiologic factor of anemia in adolescents.

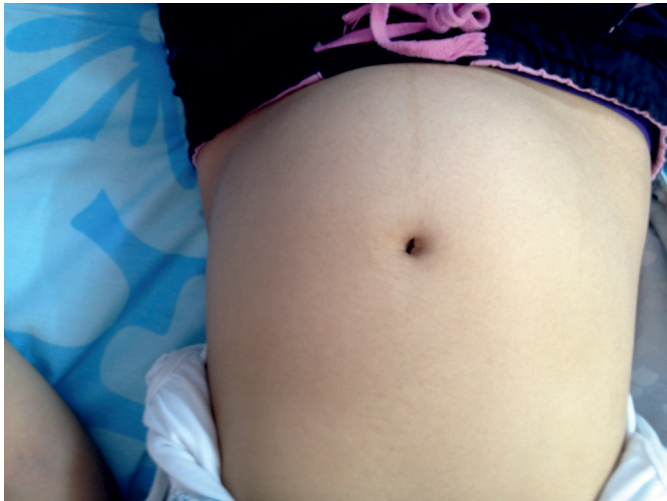

Figure 1. Appearance of abdomen of the patient.

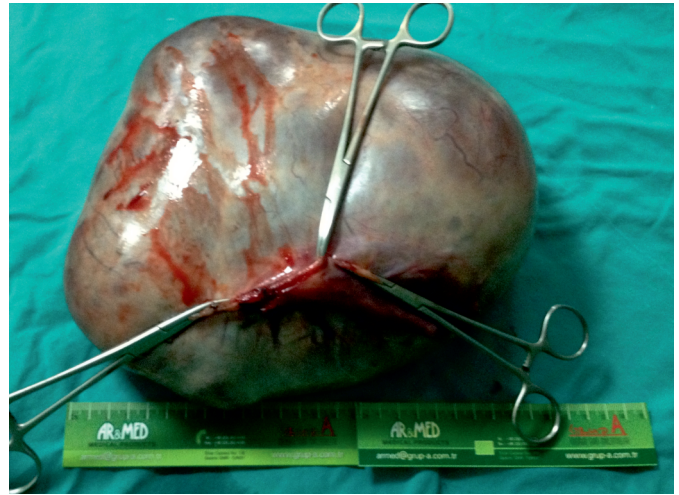


Figure 2. Macroscopy of the mass.

Yazarlarla ilgili bildirilmesi gereken konular (Conflict of interest statement) : Yok (None)

References

- 1) Lerner NB, Sills R. Iron-deficiency anemia. In: Kliegman RM, Stanton BF, St Geme JW, Schor NF, Behrman RE, eds. Nelson Textbook of Pediatrics. 19th ed. Philadelphia, Pa: Saunders Elsevier, 2011: 1655-8.
- 2) Browner-Elhanan KJ, Epstein J, Alderman EM. Evaluation of irregular menses in perimenarcheal girls: a pilot study. J Pediatr Adolesc Gynecol. 2003 Dec; 16(6):365-8.
- 3) Simsik S, Özokutan BH, Ceylan H, Aydın A, Güler E. Çocuklarda Over Patolojileri. Gaziantep Tıp Dergisi. 2010; 16(2): 1-4.
- 4) De Backer A, Mader GC, Oosterhuis JW, Hakvoort-Cammel FG, Hazebroek FW. Ovarian germ cell tumors in children: a clinical study 66 patients. Pediatr Blood Cancer. 2006; 46(4): 459-464.