

Treatment of Mallory-Weiss syndrome using argon plasma coagulation

Mallory-Weiss sendromunun argon plazma koagülasyonu ile tedavisi

Mehmet BEKTAŞ¹, Esin KORKUT¹, Ramazan IDILMAN¹, Onur KESKİN¹, Yusuf ÜSTÜN¹, Vikas GUPTA², Kadir BAHAR¹

Department of ¹Gastroenterology, Ankara University, School of Medicine, Ankara

²The University of Texas, School of Public Health, Houston, Texas, USA 77030

The endoscopic hemostatic method has been introduced as a safe and effective mechanical approach to hemostasis for upper gastrointestinal bleeding related to Mallory-Weiss syndrome. A 62-year-old male patient with chronic cough and a 27-year-old 10-week pregnant female were admitted to our clinic with gross hematemesis. Upper gastrointestinal endoscopy was performed and Mallory-Weiss syndrome was diagnosed. Coagulum and visible vessels were observed during the procedure. Argon plasma coagulation was applied. After argon plasma coagulation, complete hemostasis was achieved and rebleeding did not occur. In conclusion, argon plasma coagulation can be performed easily and with minimum risk of complications such as perforation or delayed hemorrhage in patients with actively bleeding non-fibrotic Mallory-Weiss syndrome.

Key words: Argon plasma coagulation, Mallory-Weiss syndrome

INTRODUCTION

Mallory-Weiss syndrome (MWS) is characterized by linear, nonperforating mucosal lacerations in the cardia, cardioesophageal junction or distal esophagus, or a combination of these sites. These lacerations are oriented along the longitudinal axis of the esophagus causing repeated vomiting. Many conditions have been noted to have an association with MWS, including chronic and/or binge alcohol use (1,2). Other associations described previously include the presence of a hiatus hernia, non-steroidal anti-inflammatory agent use, portal hypertension, other mucosal pathologies, upper endoscopy, and prolonged coughing or paroxysms of coughing (3,4).

MWS is a common cause of upper gastrointestinal (GI) hemorrhage, accounting for between 5% and 15% of cases (6). In approximately 90% of patients, non endoscopic management controls the bleeding. The clinical course is usually benign. For the remaining patients, in whom bleeding does not cease spontaneously, intervention is required (1). With the development of endoscopic techniques, endoscopic therapy has become the first-line treatment for actively bleeding lacerations. Various endoscopic methods of hemostasis, such as injection of sclerosing agents, electrocoagulation, hemoclip placement, and endoscopic band ligation, have been used and evaluated for MWS (1,3,7).

Endoskopik hemostaz metotları Mallory-Weiss Sendromuna bağlı üst gastrointestinal kanamalarda güvenli ve etkin bir yaklaşım olarak kabul edilmektedir. Kronik öksürüğü olan 62 yaşındaki bir erkek hasta ve 27 yaşında 10 haftalık gebe hasta kliniğimize ciddi hematemez bulgularıyla başvurdu. Bu hastalara üst gastrointestinal endoskopi uygulandı ve Mallory Weiss sendromu tanısı kondu. İşlem sırasında koagulum ve visible vessel görüldü ve bu lezyonlara argon plazma koagülasyonu uygulandı. Argon plazma koagülasyonu sonrasında tam bir kanama kontrolü sağlandı ve takipte kanama tekrarlamadı. Sonuç olarak argon plazma koagülasyonu aktif kanayan non fibrotik Mallory-Weiss sendromu olan hastalarda gecikmiş hemoraji ve perforasyon gibi minimal komplikasyon riskiyle kolaylıkla uygulanabilir.

Anahtar kelimeler: Argon plazma koagülasyon, Mallory-Weiss sendromu

Argon plasma coagulation (APC) is a special electrosurgical modality in which a high-frequency electric current is conducted 'contact-free' through ionized and thus electrically conductive argon (argon plasma) into the tissue to be treated. The aim of this technique is to create therapeutically effective temperatures for thermal hemostasis and/or the ablation of pathologic tissue (12). Our search of the PubMed database revealed no literature on the use of endoscopic therapy in MWS. In this study, we describe the use of APC in two cases with massive hematemesis caused by MWS.

CASE REPORTS

Case 1

A 62-year-old male patient admitted to our hospital complaining of massive hematemesis and melena. In his medical history, chronic cough for three months was remarkable. In his physical examination, his vital signs were stable with blood pressure (BP) of 125/85 mmHg and pulse of 92/min. His laboratory study values were: hemoglobin (Hb): 10.2 g/dl, hematocrit (Htc): 30.3%, platelets (Plt): 250,000 mm³, and prothrombin time: 13.2/s. During the upper endoscopic procedure, a 2.5 cm tear from 1 cm above the esophagogastric

Correspondence: Mehmet BEKTAŞ

Ankara University, School of Medicine Department of Gastroenterology,

Tıp Fakültesi Hastanesi 06100 Dikimevi, Ankara, Turkey

Phone: + 90 312 508 21 50 • Faks: + 90 312 363 62 13 • E-mail: mbektas70@hotmail.com

Manuscript received: 18.05.2011 **Accepted:** 15.06.2011

junction through the cardia was observed. Coagulum and visible vessels proximal to the cardia were detected (Figure 1). The stomach and duodenum were filled with blood. No other bleeding spots were detected in the stomach or duodenum. A 40-watt, 2-flow APC was performed to the MWS site (Figure 2). After the procedure, no complication was observed (Figure 3). The patient had bleeding and did not require transfusion. In his follow-up endoscopy, no bleeding spots were found.

Case 2

A 27-year-old female patient at 10 weeks of pregnancy was admitted to the hospital with the diagnosis of hyperemesis gravidarum. In her follow-up, her Hb dropped from 12 g/dl to 9.5 g/dl. Diagnostic endoscopy was performed, which revealed a 1 cm tear covered with coagulum in the esophago-gastric junction. A 40-watt, 2-flow APC was performed. After the procedure, no complication was observed. In these two cases, sucralfate and acid suppressive treatment were given after the APC procedure.

DISCUSSION

Mallory-Weiss syndrome (MWS) generally has a benign course, in more than 90% of cases. Therapeutic endoscopy was not necessary in patients with protruding visible vessels and/or adherent clots. However, a variety of hemostatic procedures were required in 87.5% of control patients who had active bleeding and in whom endoscopic hemostasis was not achieved. A variety of endoscopic treatment methods for MWS bleeding have been tested in transient or permanent hemostatic trials in many studies. Recently, some investigators

have suggested the use of the metallic hemoclip method or band ligation method in a mechanical hemostatic approach (1).

Mechanical hemostasis by hemoclip placement or band ligation is associated with less damage to the surrounding tissues than that caused by sclerosant injection or thermal coagulation. Thus, these procedures may be less likely to cause some of the complications that have occurred with other treatment methods. Huang et al. (3) reported that hemoclip placement currently has an initial success rate of 94%. Hemoclip application is difficult because of a tangential approach in MWS. The assistants and endoscopists must be trained in the use of the hemoclip system (8). Endoscopic band ligation can be used effectively for bleeding lesions in non-fibrotic tissue. Because MWS is actually a mucosal tear without fibrotic tissue, it is possible to achieve hemostasis in a single session if the lesion is placed within the endoscopic band ligation cap. Endoscopic band ligation has an initial success rate of 100%, with permanent hemostasis achieved in 97.3% of cases (9).

The MWS tear usually extends into the submucosa, and bleeding occurs from the rich plexus of arteries and veins. Although most patients with MWS stop bleeding spontaneously, injection hemostasis may be incomplete for patients with a large and/or long plexus of vessels. Injection therapy involving various agents such as epinephrine, absolute alcohol and 1% polidocanol has been reported. For patients with MWS, the reported rates of primary hemostasis obtained with epinephrine injection range from 93% to 100%. However, bleeding recurs in 5.8% to 44% of patients with actively bleeding

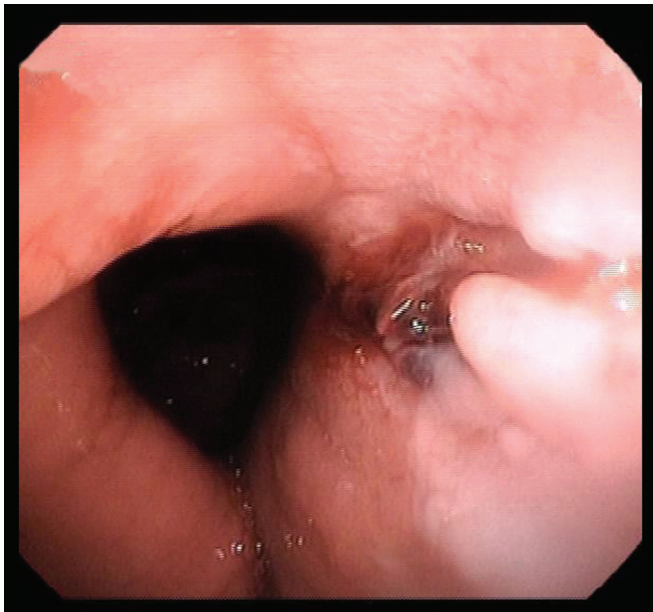


Figure 1. Coagulum and visible vessel at the base of the lesion.

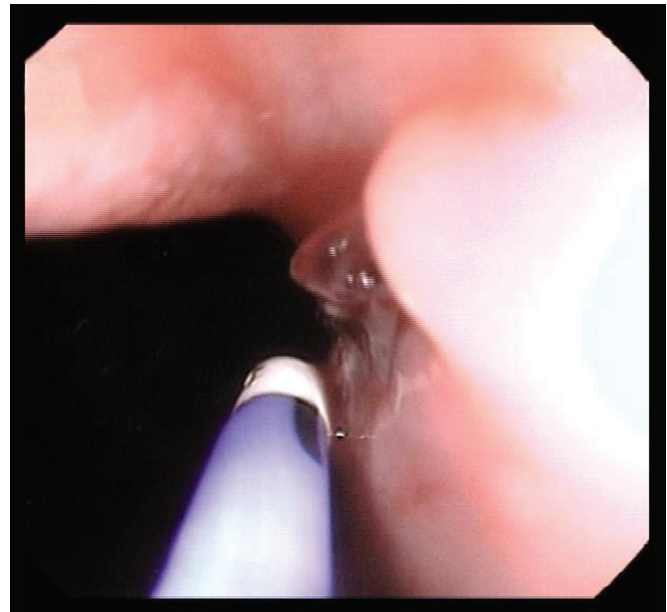


Figure 2. Argon plasma coagulation application to the visible vessel.

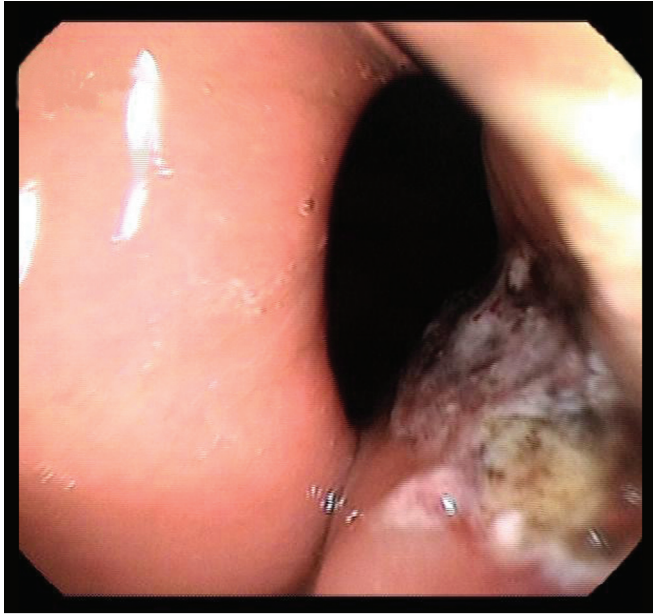

Figure 3. Scene of the tear after argon plasma coagulation.

MWS (10,11). Furthermore, in thermal endoscopic therapy, endoscopists have to be careful to manage the relatively thin esophageal wall and few fibrotic bases in patients with MWS. Electrocoagulation allows the simultaneous application of heat and pressure to the bleeding lesion. The application of the electrocoagulation in a wet field, as occurs when there is sig-

nificant bleeding, also decreases the effectiveness of coagulation because the liquid dissipates the heat quickly, thereby reducing the effect on the tissue. The reported rate of initial hemostasis was 83.3% for patients with actively bleeding MWS (12).

Argon plasma coagulation (APC) is a non-contact method of delivering high-frequency monopolar current through ionized and electrically conductive argon gas, which is called argon plasma. Initially developed for the surgical arena, this device has seen an ever-expanding role in therapeutic endoscopy. APC is used for various clinical indications: adjunctive therapy (after piecemeal resection of large colonic polyps), radiation proctopathy, gastric antral vascular ectasia, angiectasia, ablation of Barrett's epithelium, bleeding peptic ulcers, prevention of recurrent esophageal varices, palliation of GI malignancy, and refractory ulcerative colitis (13). However, there are no data about the use of APC in the treatment of bleeding MWS. In our cases, 40-watt, 2 L/min flow was used for the procedure. No complication was observed during the follow-up. No more bleeding was documented during the follow-up endoscopy 24 hours after the procedure.

In conclusion, APC is an effective and safe alternative for the management of upper gastrointestinal bleeding related to MWS. Greater experience in prospective trials is required to evaluate the suitability of APC for wide clinical use.

REFERENCES

- Morales P, Baum AE. Therapeutic alternatives for the Mallory-Weiss tear. *Curr Treat Options Gastroenterol* 2003; 6: 75-83.
- Sugawa C, Benishek D, Walt AJ. Mallory-Weiss syndrome. A study of 224 patients. *Am J Surg* 1983; 145: 30-3.
- Huang SP, Wang HP, Lee YC, et al. Endoscopic hemoclip placement and epinephrine injection for Mallory-Weiss syndrome with active bleeding. *Gastrointest Endosc* 2002; 55: 842-6.
- Paquet KJ, Mercado-Diaz M, Kalk JF. Frequency, significance and therapy of the Mallory-Weiss syndrome in patients with portal hypertension. *Hepatology* 1990; 11: 879-83.
- Penston JG, Boyd EJ, Wormsley KG. Mallory-Weiss tears occurring during endoscopy: a report of seven cases. *Endoscopy* 1992; 24: 262-5.
- Knauer CM. Mallory-Weiss syndrome, characterization of 75 Mallory-Weiss lacerations in 528 patients with upper gastrointestinal hemorrhage. *Gastroenterology* 1976; 71: 5-8.
- Higuchi N, Akahoshi K, Sumida Y, et al. Endoscopic band ligation therapy for upper gastrointestinal bleeding related to Mallory-Weiss syndrome. *Surg Endosc* 2006; 20: 1431-4.
- Gevers AM, De Goede E, Simoens M, Hiele M, Rutgeerts P. A randomized trial comparing injection therapy with hemoclip and with injection combined with hemoclip for bleeding ulcers. *Gastrointest Endosc* 2002; 55: 466-9.
- Farin G, Grund KE. Technology of argon plasma coagulation with particular regard to endoscopic applications. *Endosc Surg Allied Technol* 1994; 2: 71-7.
- Chung IK, Kim EJ, Hwang KY, et al. Evaluation of endoscopic hemostasis in upper gastrointestinal bleeding related to Mallory-Weiss syndrome. *Endoscopy* 2002; 34: 474-9.
- Park CH, Min SW, Sohn YH, et al. A prospective, randomized trial of endoscopic band ligation vs epinephrine injection for actively bleeding Mallory-Weiss syndrome. *Gastrointest Endosc* 2004; 60: 22-7.
- Matsui S, Kamisako T, Kudo M, Inoue R. Endoscopic band ligation for control of nonvariceal upper GI hemorrhage: comparison with bipolar electrocoagulation. *Gastrointest Endosc* 2002; 55: 214-8.
- Vargo JJ. Clinical applications of the argon plasma coagulator. *Gastrointest Endosc* 2004; 59: 81-8.