

Tubulointerstitial Nephritis and Uveitis (TINU) Syndrome: A Case Report and Review of Literatüre

Tübülointerstisyel Nefrit ve Üveit (TINU) Sendromu: Literatür Eşliğinde Bir Olgu

Erdal Bodakci, Dondu Uskudar Cansu, Cengiz Korkmaz

Eskişehir Osmangazi University Medical School, Rheumatology Division, Eskişehir, Turkey

Abstract: Tubulointerstitial nephritis and uveitis (TINU) syndrome is characterized by the association of acute tubulointerstitial nephritis and uveitis. This syndrome is a rare cause of acute tubulointerstitial nephritis and is a diagnosis of exclusion. In this case report, we presented a 56-year-old female patient, who developed uveitis before kidney involvement and was diagnosed with TINU syndrome due to recurrences. We also briefly reviewed the type of ocular involvement in light of literature.

Keywords: Acute tubulointerstitial nephritis, tubulointerstitial nephritis and uveitis (TINU) syndrome, uveitis

Bodakci E, Cansu Uskudar D, Korkmaz C. 2019. Tubulointerstitial Nephritis and Uveitis (TINU) Syndrome: A Case Report and Review of Literatüre, *Osmangazi Journal of Medicine*, 41(2): 187-191, **Doi:** 10.20515/otd.515086

Özet: Tübülointerstisyel nefrit ve üveit (TINU) sendromu, akut tübülointerstisyel nefrit ve üveit birlikteliği ile karakterizedir. Bu sendrom akut tübülointerstisyel nefritin nadir bir nedeni olup diğer sebeplerin dışlanmasıyla tanı alır. Bu olgu sunumunda böbrek tutulumundan önce üveit gelişen ve nüks nedeniyle TINU sendromu tanısı konan 56 yaşında bir kadın hasta sunuldu. Ayrıca literatür ışığında oküler tutulum tipini kısaca gözden geçirdik.

Anahtar kelimeler: Akut tübülointerstisyel nefrit, tübülointerstisyel nefrit ve üveit (TINU) sendromu, üveit

Bodakçi E, Cansu Üsküdar D, Korkmaz C. 2019. Tübülointerstisyel Nefrit ve Üveit (TINU) Sendromu: Literatür Eşliğinde Bir Olgu, *Osmangazi Tıp Dergisi*, 41(2): 187-191, **Doi:** 10.20515/otd.515086

ORCID ID of the authors: E.B. 0000-0002-0402-1525; D.Ü.C. 0000-0001-6543-3905; C.K 0000-0003-2679-0699

1. Introduction

The association of uveitis and tubulointerstitial nephritis is called TINU syndrome. It can be also called as the oculo-renal syndrome. The association of uveitis and acute tubulointerstitial nephritis was first described by Dobrin et al. in 1975 (1). After the disease has been defined as TINU syndrome by Vanhaesebrouck (2), approximately 425 cases have been reported until today. Although its pathogenesis is not completely known, it is an autoimmune disease in which humoral and cellular immunity play a role (3,4), and drugs, infections, and toxic agents are considered to trigger the disease in patients with this genetic background (5). Uveitis is typically anterior and bilateral, but many atypical forms of panuveitis and posterior uveitis have been described. Ocular signs may occur before, simultaneously or after the onset of renal

failure (6). Topical and systemic corticosteroids are recommended for the treatment of uveitis. We detected 425 cases in the scanning in PUBMED database for the date between 1975 and December 2017. All of these cases had tubulointerstitial nephritis and accompanying uveitis. However, since the data of the uveitis (simultaneous and after the uveitis) before the nephritis were inadequate, we did not group the patients in terms of this respect. The uveitis types and the rates of the 425 cases were determined according to gender. In this case report, we aimed to present a case of TINU syndrome, who had a history of acute tubulointerstitial nephritis and had three episodes of bilateral panuveitis, in the light of literature because it is rare and can be missed if not thought. We also briefly reviewed the type of ocular involvement in light of literature.

2. Case Presentation

A 56-year-old woman had no any known disease other than hypertension and was diagnosed with bilateral panuveitis 3 years ago due to complaints of excessive tearing, photophobia, and pain. She improved considerably on corticosteroid therapy. When she complained of loss of appetite, fatigue, and nausea 2 years ago, creatinine level was found to be 4.1 mg/dl. The patient's previous creatinine values were normal. Proteinuria was detected as 3800 mg/day in a 24 hour urine sample. Complete urine analysis showed no hematuria and eosinophilia. On renal ultrasound, renal dimensions were normal, and there were grade 1 renal parenchymal changes. In the patient who had no any infection in recent times, ANA, anti-dsDNA, anti-neutrophil cytoplasmic antibody (c-ANCA), and perinuclear anti-neutrophil cytoplasmic antibody (p-ANCA) were negative. Complement levels were normal. Serum thyroid stimulating hormone (TSH) was normal. Percutaneous renal biopsy showed interstitial lymphoplasmacytic infiltration, minimal focal fibrosis, and focal tubular atrophy. Glomerular and vascular changes were not observed in immunofluorescent staining. Fibrinogen, immunoglobulins, and complement components were negative. After creatinine level and proteinuria were improved on corticosteroid and fluid therapy, the patient was followed up clinically. She had pain, redness and photophobia in both eyes three months after corticosteroid therapy was discontinued, and ophthalmologic examination revealed bilateral panuveitis. Uveitis improved with corticosteroid therapy. Because the patient had bilateral panuveitis six months after the second attack of uveitis, she was referred to us for the investigation of rheumatic diseases. No significant pathology was found in the examination and laboratory tests performed for Behcet's disease, sarcoidosis, Sjögren's syndrome, tuberculosis, toxoplasmosis, spondyloarthritis, and granulomatous polyangiitis. None had a history of pancreatitis, sialadenitis, or other inflammatory disorders potentially referable to IgG4 related disease. The patient was diagnosed with TINU syndrome because she

had an idiopathic recurrent bilateral panuveitis and an idiopathic acute tubulointerstitial nephritis. Uveitis improved with combined therapy of corticosteroid and azathioprine. The patient was followed up on only azathioprine treatment.

3. Discussion

Our patient developed bilateral panuveitis which occurred twice with an interval of 6 months after nephritis. We aimed to present this case because it was bilateral, panuveitis (a rare form) and recurrent and occurred before and after nephritis. In most cases (65%), nephritis precedes uveitis; however, in 21% of cases, uveitis is present before nephritis, and in 15%, the two conditions occur simultaneously (7). Ariba et al series, in 75% of cases, uveitis preceded the nephritis (8).

TINU syndrome should be brought to mind in every person who has evidence of eye and kidney disease, but the differential diagnosis should be made. Although the etiology of TINU syndrome remains uncertain, it has been associated with multiple immunologic conditions and HLA proteins, suggesting an immunologic abnormality (9). This syndrome is associated with many autoimmune diseases. Sjögren's syndrome, sarcoidosis, Behcet's disease, tuberculosis, toxoplasmosis and Wegener's granulomatosis are the main ones. Therefore, while the differential diagnosis was made in these patients, the laboratory tests such as chest x-ray, serum ACE level, pulmonary function tests, p-ANCA and c-ANCA levels should be used. In our patient, other diseases were excluded with the laboratory and radiological evaluations performed for the differential diagnosis of other systemic diseases.

In the PUBMED Database dated December 2017, we performed a scan under the title of "TINU syndrome" and "Tubulointerstitial Nephritis and Uveitis Syndrome"; and evaluated the patients that had definite TINU Syndrome diagnosis and the ones whose uveitis localizations were defined according to age, gender, uveitis localization and unilateral, bilateral findings (Table 1). In this scan, we

determined 425 cases published so far between the dates 1975 and December 2017 (figure 1). Of these cases, 281 (66%) were female, and 144 (34%) were male; and the rate of the females males was determined as 1.9. The mean age was 26.3 years, and the age range was between 6 and 74. While Mandeville et al. (7) reported in their analysis in 2001 that the Female:Male rate was 3:1, and the mean age was 15, anterior uveitis was 80%, bilateral uveitis 84%; we found in our analysis that the average age had increased; the female:male rate was decreased; bilateral uveitis 95.5% and anterior uveitis was seen in 88% of the cases. We consider that these differences are due to the increase in the cases causing increased awareness and knowledge on the syndrome. Based on this analysis, we may claim that since the anterior and bilaterality rate of the uveitis, it is the most important parameters among the diagnosis criteria; however, unlike the opinion in the

previous literature claiming that it was generally diagnosed in children, it may be observed in any age groups, and it must be kept in mind that this syndrome may occur in patients who have nephritis and ocular symptoms independent from age factor. Patients with TINU syndrome have been treated successfully with corticosteroids. Some patients require additional immunosuppressive drugs such as azathioprine, methotrexate, or cyclosporine if steroid resistance, recurrence of uveitis, or significant steroidal side effects occur (10).

In conclusion, patients with renal insufficiency should be questioned in detail (such as burning, stinging, blurred vision) in terms of the findings that could definitely indicate ocular disease, and these should be taken care of, and their eye examinations should be done. All these can be a guide for a disease such as TINU syndrome which may be rarely responsible for the etiology.

Table 1

Demographic Factors and Categorization of Ocular Disease for Reported Patients with TINU Syndrome

Age (n= 425)	
Median	26.3 years
Range	6-74 years
Sex (n= 425)	
Female	281 (66.2 %)
Male	144 (33.8 %)
Category of uveitis (n= 425)	
Anterior	378 (88.9 %)
intermediate	10 (2.3 %)
Posterior	17 (4 %)
Panuveitis	20 (4.7%)
Laterality of uveitis (n= 425)	
Bilateral	402 (94.5 %)
Unilateral	23 (5.4%)

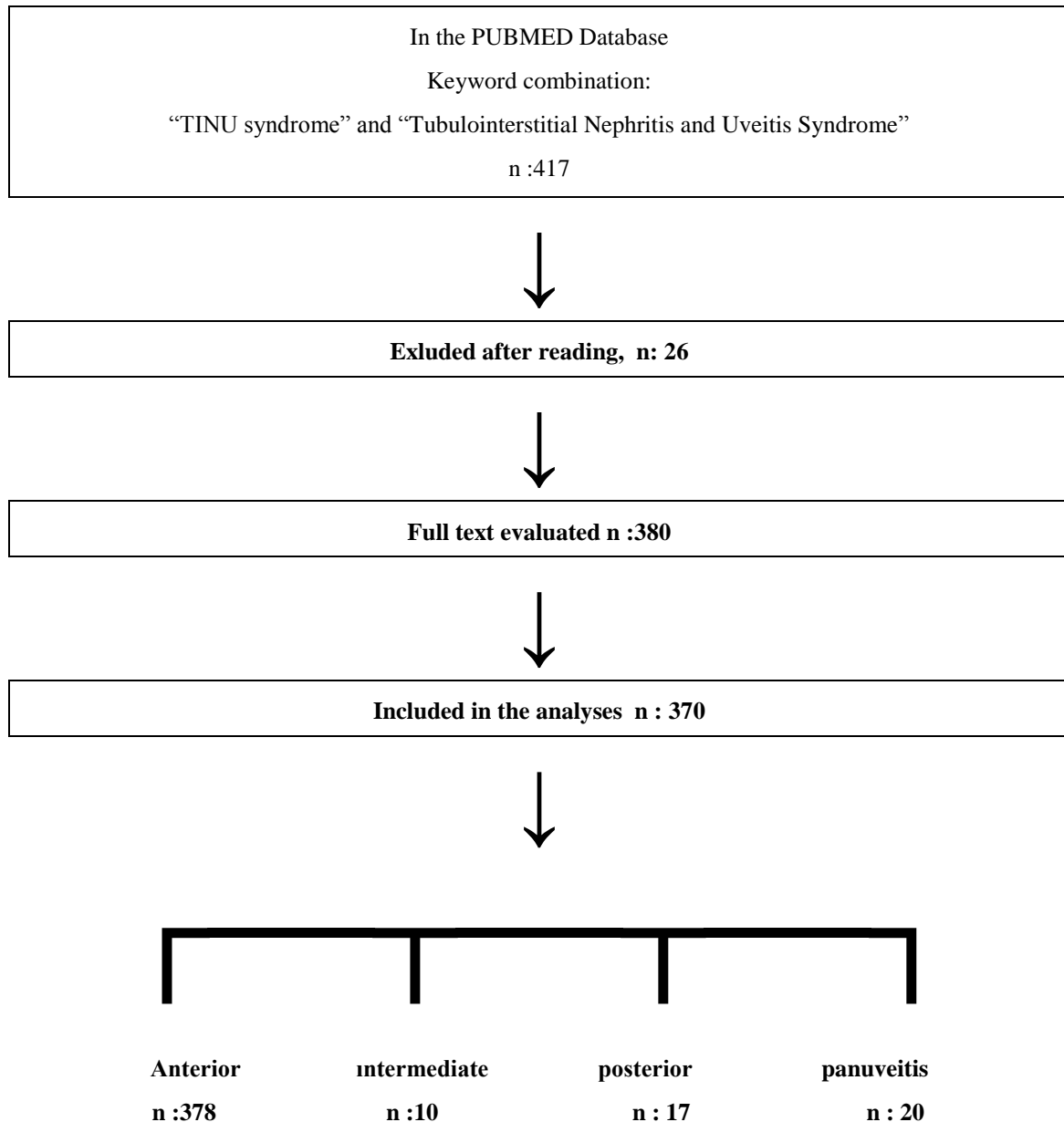


Figure 1: Data obtained from literature review and cases of uveitis

REFERENCES

1. Dobrin RS, Vernier RL, Fish AJ. Acute eosinophilic interstitial nephritis and renal failure with bone marrow lymph node granulomas and anterior uveitis. *Am J Med* 1975; 59: 325-33.
2. Vanhaesebrouck P, Carton D, De Bel C, Praet M, Proesmans W. Acute tubulo-interstitial nephritis and uveitis syndrome (TINU syndrome). *Nephron* 1985; 40:418-22
3. Gafter U, Kalechman Y, Zevin D, Korzets A, Livni E, Klein T, Sredni B, Levi J. Tubulointerstitial nephritis and uveitis: association with suppressed cellular immunity. *Nephrol Dial Transplant* 1993; 8: 821-6.
4. Wakaki H, Sakamoto H, Awazu M. Tubulointerstitial nephritis and uveitis syndrome with autoantibody directed to renal tubular cells. *Pediatrics* 2001; 107: 1443-6.

5. Tan Y, Yu F, Zhao M-H. Autoimmunity of patients with TINU syndrome. *Hong Kong J Nephrol* 2011; 13:46–50.
6. Levinson RD. Tubulointerstitial nephritis and uveitis syndrome. *Int Ophthalmol Clin* 2008;48:51-9
7. Mandeville, John TH, Ralph D. Levinson, and Gary N. Holland. "The tubulointerstitial nephritis and uveitis syndrome." *Survey of ophthalmology* 46.3 (2001): 195-208.
8. Ariba YB, Labidi J, Elloumi Z, Selmi Y, Othmani S. Acute tubulointerstitial nephritis and uveitis syndrome: A report on four adult cases. *Saudi J Kidney Dis Transpl.* 2017 Jan-Feb;28(1):162-166.
9. Matsumoto K, Fukunari K, Ikeda Y, et al. A Report of an adult case of Tubulointerstitial Nephritis and Uveitis (TINU) syndrome, with a review of 102 Japanese cases. *Am J Case Rep.* 2015;16:119–23.
10. Gion N, Stavrou P, Foster CS. Immunomodulatory therapy for chronic tubulointerstitial nephritis-associated uveitis. *Am J Ophthalmol* 2000;129:764-8.