

Marihuana suistimali ile ilişkili yineleyen inme

Recurrent stroke associated with marijuana abuse

Semih GİRAY¹, Betül GULALP², Mehmet KARATAS¹,
Mehmet NUR ALTINORS², Ufuk CAN¹

1 Department of Neurology, Baskent University, Ankara, Turkey
2 Department of Emergency Medicine, Baskent University, Ankara, Turkey

ABSTRACT

Introduction: It is one of most abused substances all over the world. It is produced from the Cannabis sativa and induces its main effects by delta-9-tetrahydrocannabinol [THC]. Clinical effects consist in respiratory, central nervous system, psychiatric health, and these are generally transient. This report presents a complicated mortal case followed with chronic use.

Case Report: A 35-year-old male patient was brought to the emergency department with unconsciousness, agitation and acute right hemiplegia. There was only a chronic infarction on cerebral computerised tomography. All the laboratory results were in normal range except fibrinogen and D-dimer. Cerebral Magnetic Resonance Imaging [MRI] and MR Angiography [MRA] showed the lesion to be related to an acute middle cerebral artery [MCA] infarction. Ecocardiography revealed cardiac akinesia and a decreased ejection fraction. On the third day of admission, his relatives explained his chronic regular abuse of high dose hashish, a kind of marijuana, for along time. Samples were sent to the laboratory for identification of all toxicological parameters; however THC was the only positive result. The clinical prognosis was very poor. He had died in the intensive care unit on the seventh day.

Conclusion: Marijuana can be seriously harmful to cardiovascular and cerebral systems with mortal complications in chronic use.

Keywords: Hashish, emergency department, stroke

Received: 31.12.2010

Accepted : 03.01.2011

ÖZET

Giriş: Tüm dünyada en çok suistimal edilen maddelerden biridir. Cannabis sativa bitkisinden elde edilir ve temel etkilerini delta-9-tetrahydrocannabinol [THC] ile oluşturur. Klinik etkileri solunum sistemi, santral sinir sistemi, psikiyatrik olarak meydana gelir ve bunlar genellikle geçicidir. Bu rapor kronik kullanımı izleyen komplike ölümcül bir olguyu sunmaktadır.

Olgu sunumu: 35 yaşında erkek hasta acile bilinç bozukluğu, ajitasyon ve akut sağ hemipleji ile getirildi. Beyin tomografisinde yalnız kronik infarkt vardı. Fibrinojen ve D-Dimer dışında tüm laboratuvar sonuçları normal aralıkta idi. Beyin Magnetik Rezonans Görüntüleme [MRG] and MR Angiografi [MRA] akut orta serebral arter [OSA] infarktüsüne bağlı lezyonu gösterdi. Ekokardiografi kalp akinezisini ve azalan ejeksiyon fraksiyonunu açıkladı. Yatışının üçüncü günü, yakınları hastanın uzun zamandır bir marihuana çeşidi olan esrarı kronik olarak düzenli kullandığını açıkladılar. Tüm toksikolojik parametrelerin belirlenmesi için örnekler laboratuvara gönderildi, ama THC tek pozitif sonuçtu. Klinik prognoz oldukça kötüydü. Hasta yedinci gün yoğun bakımda kaybedildi.

Sonuç: Marihuana kronik kullanımında ölümcül komplikasyonlar ile kardiyovasküler ve serebral sistemlerde ciddi olarak zararlı olabilir.

Anahtar Kelimeler: Esrar, acil serviste, inme

Başvuru Tarihi: 31.12.2010

Kabul Tarihi :03.01.2011

Yazışma Adresi/Corresponding to:

Betül Gülalp

Baskent University

Department of Emergency Medicine Ankara-Turkey

GSM: 0 533 519 44 05

e-mail: docbetul@yahoo.com

INTRODUCTION

Hashish is a kind of cannabis obtained from the tops of flowers of the Indian hemp plant, *Cannabis sativa*.¹ It contains high concentrations of THC, which acts as a psychoactive substance. THC is hydrophobic, accumulates in lipid tissue and it is highly protein-bound. It is enterohepatically recirculated. The screening test in urine is designed to detect THC at levels of 20, 50, or 100 ng/mL and it may be positive for up to 70 days or more as it has a slow elimination from the body. *Cannabis sativa* contains a number of other resins known as cannabinoids, which are found in small concentrations. These cannabinoids may induce acute and chronic medical problems.¹ Cannabinoids inhibit adenylyclase, probably through interaction with an inhibitory G-protein. The enzyme becomes unable to convert adenosine triphosphate into the 'second messenger' cyclic adenosine monophosphate.² Recent reports showed that marihuana could seriously affect the systems and trigger complications such as myocardial infarction in acute abuse, and lung disease in chronic abuse, in addition to perceptual disorders.

CASE REPORT

A 35-year-old male was brought to the emergency unit after having fallen down in a public bus. There was not a detailed family history as they avoid to come to the hospital and share any knowledge. He had no relatives with him in admission, his past medical history was obtained from an acquaintance, which revealed that he had suffered a myocardial infarction and a left hemiparesis syndrome the previous year.

On presentation, his Glasgow Coma Scale score was 8. Vital signs were: temperature: 37°C; pulse: 83 beats/min; respiratory rate: 27 breaths/min; blood pressure: 150/90 mmHg; and pulseoximetry: 73. The patient was unconsciousness, agitated and right hemiplegic on the first examination. Complete right hemiplegia and right positive Babinski were distinct. There were no another pathologic findings on his physical examination. His fingerstick blood glucose was 100 mg/dL. The patient was rapidly intubated and ventilated with induction by 10 mg diazepam and then 10 mg vecuronium through an intravenous access placed at the antecubital fossa for parenteral treatment. Cerebral CT showed chronic infarction containing the basal ganglia, particularly on the frontotemporal part of the right hemisphere [Fig-1(a)]. The white blood cell count and biochemical parameters such as BUN, Cr, SGOT, SGPT, Na, and K were in the normal range. Cardiac enzymes, APTT, and PT were also normal. The first and the consecutive troponin values were 0.00 ng/ml. Fibrinogen was 6.3 g/L, and D-dimer was 316 µg/mL. Protein S, Protein C, Antithrombin III, Antiphospholipid antibodies, ANA, and HIV analyses all revealed negative results. Pleural effusion was a transudate. Cerebral and diffusion MRI revealed encephalomalacia consistent with right frontotemporoparietal chronic infarction which contained the caudate nucleus and the lentiform nucleus, in addition to an acute infarct on the same part of the left hemisphere of the brain [Fig-1(b), 2(a), 2(b)]. There was a left cerebral MCA occlusion on the cerebral MR Angiography [Fig-2(c)]. Echocardiography performed by an experienced Cardiologist demonstrated akinesia of the septum, apex and the anterior part of the heart, and the Ejection Fraction was 35%. No thrombus was detected. Glycerol trinitrat 10 mcg/min, enoxiparin sodium 0.4 cc, 2 times/d, mannitol 100 cc, 4 times/d, ranitidine 50 mg, 4 times/d, midazolam 0.1 mg/kg/h were used. There was not realised a withdrawal syndrome as sedation. On the third day, his

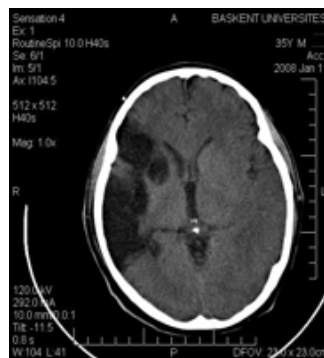

Figure 1 a. Cerebral CT of the patient in the emergency department; chronic right MCA infarction.

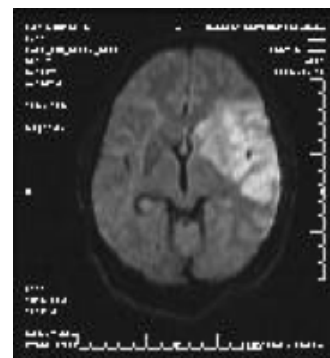


Figure 1 b. Diffusion-weighted MRI of the patient reveal acute infarction on the left hemisphere.

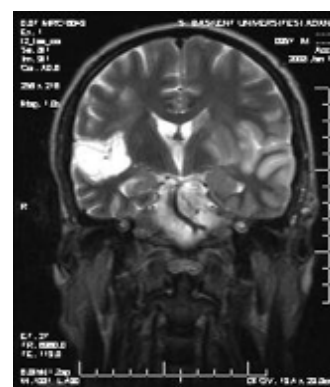
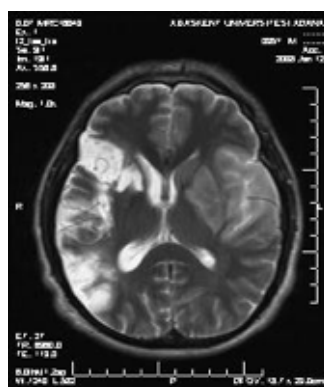


Figure 2 a and 2 b. Axial and coronal T2 weighted images show left sided acute infarction and right sided chronic infarction.

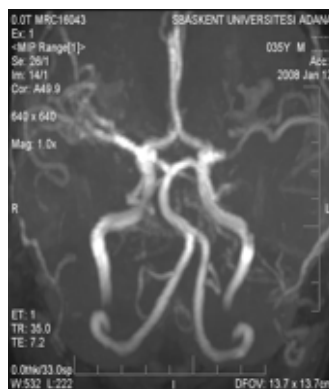

Figure 2 c. Cerebral MR angiography of the patient; Left MCA occlusion.

relatives described that he had been using hashish for a long time, on a regular basis.

With a consent of the relatives, blood samples were sent to the laboratory for identification of toxicological substances such as THC, ethylalcohol, methylalcohol, COHb, pesticides, narcotics and other drugs. The THC level was found to be 40 ng/L. Despite all the efforts at the intensive care unit, he died on the seventh day due to MCA infarct and pulmonary edema.

DISCUSSION

Hashish is a kind of marijuana which can be purchased illegally in many countries.³ A specific cannabinoid receptor is located in the cerebral cortex, which is associated with the pharmacological effects of marijuana. Certain neuronal membranes contain receptors that bind to THC, thereby producing pharmacological effects.¹ The central effects of cannabinoids reported as disruption of psychomotor behaviours, short-term memory impairment, intoxication, stimulation of appetite, anti-nociceptive actions and anti-emetic effects.^{4,5} Cognitive impairment of various types were observed during acute intoxication in a recent report.² The onset and the grade of the effects of marijuana appertain to the concentration of THC. The psychological effects were mentioned without dose dependent, but the physiological effects were relevant.¹ The adverse effects of chronic use can be on the respiratory, cardiovascular, and the central nervous systems, in addition to effects on the psychological status.⁶ Similar to tobacco smoking, THC can lead to chronic lung disease and carcinogenesis. Lung parenchymal damage and bullous lung disease due to marijuana have been described.⁴ Heavy marijuana use has been shown to have a residual neuropsychological effect not seen with mild users who abuse it in less than 3 days a month. Increase in heart rate is common, but the blood pressure response is variable.¹ The chronic effects on the cardiovascular system are not clear. There are a few studies claiming that chronic use may permanently damage the brain; however, there is yet no proof.² Hepatotoxicity and myocardial infarction (MI) have been reported.^{6,7} In spite of the fact that the case had a history of myocardial infarction the previous year, cardioembolic stroke was not considered to be the primary reason in explaining the mortal cerebral ischemia, since most cardioembolic strokes are seen to be associated in the first 3-month period after an MI.⁸

There was not a witness explained the period between being exposed to the substance and the stroke. However, 15 minutes was reported in having a stroke after exposure of cannabis in a case.⁹ Another case had a posterior cerebral artery infarction after 30 minutes of smoking the substance.¹⁰ Both of them were transient. The results of the blood analyses of the patient on the third day were consistent with chronic regular use as the general detection times for daily use of THC were 10 days to 4 weeks. The inotropic effect on the cardiovascular system and increased airway resistance can induce systolic functional defects with akinetic areas on the left ventricle possibly provoked following the recent infarctions, in addition to bilateral pleural fluid in the long run. Theoretically, despite the fact that decreased ejection fraction and widespread hypokinesia create a risk for thrombus formation, a definite relation with the etiology of stroke is still controversial.¹¹

Two recent reviews revealed a possible relationship between marijuana use and cerebrovascular ischemia and infarction.^{1,7} The mechanism by which marijuana could produce cerebral ischemia in young adults without other predisposing conditions is unclear, but vasospasm seems to be the most likely mechanism, as the vasoconstrictive effects of THC have been documented in animals.²

Other possible mechanisms of cannabis related in stroke were

reported as systemic hypotension, altered cerebral autoregulation, altered cerebral blood flow, vasculitis, cerebral vasoconstriction syndrome, cardioembolism with atrial fibrillation.¹² More than one of them could be associated in cannabis consumption. However there has not found an evidence explained the reason in stroke, yet.

Furthermore, THC addiction was reported to be associated with recurrent cerebrovascular attacks according to the acute vasospastic effects and altered cerebral autoregulation, altered cerebral blood flow, however our case had an MCA infarct differed from literature.¹²⁻¹⁴

CONCLUSION

We therefore conclude that a young person without apparent risk factors, but with long-standing THC use, could have serious cardiovascular, respiratory and cerebral events. Consequently, clinical toxicology is valuable in the evaluation of diagnostic studies in emergency medicine. Chronic marijuana use can be the trigger of mortal complications such as serious cerebral infarction with cardiac pathology. Pathophysiological studies are required to prove this. Consequently, mortal cerebrovascular ischemia could be associated with vasospasm in THC addiction.

- This case report had presented as an abstract in 6 th World Stroke Congress. Vienna, Austria 2008.

REFERENCES

1. Goldfrank LR, Flomenbaum NE, Lewin NA, Weisman RS, Howland MA, Hoffman RS: Marijuana. Goldfrank's Toxicologic Emergencies. Part D. 6th edition. Edited by Goldfrank LR. Appleton and Lange 1998:1121-1125.
2. Iversen L. Cannabis and the brain: Brain 2003;126:1252-1270.
3. Clough A, Conigrave K. Managing confidentiality in illicit drugs research: ethical and legal lessons from studies in remote Aboriginal communities. Intern Med J 2008;38:60-3.
4. Hii SW, Tam JD, Thompson BR, Naughton MT: Bullous lung disease due to marijuana. Respirology 2008;13:122-7.
5. Nixon PJ. Health effects of marijuana: a review. Pac Health Dialog 2006;13:123-9.
6. Borini P, Guimaraes RC, Borini SB: Possible hepatotoxicity of chronic marijuana usage. Sao Paulo Med J 200;122:110-6.
7. Charles R, Holt S, Kirkham N: Myocardial infarction and marijuana. Clin Toxicol 1979;14:433-8.
8. Cairns JA, Theroux P, Lewis HD. Antithrombotic agents in coronary artery disease. Chest 1998;114:611S-633S.
9. Finsterer J, Christian P, Wolfgang K. Occipital stroke shortly after cannabis consumption. Clin Neurol Neurosur 2004;106:305-8.
10. Alvaro LC, Iriundo I, Villaverde FJ. Sexual headache and stroke in a heavy cannabis smoker. Headache 2002;42:224-6.
11. Vaitkus PT, Barnathan ES. Embolic potential, prevention and management of mural thrombus complicating anterior myocardial infarction: a meta-analysis. J Am Coll Cardiol 1993;22:1004-9.
12. Thanvi BR, Treadwell SD. Cannabis and stroke: is there a link? Postgrad Med J 2009;85:80-3.
13. Moussouttas M. Cannabis use and cerebrovascular disease. Neurologist 2004;10:47-53.
14. Mateo I, Infante J, Gomez Beldarrain M, et al: Cannabis and cerebrovascular disease. Neurologia 2006;21:204.