

Exogenous Lipoid Pneumonia Due To Intramuscular Injection of Synthol in a Bodybuilder

Vücut Geliştiricide İntramuskuler Synthol Enjeksiyonuna Bağlı Lipoid Pnömoni

Nesrin ÖCAL¹, Armağan GÜNAL², Yakup ARSLAN¹, Berat KAÇMAZ¹, Ali COŞKUN²,
Bahadır Can KARAN¹, Deniz DOĞAN¹, Cantürk TAŞÇI¹, Ergün UÇAR¹

¹Health Sciences University, Gulhane Medical Faculty, Department of Chest Diseases, Ankara
²Health Sciences University, Gulhane Medical Faculty, Department of Medical Pathology, Ankara

Abstract

We report a case of chronic exogenous lipoid pneumonia that developed due to recurrent intramuscular use of "Synthol", a synthetic oil derivative, for muscle filling. 40-year-old man, who had used Synthol to enlarge his pectoral muscles, was admitted to the chest diseases polyclinic with shortness of breath progressing within a year. On computerized tomography of thorax there were reticulations and septal thickenings consistent with interstitial lung disease. The patient underwent bronchoscopy. Bronchoalveolar lavage and transbronchial biopsy (TBB) were performed. In the histopathologic study of TBB, intraalveolar and interstitial fatty macrophages, giant cells around fat particles and extracellular fat particles were observed and the specimen was reported as "lipoid pneumonia". According to our knowledge, exogenous lipoid pneumonia due to intramuscular use of Synthol has not been reported heretofore and this is the first case in the literature.

Keywords: Bodybuilder, Lipoid Pneumonia, Synthetic Oil, Synthol

Öz

Bu makalede kas dolgusu amacıyla sentetik bir yağ türevidir olan "Synthol" un tekrarlayan intramuskuler kullanımı nedeniyle gelişen kronik eksojen lipoid pnömoni olgusu sunulmuştur. Göğüs kaslarını büyütmek için Synthol kullanan 40 yaşında erkek hasta, bir yıl içinde ilerleyen nefes darlığı ile birlikte polikliniğimize başvurdu. Toraks tomografisinde interstisyel akciğer hastalığı ile uyumlu retikülasyonlar ve septal kalınlaşmalar izlenmekteydi. Hastaya bronkoskopi yapıldı. Bronkoalveolar lavaj ve transbronşiyal biyopsi (TBB) alındı. TBB'nin histopatolojik incelemesinde, intraalveoler ve interstisyel yağlı makrofajlar, yağ partikülleri etrafındaki dev hücreler ve ekstraselüler yağ partikülleri gözlemlendi. Örnek "lipoid pnömoni" olarak raporlandı. Bizim bilgimize göre Synthol'un intramuskuler kullanımına bağlı eksojen lipoid pnömonisi şimdiye kadar bildirilmemiştir ve olgumuz literatürdeki ilk olgudur.

Anahtar Kelimeler: Lipoid Pnömoni, Sentetik Yağ, Synthol, Vücut Geliştirme

Introduction

Lipoid pneumonia is a rare pulmonary disease characterized by non-infectious inflammatory pneumonitis accompanied by alveolar lipid accumulation. In fact, the pathological description of lipoid pneumonia is the development of a chronic foreign body reaction to oil in the respiratory tract (1, 2). It is distinguished into two groups depending on whether the lipid or fat content in the respiratory tract origins from an endogenous or exogenous source. Several cases with exogenous lipoid pneumonias due to aspiration or inhalation of fat derivatives have been reported (3). However, chronic lipoid pneumonia associated to intramuscular injections is not common. In this

article, we present a case of chronic exogenous lipoid pneumonia that developed quietly after recurrent intramuscular use of "Synthol", a synthetic oil derivative, for muscle filling. According to our knowledge, exogenous lipoid pneumonia due to Synthol use has not been presented in the current literature heretofore.

Case

A 40-year-old bodybuilder man was admitted to the chest diseases polyclinic with complaints of shortness of breath progressing within a year. There was no known chronic illness story. Vital findings were stable and SpO₂ in room air was measured as 88%. On the inspection, all striated muscle structures of the body were observed as hypertrophic, with pectoral and brachial muscles being more prominent (Fig. 1). At the auscultation, respiratory voices were heard as rough, no crackle and rhonchus were heard. When the patient's story was deepened, it was learned that he had used long-acting protein dust and testosterone hormone supplements, and that over the last 1.5 years he had injected an oil-based filling substance called "Synthol" into the pectoral and brachial muscles of his body at various times. On computerized tomography, widespread ground glass opacities accompanied by messy consolidations, interlobular septal thickenings and reticulations, which were more prominent in subpleural areas in

	ORCID No
Nesrin ÖCAL	0000-0002-3789-7769
Armağan GÜNAL	0000-0002-9923-926X
Yakup ARSLAN	0000-0002-9079-1701
Berat KAÇMAZ	0000-0001-8104-6921
Ali COŞKUN	0000-0003-2286-0135
Bahadır Can KARAN	0000-0003-1559-6516
Deniz DOĞAN	0000-0003-2596-3113
Cantürk TAŞÇI	0000-0002-8789-7775
Ergün UÇAR	0000-0002-1559-6516

Başvuru Tarihi / Received: 31.08.2018
Kabul Tarihi / Accepted : 28.09.2018

Adres / Correspondence : Nesrin ÖCAL
Health Sciences University, Gulhane Medical Faculty,
Department of Chest Diseases, Ankara
e-posta / e-mail : serkanergozen@mu.edu.tr

both lungs, were observed (Fig. 2). Taking into account the anamnesis about the various drug uses, bronchoalveolar lavage (BAL) and transbronchial biopsy (TBB) were performed by bronchoscopy with a preliminary diagnosis of drug-induced interstitial lung disease. BAL cell count showed eosinophilia of 19.8%. There was no microbiological culture positivity in BAL. In the histopathologic study of lung TBB and the cytopathological examination of BAL specimen; intraalveolar and interstitial fatty macrophages, giant cells around fat particles and extracellular fat particles were observed. Final pathological identification of these specimens was reported as "lipoid pneumonia" (Fig. 3A-D).

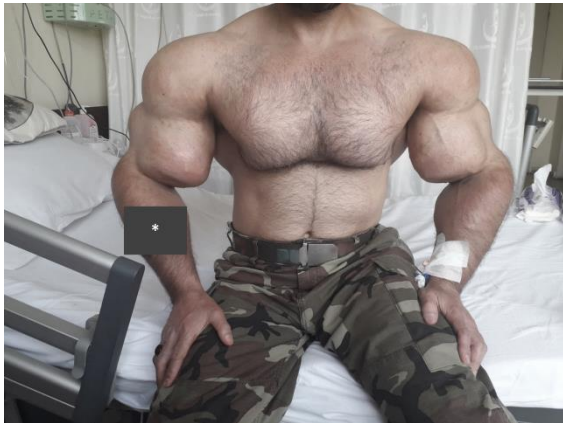

Figure 1. The striated muscles of the patient's upper body were extremely large and distinct. In addition, there were abnormal fullness deformities in the regions of the pectoral region and upper arm muscles. (*The tattoo was hidden to protect the identity of the patient)

Considering the use of oil-based filler, the radiological and clinical findings and pathological findings, the patient was diagnosed as a case of exogenous lipoid pneumonia due to intramuscular use of Synthol. Methylprednisolone therapy at 0.5 mg/kg/day dosage was initiated. On the 7th day of treatment, significant radiological improvement was observed in reticular lesions (Fig. 4A and B). Clinical signs and symptoms were significantly improved with the ongoing steroid treatment. Patient's consent form about the medical, educational and scientific use of his data and photo was obtained.

Discussion

Lipoid pneumonia is one of the rare lung pathologies and no large case series have been reported in the current literature yet. It was first described by Laughlen (4) in 1925. Afterwards, only sporadic cases were reported. According to the origin of the fat particles which infiltrate and accumulate in alveolar space and alveolar macrophages, lipoid pneumonia is divided into two groups as endogenous and exogenous lipoid pneumonias. Endogenous lipoid pneumonia may be

primary or secondary to frequently chronic obstructive pneumonia. It can also be developed by cholesterol and/or ester derivatives secreted from inflammatory lesions (5, 6). Exogenous lipoid pneumonias are most often caused by aspiration or inhalation of exogenous oil molecules. Exogenous lipoid pneumonia cases can manifest themselves with an acute pattern with a rapid onset when abundant quantities of the oil component are inhaled in a short time, as well as a chronic pattern with recurrent uptake of small amounts of oil molecules over long periods of time. Aspiration of many oil derivatives such as liquid paraffin, kerosen, petroleum jelly, mineral oil laxatives, oil based nasal drops, milk, poppy seed oil and egg yolk have been reported as the main origin of exogenous lipoid pneumonia in several cases (7, 8).

In this paper, we present a case of lipoid pneumonia that had been developed secondary to recurrent intramuscular injection, not due to inhalation or aspiration, of a synthetic oil derivative. In the current literature, an acute case of lipoid pneumonia has been reported following intramuscular anabolic steroid injection (9). In this case, it was determined that the patient accidentally injected the drug intravenously and progressed rapidly to an ARDS-like status. In the literature, the case of acute lipoid pneumonia that develops in a woman who injects a liquid silicone filler for cosmetic purposes into the hip region is partially similar to our case (10). The existence of this case was described as an acute situation, presented with cough and shortness of breath that developed suddenly after an hour from the injection procedure. In our case, the clinical situation was more insidious and has emerged with an increasing dyspnea during the last year.

Oil derivatives as tissue filler were first used in 1899 with cosmetic purposes for breast enlargement and filling the skin wrinkles (11). There have been many reports of health problems from all over the world in recent years about synthetic fillers, which are known to have an increased and uncontrolled use by bodybuilders (12). Synthol, one of the most preferred synthetic oils for this purpose, consists of 85% fat (medium chain triglycerides), 7.5% lidocaine and 7.5% alcohol (13). Several clinical complications related to the use of Synthol have been reported. The most commons of these are extrapulmonary problems, mainly muscle injuries, neuronal damage and infections (14). As a pulmonary complication due to Synthol use, only one case with fat embolism has been reported in the pneumotox.com (15). According to our knowledge, exogenous lipoid pneumonia due to Synthol use has not been presented in the current literature heretofore. In this respect, our case is of great importance as being the first exogenous pneumonia case due to intramuscular use of Synthol in the literature.

As a result, it has been observed in recent years that the use of Synthol-labelled substance, a synthetic oil derivative, known to be increasingly uncontrollable among young people who seek for a rapid and easy way of having excessively large muscles and body-build. Unfortunately; Synthol, which has been supposed to be an innocent oil derivative, can lead to lipid pneumonia and cause

significant respiratory failure. Therefore, the use of Synthol should be controlled as soon as possible and the community should be informed about possible complications of inconvenient applications of it. We believe that, besides being the first case in the literature, this paper will be useful to clinicians by drawing attention to the contingency of lipid pneumonia due to Synthol injection.

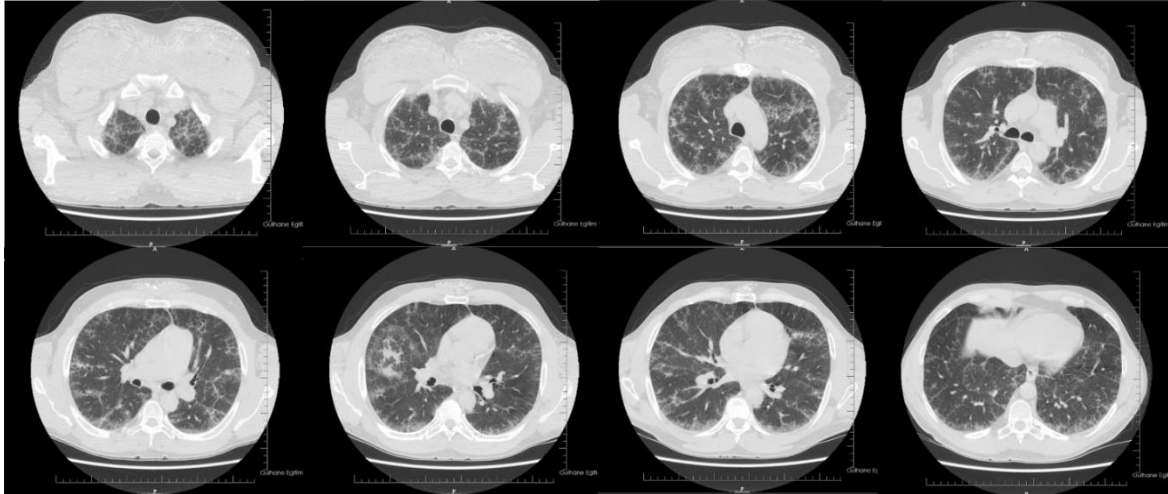


Figure 2. On computerized tomography, widespread ground glass opacities accompanied by messy consolidations, interlobular septal thickenings and reticulations, which were more prominent in subpleural areas in both lungs, were observed.

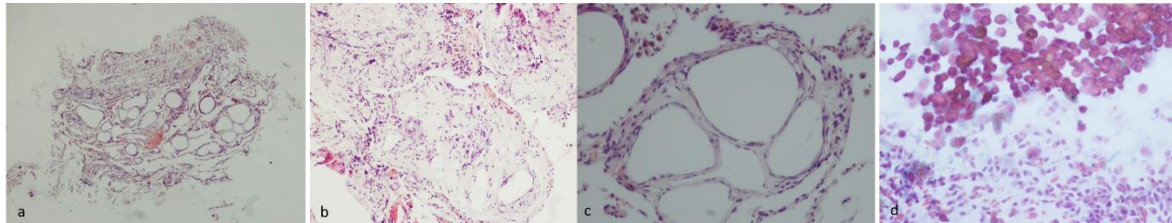


Figure 3. Typical appearance of lipid pneumonia morphology. Multinuclear giant cells and cavities surrounded by lipid-laden macrophages (H & E stained transbronchial lung biopsy (a) 40x (b) 100x (c) 200x). Lipid-loaded macrophages are seen in PAP-stained bronchoalveolar lavage (d) 200x.

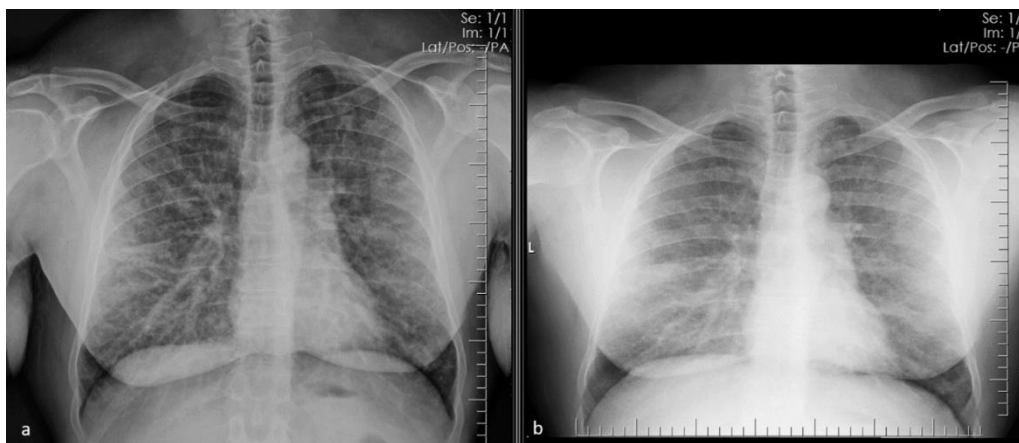


Figure 4. At the end of the first week of treatment with corticosteroids findings on chest x-ray were recorded. Chest X-ray before the treatment (a), and chest X-ray after the first week of treatment (b).

Informed Consent: Written informed consent was obtained from patient who participated in this case (14.05.2018).

References

1. Gondouin A, Manzoni PH, Ranfaing E, et al. Exogenous lipid pneumonia: a retrospective multicentric study of 44 cases in France. *Eur Respir J.* 1996;9:1463-9.
2. Cherrez Ojeda I, Calderon JC, Guevara J, Cabrera D, Calero E, Cherrez A. Exogenous lipid pneumonia related to long-term use of Vicks VapoRub by an adult patient: a case report. *BMC Ear, Nose Throat Disord.* 2016;16:11.
3. Betancourt SL, Martinez-Jimenez S, Rossi SE, Truong MT, Carrillo J, Erasmus JJ. Lipoid pneumonia: spectrum of clinical and radiologic manifestations. *Am J Roentgenol.* 2010;194:103-9.
4. Laughlin GF. Studies of pneumonia following injections of oil. *Am J Pathol.* 1925;1:407-14.
5. Marchiori E, Zanetti G, Mano CM, Irion KL, Daltro PA, Hochegger B. Lipoid pneumonia in 53 patients after aspiration of mineral oil: comparison of high-resolution computed tomography findings in adults and children. *J Comput Assist Tomogr.* 2010; 34(1): 9-12.
6. Rahaghi F, Varasteh A, Memarpour R, Tashtoush B. Teppanyaki/Hibachi Pneumonitis: An Exotic Cause of Exogenous Lipoid Pneumonia. *Case Rep Pulmonol.* 2016; 2016: 1035601.
7. Hotta T, Tsubata Y, Okimoto T, Hoshino T, Hamaguchi S, Isobe T. Exogenous lipid pneumonia caused by herbicide inhalation. *Respirol Case Rep.* 2016;4(5): e00172.
8. Yasui H, Yokomura K, Suda T. A severe case of acute exogenous lipid pneumonia treated with systemic corticosteroid. *Respir Med Case Rep.* 2016;17: 64-7.
9. Russell M, Storck A, Ainslie M. Acute respiratory distress following intravenous injection of an oil-steroid solution. *Can Respir J.* 2011;18(4): 59-61.
10. Fumo G, Ferrelli C, Murgia S, Galletti R, Pau M. A serious complication due to liquid silicone injection in the legs for cosmetic purpose. *Clin Ter.* 2013;164(5):377-9.
11. Gersuny R. Ueber eine subcutane Prothese. *Z Heilk.* 1900;30:1-5.
12. Pupka A, Sikora J, Mauricz J, Cios D, Plonek T. The usage of synthol in the body building. *Polim Med.* 2009;39:63-5.
13. Ghandourah S, Hofer MJ, Kießling A, El-Zayat B, Schofer MD. Painful muscle fibrosis following synthol injections in a bodybuilder: a case report. *J Med Case Rep.* 2012;6:248.
14. <https://www.pneumotox.com/drug/view/1171/synthol>