

■ Original Article

## Analysis of myocardial texture in patients with isolated left ventricular noncompaction

### *İzole sol ventrikül noncompaction olan hastalarda miyokard dokusunun analizi*

Sefa UNAL , Burak ACAR , Cagri YAYLA\* , Ahmet Goktug ERTEM , Omac TUFEKCIOGLU , Dursun ARAS 

Turkiye Yuksek Ihtisas Education and Research Hospital, Department of Cardiology, Ankara/TURKEY

#### ABSTRACT

**Aim:** Videodensitometric myocardial texture analysis (VMTA) has been widely used to investigate left ventricular (LV) dysfunction in various cardiac disorders. Patients with isolated left ventricular noncompaction (IVNC) experience an undulating decline in LV function. The aim of this study was to assess the value of VMTA for evaluating deterioration of LV function in this patient group.

**Material and Methods:** Twenty-two patients with IVNC (10 asymptomatic [preserved LV function], 12 symptomatic [LV dysfunction]) and 12 healthy controls were evaluated. Videodensitometry was used to record background-corrected mean gray levels (BC-MGL) for 2 regions of the mid-basal LV wall (the interventricular septum [IVS] and the posterior wall [PW]) at end-systole and end-diastole. The cyclic variation (CV) index for each region was calculated according to the formula,  $CV \text{ index } \% = ([BC-MGL_{\text{end-diastole}} - BC-MGL_{\text{end-systole}}] \div BC-MGL_{\text{end-diastole}}) \times 100$ .

**Results:** The mean IVS-CV index in the symptomatic IVNC group ( $12.3 \pm 4.9\%$ ) was significantly lower than the corresponding findings in the asymptomatic IVNC group ( $32.3 \pm 14.8\%$ ,  $p < 0.05$ ) and control group ( $36.6 \pm 12.1\%$ ,  $p < 0.001$ ). The mean PW-CV index in the symptomatic group ( $15.1 \pm 5.5\%$ ) was also significantly lower than the corresponding values in the asymptomatic ( $27.0 \pm 10.4\%$ ,  $p < 0.05$ ) and control groups ( $28.8 \pm 10.9\%$ ,  $p < 0.001$ ).

**Conclusion:** VMTA is a practical, useful adjunct to conventional echocardiography for assessing LV myocardium in patients with IVNC. Detection of reduced CV index values might predict the early stages of LV deterioration in this group.

**Keywords:** videodensitometric myocardial texture analysis; isolated left ventricular noncompaction; cardiomyopathy; heart failure; non-invasive cardiac imaging

Corresponding Author\*: Cagri YAYLA, Turkiye Yuksek Ihtisas Education and Research Hospital, Department of Cardiology, Ankara/TURKEY

E-mail: cagriyayla@gmail.com

ORCID: 0000-0002-5302-4502

Received: 24.01.2019 accepted: 31.01.2019

Doi: 10.18663/tjcl.517548

## ÖZ

**Amaç:** Videodensitometrik miyokardiyal doku analizi (VMTA), çeşitli kardiyak hastalıklarda sol ventrikül (LV) disfonksiyonunu araştırmak için yaygın olarak kullanılmıştır. İzole sol ventrikül noncompaction (IVNC) olan hastalar LV fonksiyonunda dalgalı bir düşüş yaşarlar. Bu çalışmanın amacı, bu hasta grubunda LV fonksiyonunun bozulmasını değerlendirmek için VMTA değerini değerlendirmektir.

**Gereç ve Yöntemler:** IVNC'li 25 hasta (10 asemptomatik [korunmuş LV fonksiyonu], 12 semptomatik [LV disfonksiyon]) ve 12 sağlıklı kontrol olacak şekilde değerlendirildi. Sistol sonunda ve diyastolde orta bazal LV duvarının 2 bölgesi (interventriküler septum [IVS] ve arka duvar [PW]) için arka plan düzeltmeli ortalama gri seviyelerini (BC-MGL) kaydetmek için videodensitometri kullanıldı. Her bölge için sıklık varyasyon (CV) indeksi, formül CV'ye göre hesaplandı, CV indeksi, % =  $\frac{[BC-MGL_{end-diastol} - BC-MGL_{end-sistol}]}{BC-MGL_{end-diastol}} \times 100$ .

**Bulgular:** Semptomatik IVNC grubundaki ortalama IVS-CV indeksi (%  $12.3 \pm 4.9$ ), asemptomatik IVNC grubundaki (%  $32.3 \pm 14.8$ ;  $p < 0.05$ ) ve kontrol grubundaki (%  $36.6 \pm 12.1$ ) karşılık gelen bulgulardan anlamlı olarak düşüktü ( $p < 0.001$ ). Semptomatik gruptaki ortalama PW-CV indeksi (%  $15.1 \pm 5.5$ ), asemptomatik ( $27.0 \pm 10.4$ ;  $p < 0.05$ ) ve kontrol gruplarındaki ( $28.8 \pm 10.9$ ;  $p < 0.001$ ) karşılık gelen değerlerden anlamlı olarak düşüktü.

**Sonuç:** VMTA, IVNC'li hastalarda LV miyokardiyumu değerlendirmek için konvansiyonel ekokardiyografiye pratik ve faydalı bir yardımcıdır. Azaltılmış CV indeks değerlerinin tespiti, bu grupta LV bozulmasının erken aşamalarını öngörebilir.

**Anahtar kelimeler:** videodensitometrik miyokardiyal doku analizi; izole sol ventrikül noncompaction kardiyomiyopati; kalp yetmezliği; non-invaziv kalp görüntüleme

## Introduction

Isolated left ventricular noncompaction (IVNC) is a congenital form of cardiomyopathy that has not yet been classified by the World Health Organization [1]. In early life, the myocardium of the left ventricle (LV) undergoes a distinct form of morphogenesis characterized by changes in the trabecular patterning on the endocardial surface [2]. During normal morphogenesis, the myocardium becomes condensed and large recesses in the trabecular meshwork flatten out or completely disappear [2]. If this process is arrested, the result is ventricular noncompaction [3-5]. Initial studies suggested that noncompaction was associated with grave prognosis due to heart failure, embolic events and malignant arrhythmias [4-8]. However, subsequent research has demonstrated that the prognosis is not as grim as originally thought [7-9]. Thus, practical, non-invasive cardiac imaging techniques are important for monitoring the status and deterioration of the LV in patients with noncompaction.

Noncompaction is generally an abnormality of the LV apex and adjacent portions of the LV wall; it is unusual for the basal segments of the ventricle to be affected [4-7,9]. The role of conventional echocardiography for assessing or predicting ventricular deterioration in patients with early-phase IVNC remains controversial.

Videodensitometric myocardial texture analysis (VMTA) has been used to document the cyclic variation (CV) of myocardial acoustic properties in various cardiac disorders, including those of ischemic and non-ischemic origin [10-12]. In this study, we used this technique to assess the acoustic properties of LV myocardium in the setting of IVNC. Specifically, the videodensitometric findings for the LV aspect of the interventricular septum (IVS) and the posterior wall of the LV (PW) were evaluated in subgroups of patients with IVNC, and findings were compared to those in healthy subjects.

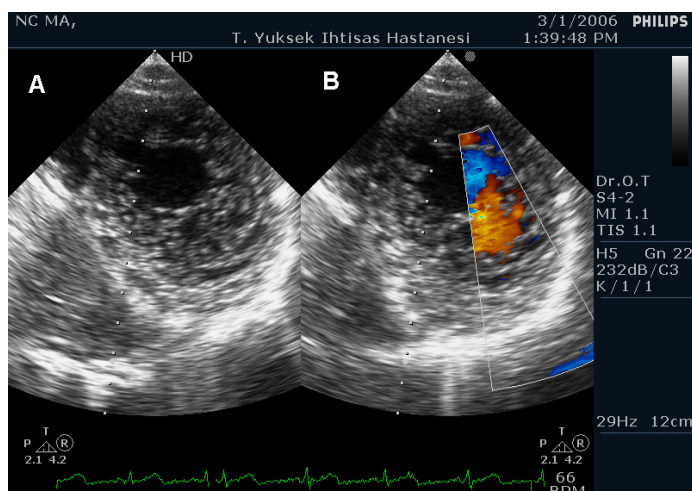
## Material and Methods

### Study Population

Between February 2013 and March 2016, 22 consecutive patients with IVNC (11 men and 11 women; mean age,  $38 \pm 14$  years) who met the inclusion criteria for this study (details below) were enrolled in the study. We also investigated 12 healthy hospital-staff volunteers (6 men and 6 women; mean age,  $39 \pm 14$  years) as controls. None of the controls had cardiovascular symptoms or evidence of any systemic disease, as assessed by physical examination, chest radiography, electrocardiography (ECG) and echocardiography.

The diagnostic criteria for IVNC were as follows: (1) absence of coexisting cardiac anomalies, (2) presence of excessive numbers of large trabeculae, (3) multiple deep intertrabecular

recesses filled with blood from the ventricular cavity, as demonstrated by color Doppler imaging, and (4) ratio of the thickness of the noncompacted endocardial layer to that of the compacted epicardial layer (NC/C ratio)  $\geq 2$  (6-9) (Fig 1). The exclusion criteria were rhythm other than sinus, bundle branch block, any pre-excitation syndrome, cardiogenic shock, significant valvular regurgitation or valvular stenosis, any systemic disease (diabetes, hypertension, goiter and others), neuromuscular disease at time of presentation, involvement of the right ventricle, clinical and ECG evidence of ischemic heart disease, stroke in the 2 months prior to the study, history of cardiotoxic agent use (chemotherapeutics or long-term alcohol consumption), hypertrabeculation on the side that the ROI would be positioned for VMTA.



**Fig. 1.** Modified apical view of the left ventricular apex in a patient with isolated left ventricular noncompaction. Two-dimensional echocardiography reveals the 2 layers of myocardium (compacted and noncompacted), excessive numbers of large trabeculae (Panel A), and multiple deep intertrabecular recesses filled with blood from the ventricular cavity as shown on color Doppler (Panel B).

For analysis, the 22 patients with IVNC were divided into 2 groups: an asymptomatic group ( $n = 10$ ; 5 men and 5 women; mean age,  $39 \pm 11$  years) and a symptomatic group ( $n=12$ ; 6 men and 6 women; mean age,  $36 \pm 12$  years). The 10 asymptomatic patients showed no clinical signs of heart failure (8 cases diagnosed during family screening, 2 diagnosed incidentally during echocardiography for other reasons). The 12 symptomatic individuals were in clinical heart failure and each had been hospitalized at least once for decompensated heart failure. These 12 patients were all taking appropriate medical therapy, such as diuretics,  $\beta$ -blockers, digitalis, anticoagulants and angiotensin-converting enzyme inhibitors.

Patients who were on medications that affect LV performance ( $\beta$ -blockers or digoxin) were taken off these drugs for at least 5 days before the echocardiographic examination was done.

All subjects were informed about the study and each gave written consent to participate.

### **Transthoracic Echocardiography**

Conventional M-mode, 2-dimensional and color Doppler images were obtained for all subjects using a commercially available echocardiography unit (Philips Ultrasound EnVisor C HD, Andover, MA, USA) with a 2- to 4-MHz phased-array multifrequency transducer. Subjects were all examined in left lateral decubitus position while breathing calmly. Imaging was done through parasternal and apical windows. LV end-diastolic diameter (LVEDD), LV end-systolic diameter (LVESD), thickness of the IVS during diastole, thickness of the PW during diastole, and maximal left atrial diameter (LAD) were measured from M-mode tracings according to the recommendations of the American Society of Echocardiography.

For each patient with IVNC, the number of regions/segments exhibiting noncompaction, the specific locations of these, and the NC/C ratio were recorded. As noted, the NC/C ratio was calculated based on the thicknesses of the 2 layers of myocardium (compacted and noncompacted). These measurements were taken at the site of the most prominent trabecular meshwork in end-systole, as this allowed best visualization of the layers [6]. Sites of noncompaction were recorded by dividing the LV wall into 16 regions/segments: the inferior wall, lateral wall, anterior wall, and septum on the short-axis apical view; the anterior septum, posterior septum, and the posterior, inferior, lateral and anterior LV walls on the short-axis mid-ventricular view and the short-axis basal view.

LV systolic function was assessed based on ejection fraction (EF) and fractional shortening (FS). LV EF was calculated from apical views using the biplane area length method [9]. FS was calculated from M-mode tracings of the parasternal long axis using the equation,  $FS (\%) = [(LVEDD - LVESD) \div LVEDD] \times 100$ . All examinations were conducted by the same observer (O.T.). For each parameter, the mean value calculated from 3 consecutive heartbeats was recorded.

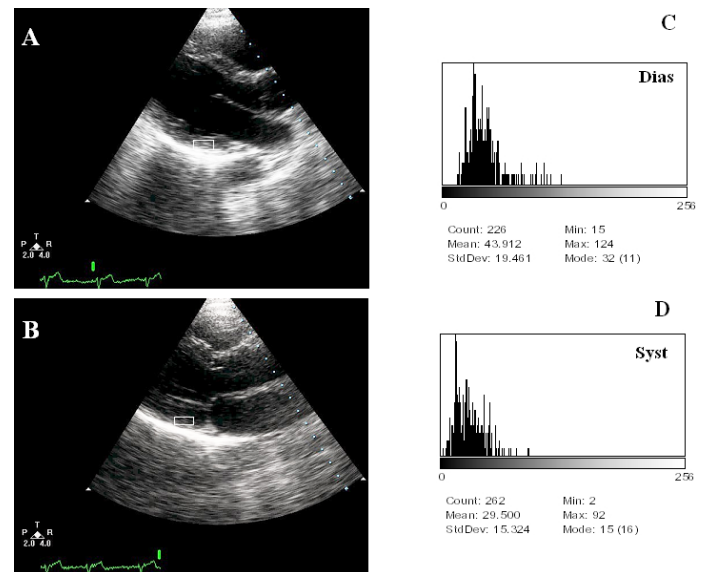
### **Videodensitometric Analysis of Myocardial Texture**

The same gain settings and compensation profiles were used for all participants to achieve approximately uniform brightness of the IVS and PW throughout all the echocardiography exams. Harmonic imaging was not used, and the gray-scale

transfer function was adjusted to be linear at a depth of 16 to 18 cm. Dynamic range, emission power, focal plane, filters, and overall gain were adjusted to fixed settings in all the exams so as to minimize noise on the image. To avoid bias in data analysis, the manual adjustment for depth gain compensation (linear curve) was kept at zero. Care was taken to ensure that the angle of incidence of the ultrasound beam was kept perpendicular to the mid-basal segments of the IVS and PW when the parasternal long axis of the LV was scanned.

For each subject, the optimal ECG-guided end-diastolic and end-systolic 2-dimensional echocardiographic images of 3 consecutive beats in the cine loop were transferred directly from the screen to the digital archive of the echocardiography system. This was done using an image format of 24-bit intensity range and resolution of  $800 \times 564$  pixels. End-diastole was defined as the point in the cardiac cycle marked by the start of the R wave on ECG. End-systole was defined as the time of minimal LV chamber size, marked by the peak of the T wave on ECG. The digitized images were transferred from the echocardiography unit to a personal computer for VMTA.

The same observer (O.T.) analyzed all cases. Using dedicated software (NIH-ImageJ-1.35s, National Institutes of Health, USA), the images were converted to a format of 8-bit intensity range and  $800 \times 564$  resolution, with each pixel featuring 256 gray levels (0 = black, 255 = white). The same software allows the examiner to generate a histogram that depicts echocardiographic gray-level distribution across each image. A histogram was generated for each ROI by plotting gray-level distribution on the abscissa and frequency on the ordinate (Fig. 2). For images captured in the parasternal long axis view, a trackball-controlled cursor was used to outline and highlight the ROI on each image (all ROIs identical in each set of images). Effort was made to position each ROI at the same location on the IVS and on the PW in each case (i.e., near the tips of the mitral valve leaflets in end-systolic and end-diastolic frames) [11-13]. Only normal myocardial segments were analyzed (i.e., segments without the abnormal trabeculae that characterize noncompaction), and endocardial and epicardial specular echoes were excluded to avoid areas of “echo drop-out” and obvious artifacts. For each ROI in each wall region (IVS and PW), the background signal was subtracted from the mean gray level (MGL) to obtain background-corrected MGL (BC-MGL). The CV index of the gray-level amplitude for each ROI was calculated according to the formula, CV Index (%) =  $([BC-MGL_{end-diastole} - BC-MGL_{end-systole}] \div BC-MGL_{end-diastole}) \times 100$ . To assess the variability of these measures, 3 consecutive cycles were analyzed.



**Fig. 2.** Digitized images from a healthy subject show the position of the region of interest on the posterior wall of the left ventricle in end-diastole (Panel A) and end-systole (Panel B) (cycle phases determined from electrocardiography). A histogram was generated (the gray-level distribution on abscissa, frequency on the ordinate) for each region of interest at end-diastole (Panel C) and end-systole (Panel D). Local ethics committee approved the study and informed consent was obtained from participant(s)

## Statistical Analysis

Descriptive data for the continuous variables are presented as mean  $\pm$  1 standard deviation. The Mann-Whitney U test, Wilcoxon rank-sum test, and chi-square test were used as appropriate. Spearman’s correlation coefficient was used for correlation analysis. A p value  $< 0.05$  was considered statistically significant.

## Results

### Clinical and Echocardiographic Findings

Table 1 summarizes the results for the clinical and transthoracic echocardiography variables in the 3 groups (asymptomatic IVNC, symptomatic IVNC, healthy controls). There were no significant differences among the groups with respect to mean age, sex distribution, mean blood pressure or mean heart rate findings. The symptomatic IVNC group had significantly larger mean LAD, LVEDD and LVESD than the asymptomatic IVNC and control groups, and registered significantly lower mean FS and mean EF than the asymptomatic IVNC and control groups.

### Findings Related to Myocardial Texture

The VMTA results are shown in Table 2. There were no significant differences among the 3 groups with respect to mean diastolic BC-MGL for the IVS. The mean diastolic BC-MGL



for the PW in the symptomatic IVNC group was significantly higher than the corresponding value in the control group ( $p < 0.01$ ), but was not significantly different from that in the asymptomatic IVNC group. The symptomatic IVNC group also had significantly higher mean systolic BC-MGL for the IVS and

mean systolic BC-MGL for the PW than the control group ( $p < 0.01$ , for IVS;  $p < 0.01$ , for PW). There were no significant differences between the asymptomatic IVNC group and the control group with respect to these means.

**Table 1.** Group Results for the Clinical and Transthoracic Echocardiography Variables

	Healthy Controls n = 12	Symptomatic IVNC Group n = 12	Asymptomatic IVNC Group n = 10
<b>Clinical Characteristics</b>			
Age (yrs)	39 ± 14	36 ± 12	39 ± 11
Sex (male/female)	6/6	6/6	5/5
NYHA Functional Class	NA	2.8 ± 0.5	NA
Heart Rate (bpm)	72 ± 10	74 ± 11	71 ± 12
Systolic BP (mmHg)	118 ± 14	116 ± 15	120 ± 11
Diastolic BP (mmHg)	79 ± 12	80 ± 5	78 ± 11
<b>Medication Use n (%)</b>			
ACE Inhibitor	NA	12 (100%)	NA
β-blocker	NA	6 (50%)	1(10%)
Digoxin	NA	7 (58%)	NA
Diuretic	NA	9 (75%)	NA
Anticoagulant	NA	1 (8%)	NA
<b>Echocardiographic Data</b>			
IVS (mm)	9.0 ± 0.9	9.0 ± 1.0	9.0 ± 1.1
PW (mm)	9.0 ± 0.8	9.0 ± 1.1	10.0 ± 1.0
LVEDD (mm)	47 ± 7	59 ± 8 *	49 ± 6
LVESD (mm)	30 ± 4	47 ± 3 *	31 ± 5
LAD (mm)	32 ± 4	43 ± 2 *	31 ± 3
FS (%)	36 ± 3	20 ± 3 *	36 ± 5
EF (%)	67 ± 8	37 ± 5 *	67 ± 4
NC/C Ratio	NA	3.1 ± 0.5	3.2 ± 0.7
No. of Segments showing Noncompaction	NA	6.1 ± 2.1	5.8 ± 3

IVNC, isolated left ventricular noncompaction; NYHA, New York Heart Association; NA, not applicable; ACE, angiotensin-converting enzyme; LVEDD, left ventricular end-diastolic diameter; LVESD, left ventricular end-systolic diameter; FS, left ventricular fractional shortening; EF, left ventricular ejection fraction; IVS, thickness of the left ventricular aspect of the interventricular septum during diastole; PW, thickness of the posterior wall of the left ventricle during diastole; NC/C, noncompaction to compaction. Values are expressed as mean ± standard deviation. \*  $p < 0.01$  vs. control group and asymptomatic IVNC group.

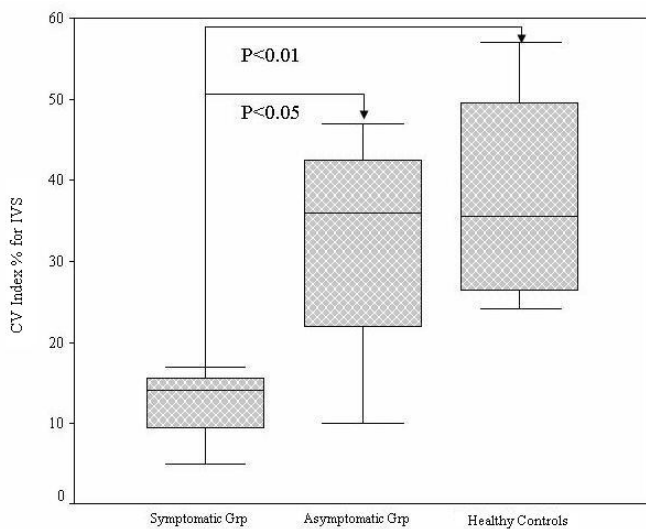
**Table 2.** Group Results for the Videodensitometric Myocardial Texture Analysis

	Healthy Controls	Symptomatic IVNC Group	Asymptomatic IVNC Group
<b>IVS</b>			
Diastolic BC-MGL	68.4 ± 21.2	61.6 ± 20.4	68.1 ± 28.2
Systolic BC-MGL	37.1 ± 12.1	53.8 ± 17.2*	39.3 ± 19.5
CV Index (%)	36.6 ± 12.1	12.3 ± 4.9†‡	32.3 ± 14.8
<b>PW</b>			
Diastolic BC-MGL	79.7 ± 22.1	113.1 ± 27.9*	92.3 ± 26.1
Systolic BC-MGL	56.3 ± 13.1	94.5 ± 24.2*	62.0 ± 18.8
CV Index (%)	28.8 ± 10.9	15.1 ± 5.5†‡	27.0 ± 10.4

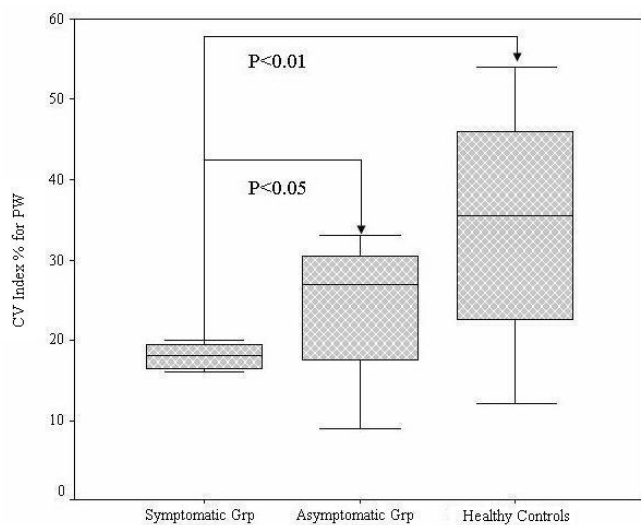
IVNC isolated left ventricular noncompaction; IVS left ventricular aspect of the interventricular septum; BC-MGL background-corrected mean gray level; CV Index (%) cyclic variation index; PW, posterior wall of the left ventricle. Values are expressed as mean ± standard deviation. \*  $p < 0.01$  vs. control group; †  $p < 0.001$  vs. control group; ‡  $p < 0.05$  vs. asymptomatic IVNC group.



The control group and asymptomatic IVNC group had statistically similar mean CV index values for the IVS and the PW, respectively. However, the mean CV index for the IVS in the symptomatic IVNC group was significantly lower than the corresponding values in the control group ( $p < 0.01$ ) and the asymptomatic IVNC group ( $p < 0.05$ ) (Fig. 3). The mean CV index for the PW in the symptomatic IVNC group was also significantly lower than the corresponding values in the other groups (controls  $p < 0.001$ ; asymptomatic IVNC group  $p < 0.05$ ) (Fig. 4).



**Fig. 3.** The mean cyclic variation index values for the region of interest in the left ventricular aspect of the interventricular septum in all 3 groups (symptomatic IVNC, asymptomatic IVNC, healthy controls). See the text for results of statistical comparison among the groups. CV Index %, cyclic variation index; IVS, left ventricular aspect of the interventricular septum; Grp, group.



**Fig. 4.** The mean cyclic variation index values for region of interest in the posterior wall of the left ventricle in all 3 groups (symptomatic IVNC, asymptomatic IVNC, healthy controls). See the text for results of

statistical comparison among the groups. CV Index %, cyclic variation index; PW, posterior wall of the left ventricle; Grp, group.

Separate analysis of the patient subgroup data (symptomatic IVNC, asymptomatic IVNC) revealed no significant correlations between the texture analysis parameters and any of the echocardiographic variables investigated (LVEDD, LVESD, LAD, FS, EF, IVS and PW thickness during diastole, NC/C ratio, number of segments with noncompaction).

### Discussion

Regions of myocardium with the typical signs of noncompaction can exhibit a variety of different histopathologic features. These include ischemic lesions, interstitial fibrosis, endomyocardial thickening, inflammatory reaction, subendocardial fibrosis, fibroelastosis, myocyte hypertrophy, myocardial fibrosis, myocardial disorganization, myocardial degeneration, and myocardial scarring [4-6, 15-16]. However, in most patients with IVNC, the basal segments of the LV do not exhibit the abnormal trabeculae that are typical of noncompaction. This portion of the ventricle appears normal on gross inspection, and it is not known whether such histopathology also exists in this region. The fact that the basal wall appears normal does not rule out underlying abnormality in these compacted regions.

Analyzing myocardial texture with echocardiography provides practical information about the condition of the heart muscle. This technique is a useful adjunct to conventional echocardiographic methods that are used to assess myocardium [10-12, 17]. Currently, there are 2 methods for assessing myocardial texture ultrasonographically: 1) integrated backscatter, which examines the acoustic intensity of the native echocardiographic signal, and 2) VMTA, which quantifies data from echocardiographic images and yields an MGL value for each ROI [14]. Integrated backscatter has been used both experimentally [18] and clinically [19] to quantify collagen and fibrosis in myocardium. As noted, VMTA has been used to investigate ischemic and non-ischemic myocardial disease, and to assess clinical prognosis in various cardiac disorders [11-12]. Research performed with the videodensitometry method has shown that, in patients with idiopathic dilated cardiomyopathy (DCMP) and ischemic myocardial disorders, the CV index values for the IVS and PW are lower than normal [12]. The same studies revealed that reduced CV index values are strongly correlated with poor prognosis. Our investigation with VMTA also revealed significantly lower CV index values for the IVS and the PW in patients with symptomatic IVNC (clinical LV dysfunction)



compared to patients with asymptomatic IVNC and healthy controls (Fig. 3-4). The prognosis for symptomatic IVNC is known to be poor [6]. Therefore, our findings suggest that CV index values for the IVS and the PW in patients with IVNC are independent indicators of prognosis.

Previous studies have shown that VMTA can identify changes in the myocardium before conventional echocardiography demonstrates any abnormality [19]. Videodensitometry can also confirm echocardiographic markers of myocardial pathology that are detected with conventional methods (for example, abnormal LV mass index, LV volume, LVEDD, LVESD and others) [19]. Excess parathyroid hormone is thought to be a major uremic toxin for myocardium that promotes activation of myocardial fibroblasts and causes cardiac fibrosis. Rossi et al. [20] also observed a relationship between altered myocardium as noted on videodensitometry and elevated serum aldosterone in patients with primary hyperaldosteronism. In this disorder, the excess aldosterone leads to cardiac fibrosis and subsequent cardiac dysfunction. However, neither of these studies documented any correlations between CV index values for the IVS or the PW and myocardial performance parameters on conventional echocardiography. Analysis of the data from our patients with IVNC showed that none of the VMTA parameters was significantly correlated with conventional echocardiography parameters of LV myocardial function (FS and EF) or echocardiography findings related to noncompaction (NC/C ratio, number of segments exhibiting noncompaction). Our results suggest that, in the setting of IVNC, videodensitometry findings can identify changes in the myocardium before conventional echocardiography demonstrates any abnormality.

VMTA is a reliable, noninvasive way to evaluate myocardial ischemia. Marini et al. [11] used this technique to investigate 34 patients who exhibited resting dyssynergia in the IVS and/or the inferior portion of the PW. Viable regions of the myocardium were identified as those that exhibited improved wall motion after revascularization. The authors observed that, prior to revascularization, videodensitometry revealed higher CV index values in these viable areas than in necrotic regions. In our study, the mean CV index values for the IVS and the PW in the symptomatic IVNC group were both significantly lower than the corresponding values in healthy individuals (the controls). However, we also observed a trend towards decreased CV index values for these sites in the asymptomatic IVNC group, patients who may be in a transitional phase that will progress to grave LV deterioration (Table 2). The

findings in both our IVNC subgroups support the theory that microcirculatory ischemic dysfunction plays a role in IVNC.

Although IVNC is a distinct form of congenital cardiomyopathy, patients who exhibit LV dysfunction due to IVNC can be misdiagnosed as having DCMP. As noted, there are a number of imaging features of the LV myocardium that typify IVNC: prominent trabeculae, deep intertrabecular recesses, compacted/noncompact layers, and recesses filled with blood from the LV cavity. In the normal heart, the base is the thickest region of the LV wall; the muscle tissue becomes remarkably thin towards the apex, and the apical portion of the wall features only small trabeculae [14]. In contrast, in the setting of IVNC the apex is thicker and has larger trabeculae, and only a few patients with this condition have trabeculae at the base of the LV [2-7]. During the course of DCMP, the LV becomes dilated as the walls become progressively thinner, and the ventricle takes on a spherical shape. In cases of IVNC, LV wall thickness does not change and the chamber does not dilate in proportion to the degree of spherical remodeling that occurs [9]. This is unlike all other cardiac conditions that feature marked systolic LV dysfunction [9]. To the best of our knowledge, the present study is the first to have applied VMTA in patients with IVNC. We found that some of the findings were similar to those reported for DCMP. Dagdeviren et al. [23] identified a relationship between contractile reserve during dobutamine stress and CV index values for the IVS and PW in DCMP. A different report by Dagdeviren et al. [12] confirmed that lower CV index values for these wall regions predict prognosis in the setting of DCMP. The CV index values for our patients with low LV EF (the symptomatic IVNC group) were similar to those that have been documented for patients with DCMP. In contrast, the mean CV index values for the asymptomatic IVNC group were considerably higher.

Although IVNC is still considered a rare cardiac disorder, it has been detected more frequently in recent years owing to improvements in cardiac imaging. Aras et al. [24] showed that age at initial presentation, ratio of NC/C, and number of affected segments seem to be major determinants of LV systolic dysfunction. As noted, IVNC is not always fatal; some patients exhibit an "undulating phenotype" with recovery of LV function for periods of time before further deterioration occurs [7]. The mechanism of distinct undulating LV dysfunction that occurs in IVNC, the cause of the LV deterioration, and the prognosis for this disorder are still in question. Pignatelli et al. [7] reported that patients with IVNC exhibit serial alterations in LV function; there

may be varying periods of recovery of systolic ventricular function before further deterioration. In line with this, a previous report by our group documented the case of a 78-year-old patient with asymptomatic IVNC who showed preserved systolic LV function [8]. Due to the nature of the disorder, patients with IVNC require continuous monitoring of LV function. For this purpose, VMTA might be a useful adjunct to conventional echocardiography in the early stages of the disease[25].

### Study Limitations

Very few patients who are referred to our echocardiography laboratory have IVNC, and this restricted the number of patients in our study. For ethical reasons, we did not obtain cardiac biopsies from our subjects with IVNC. We interpreted the videodensitometry data based on findings in previous, well-designed investigations of other patient groups. Configurational changes due to translation, rotation and twisting of the heart during the cardiac cycle can lead to misinterpretation of videodensitometry data. We tried to minimize such problems in multiple ways. As previous investigators have done, we positioned the 2 ROIs for our study at mid-basal locations on the IVS and PW, respectively. These segments were distant from regions of abnormal trabeculation (noncompacted areas), thus we avoided the echo drop-out that would have occurred in regions of noncompaction. In addition, the orientation of the ultrasound beam was such that it was almost perpendicular to the myocardial fibers in the IVS and the PW. This meant that problems with anisotropy were also avoided as much as possible. Another limitation we recognized is that we have not used two dimensional (2D) speckle tracking echocardiography (STE) which is a promising new imaging modality, similar to tissue Doppler imaging (TDI), it permits offline calculation of myocardial velocities and deformation parameters such as strain and strain rate (SR) and it has an important role in the diagnosis and follow-up in IVNC [50]. Finally, all of our subjects were adults, and results for this population cannot be extrapolated to IVNC in childhood.

### Conclusion

In conclusion, VMTA is a practical, noninvasive way to assess LV myocardium in the setting of IVNC. This technique adds important information to that obtained with conventional echocardiography. VMTA may be useful for monitoring LV status and LV deterioration in patients with IVNC.

### Declaration of conflict of interest

The authors received no financial support for the research and/or authorship of this article. There is no conflict of interest.

### References

1. Richardson P, McKenna W, Bristow M et al. Report of the 1995 World Health Organization/International Society and Federation of Cardiology Task Force on the definition and classification of cardiomyopathies. *Circulation* 1996; 93: 841–42.
2. Sedmera D, Pexieder T, Vuillemin M, Thompson RP, Anderson RH. Developmental patterning of the myocardium. *Anat Rec* 2000; 258: 319-37.
3. Jenni R, Goebel N, Tartini R, Schneider J, Arbenz U, Oelz O. Persisting myocardial sinusoids of both ventricles as an isolated anomaly: echocardiographic, angiographic, and pathologic anatomical findings. *Cardiovasc Intervent Radiol* 1986; 9: 127-31.
4. Chin TK, Perloff JK, Williams RG, Jue K, Mohrmann R. Isolated noncompaction of left ventricular myocardium: a study of eight cases. *Circulation* 1990; 82: 507-13.
5. Oechslin EN, Attenhofer Jost CH, Rojas JR, Kaufmann PA, Jenni R. Long-term follow-up of 34 adults with isolated left ventricular noncompaction: a distinct cardiomyopathy with poor prognosis. *J Am Coll Cardiol* 2000; 36: 493-500.
6. Jenni R, Oechslin E, Schneider J, Attenhofer Jost C, Kaufmann PA. Attenhofer Jost C, Kaufmann PA. Echocardiographic and pathoanatomical characteristics of isolated left ventricular non-compaction: a step towards classification as a distinct cardiomyopathy. *Heart* 2001; 86: 666-71.
7. Pignatelli RH, McMahon CJ, Dreyer WJ et al. Clinical characterization of left ventricular noncompaction in children: a relatively common form of cardiomyopathy. *Circulation*. 2003; 108: 2672-28.
8. Aras D, Tufekcioglu O, Topaloglu S et al. Preserved systolic function with isolated left ventricular noncompaction in an elderly patient. *Eur J Echocardiogr* 2006; 7: 71-74.
9. Sengupta PP, Mohan JC, Mehta V et al. Comparison of echocardiographic features of noncompaction of the left ventricle in adults versus idiopathic dilated cardiomyopathy in adults. *Am J Cardiol* 2004; 94: 389-91.
10. Picano E, Faletta F, Marini C et al. Increased echodensity of transiently asynergic myocardium in humans: a novel echocardiographic sign of myocardial ischemia. *J Am Coll Cardiol* 1993; 21: 199-207.
11. Marini C, Picano E, Varga A, Marzullo P, Pingitore A, Paterni M. Cyclic variation in myocardial gray level as a marker of viability in man. A videodensitometric study. *Eur Heart J* 1996; 17: 472-79.
12. Di Bello V, Pedrinelli R, Giorgi D et al. Ultrasonic videodensitometric analysis of two different models of left ventricular hypertrophy. Athlete's heart and hypertension. *Hypertension* 1997; 29: 937-44.





13. Di Bello V, Pedrinelli R, Giorgi D et al. Ultrasonic myocardial texture versus Doppler analysis in hypertensive heart: a preliminary study. *Hypertension* 1999; 33: 66-73.
14. Zoni A, Regolisti G, Aschieri D, Borghetti A. Myocardial ultrasonic tissue characterization in patients with different types of left ventricular hypertrophy: a videodensitometric approach. *J Am Soc Echocardiogr* 1997; 10: 74-82.
15. Dagdeviren B, Akdemir O, Eren M et al. Prognostic implication of myocardial texture analysis in idiopathic dilated cardiomyopathy. *Eur J Heart Fail* 2002; 4: 41-48.
16. Jenni R, Vieli A, Hess O, Anliker M, Krayenbuehl HP. Estimation of left ventricular volume from apical orthogonal 2-D echocardiograms. *Eur Heart J* 1981; 2: 217 - 25.
17. Lasserre R, Gosse P, Mansour S. Myocardial Tissue Characterization in Echocardiography with Videodensitometry: Evaluation of a New Semi-automatic Software Applied on a Population of Hypertensive Patients. *Eur J Echocardiogr* 2003; 4: 292-99.
18. Stamou SC, Lefrak EA, Athari FC, Burton NA, Massimiano PS. Heart transplantation in a patient with isolated noncompaction of the left ventricular myocardium. *Ann Thorac Surg* 2004; 77: 1806-8.
19. Burke A, Mont E, Kutys R, Virmani R. Left ventricular noncompaction: a pathological study of 14 cases. *Hum Pathol* 2005; 36: 403-11.
20. Skorton DJ, Melton HE Jr, Pandian NG et al. Detection of acute myocardial infarction in closed-chest dogs by analysis of regional two-dimensional echocardiographic gray-level distributions. *Circ Res* 1983; 52: 36-44.
21. Hoyt RM, Skorton DJ, Collins SM, Melton HE Jr. Ultrasonic backscatter and collagen in normal ventricular myocardium. *Circulation* 1984; 69: 775-82.
22. Bello VD, Giorgi D, Viacava P et al. Severe aortic stenosis and myocardial function diagnostic and prognostic usefulness of ultrasonic integrated backscatter analysis. *Circulation* 2004; 110: 849-55.
23. Rossi Gp, Di Bello V, Ganzaroli C et al. Excess aldosterone is associated with alterations of myocardial texture in primary aldosteronism. *Hypertension* 2002; 40: 23-27.
24. Williams RI, Masani ND, Buchalter MB, Fraser AG. Abnormal myocardial strain rate in noncompaction of the left ventricle. *J Am Soc Echocardiogr* 2003; 16: 293-96.
25. Greenbaum RA, Ho SY, Gibson DG, Becker AE, Anderson RH. Left ventricular fibre architecture in man. *Br Heart J* 1981; 45: 248-63.
26. Dagdeviren B, Akdemir O, Bolca O, Eren M, Gürlertop Y, Tezel T. Myocardial texture analysis in idiopathic dilated cardiomyopathy: prediction of contractile reserve on dobutamine echocardiography. *J Am Soc Echocardiogr* 2002; 15: 36-42.
27. Aras D, Tufekcioglu O, Ergun K et al. Clinical features of isolated ventricular noncompaction in adults long-term clinical course, echocardiographic properties, and predictors of left ventricular failure *J Card Fail* 2006; 12: 726-33.
28. Bennett CE, Freudenberger R. The Current Approach to Diagnosis and Management of Left Ventricular Noncompaction Cardiomyopathy: Review of the Literature. *Cardiol Res Pract* 2016; 2016: 5172308