

A CASE OF TRYPANOSOMOSIS IN A PIGEON IN ISTANBUL, TURKEY

Aynur GÜLANBER*

Erkut TÜZER*

İlker EFİL*

İstanbul'da bir güvercinde Trypanosomosis olgusu

Özet: 1998 Kasım ayında İstanbul'da Güneşli semtinde bakılan bir evcil güvercinde (*Columba livia*) yapılan bir kan frotisinde bir Trypanosoma türüne ait bir trypanomastigote görülmüştür. Parazit yaklaşık 55 µm uzunluğa ve iyi gelişmiş bir dalgalı zara sahipti. Çekirdeği kenara yakın olarak, kinetoplastı arka uçtan uzakta yer almıştı. Bu, Türkiye'de güvercinlerde ilk trypanosomosis (muhtemelen *T. hannah*'den ileri gelen) olgusudur

Anahtar Kelimeler: Güvercin, *Columba livia*, *Trypanosoma hannah*, İstanbul, Türkiye

Summary: A trypanosome was seen on a blood film of a domestic pigeon (*Columba livia*) reared in Güneşli district of İstanbul in November, 1998. It was a single trypanomastigote which is 55 µm long and had a well developed undulating membrane. The nucleus was placed marginally and the kinetoplast was away from the posterior end. This is the first case report on trypanosomosis (probably due to *T. hannah*) in a pigeon from Turkey.

Key Words: Pigeon, *Columba livia*, *Trypanosoma hannah*, İstanbul, Turkey

Introduction

A lot of names of trypanosomes from many species of birds have been recorded. They all look more or less alike. Trypanosomes in birds are pleomorphic. Their length may be 26-69 µm or more and have a free flagellum. Their kinetoplasts generally lie away from the posterior end. The parasites multiply little in the avian host. During winter they are mostly present in bone marrow and return back to peripheral blood during spring. Mosquitoes, simuliids and hippoboscids are their vectors. Avian trypanosomes are assumed to be nonpathogenic. *Trypanosoma avium* Danilewsky, 1885, was first described from owls and roller-birds (*Coracias garrulus*) and has since been recorded from a wide variety of birds. *Trypanosoma hannah* Pittaluga, 1905, was described from pigeons (3).

* University of İstanbul, Veterinary Faculty, Department of Parasitology, Avcılar, İstanbul 34851, Turkey

Studies performed on pigeon trypanosomes during past 25 years are rare (1, 2, 4, 6-8). *Trypanosoma hannai* was found in *Columba livia* (wild rock pigeon and domestic pigeon) in India (4, 7), in *Columba palumbus* (a species of pigeon), *Streptopelia turtur*, *S. orientalis* (species of doves) in Kazakhstan (8) and *Trypanosoma avium* in the samples of *Columba fasciata* (band-tailed pigeon) in Colorado, California (USA) and Mexico (6). *Pseudolynchia canariensis* is the vector of *T. hannai* (2, 4). In an experimental study (1), the developmental forms of *Trypanosoma avium backeri* were observed in the gut of *Aedes albipictus*, and pigeons were infected with the metacyclic trypomastigote from the hindguts of mosquitoes.

No record on the occurrence of trypanosomes in pigeons in Turkey was encountered.

C a s e

Some blood films were taken from a domestic pigeon (*Columba livia*), which was reared in Güneşli district of İstanbul, in November 1998. The films were fixed in methanol for 2 minutes and were stained with Giemsa stain for 25-30 minutes. Only one trypomastigote of a *Trypanosoma* sp was seen. It was about 55 µm long and had a well developed undulating membrane. The nucleus lied marginally and the kinetoplast was situated away from the posterior end (Fig. 1).

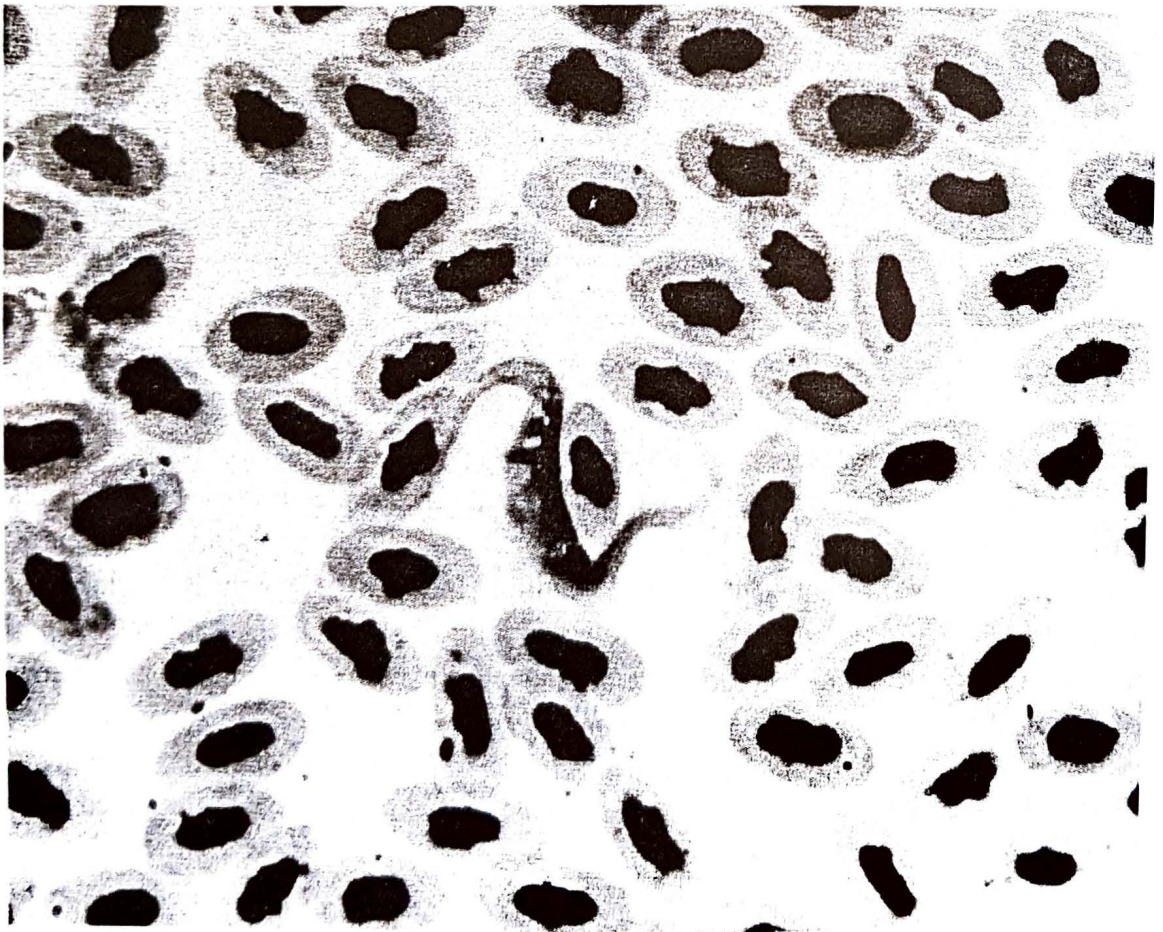


Figure 1. *Trypanosoma* sp in the blood film of pigeon

Discussion

There was no record on the presence of any species of *Trypanosoma* in pigeons in Turkey. This is the first report on the presence of *Trypanosoma sp* in pigeon from Turkey. Since avian trypanosomes are pleomorphic (3) and only one trypomastigote was seen in this case, its exact identification couldn't be done. It is suggested that the parasite may be *Trypanosoma hannai*, which is seen in *Columba livia* (Wild rock pigeon and domestic pigeon) (3, 4, 7).

Kaynaklar

1. Chetterjee, D.K. (1977): Development of *Trypanosoma avium backeri* Chatterjee and Ray, 1971 in *Aedes albopictus* and its subsequent transmission to birds. *Indian J. Parasitol.*, 1 (2): 97-100.
2. Fahmy, M.A.M., Mandour, A.M., Arafa, M.S., Makhloof, L.M. (1977): Bionomics and natural infection of *Pseudolynchia canariensis* with *Haemoproteus* and *Trypanosoma* in Assiut area, Upper Egypt. *J. Egypt. Soc. Parasitol.*, 7 (1): 19-24.
3. Levine, N.D. (1985): *Veterinary Protozoology*. Iowa State Univ. Press, Ames, USA.
4. Mandal, F.B. (1991): Natural infestation of *Trypanosoma hanna* Pittaluga (Kinetoplastida: Trypanosomatidae)., *Environ. Ecol.*, 9 (1): 294-295.
5. Springer, W.T. (1984): Other Blood and Tissue Protozoa (In: Hofstad, M.S., Barnes, H.J., Calnek, B.W., Reid, W.M., Yoder, H.W. Jr.; *Diseases of poultry* (8th. Ed.). Iowa State Univ. Press., Ames, Iowa, USA. pp. 727-740.
6. Stabler, R.M., Kitzmiller, N.J., Braun, C.E. (1977): Blood parasites from band-tailed pigeons. *J. Wildl. Manage.*, 41 (1): 128-130.
7. Subbiah, T.V., Joseph, S.A. (1988): A note on the occurrence of *Trypanosoma hanna* in the blood of the domestic pigeon, *Columba livia*. *Cheiron.*, 17 (3): 136.
8. Yakunin, M.P., Zhazyldaev, T.A. (1977): The blood parasites of wild and domestic birds in Kazakhstan. *Trudy Inst. Zool. Akad. Nauk. Kazak, SSR*, 37: 124-148. (Ref. Parasite CD 1973-1988).