



DOI: 10.33188/vetheder.518909

Araştırma Makalesi / Research Article

The applicability and efficiency of 3 dimensional printing models of hyoid bone in comparative veterinary anatomy education

Caner BAKICI^{1, a*}, Remzi Orkun AKGÜN^{1, b}, Çağdaş OTO^{1, c}

¹ Ankara Üniversitesi Veteriner Fakültesi Anatomi Anabilim Dalı, 06110, Ankara, Türkiye
ORCID: 0000-0003-2413-3142^a; 0000-0001-6648-7059^b; 0000-0002-2727-3768^c

MAKALE BİLGİSİ /

ARTICLE INFORMATION:

Geliş / Received:

28 Ocak 19

28 January 19

Kabul / Accepted:

24 Şubat 19

24 February 19

Anahtar Sözcükler:

3B baskı

Anatomi

Çok kesitli bilgisayarlı

tomografi

Dil kemiği

Eğitim

Keywords:

3D printing

Anatomy

Education

Hyoid bone

Multidetector computed

tomography

ABSTRACT:

Additive manufacturing, also known as three-dimensional (3D) printing, is bringing the technological breakthrough in many areas, such as engineering, art, education, and medicine. Two separate themes are described in this study. The first theme is to present a graphical 3D modeling approach of different hyoid bones. The second theme involves making 3D printing models of these bony structures and compared with original forms. Different hyoid bones (horse, cattle, dog, cat, and pig) were used to produce 3D printing models. Hyoid bones were scanned with the multidetector computed tomography (MD CT). Two-dimensional (2D) images were stored in Digital Imaging and Communications in Medicine (DICOM) and segmentation and post-processing of these images were performed. 3D reconstructed images of the hyoid bones were acquired with 3D Slicer software. 3D models of the hyoid bones were recorded in stereolithography (STL) file format on the computer. These STL images were then used to produce physical 3D printing models with the Fused Deposition Modelling (FDM) printer and polylactic acid (PLA) filament. It was known that hyoid bones are very thin and fragile. For this reason, 3D printed models could be used for these characteristic bones. These 3D models were seen useful for anatomy education and hard to break compared to original bones. It was seen that it could be rapidly produced by 3D printing technology for anatomy education in practical lessons. This study shows that durable, real-like bone specimens could be produced with minimal equipment and manpower. It was observed that both produced 3D models and 3D reconstructed images can be used during veterinary anatomy education.

3 boyutlu baskı dil kemik modellerinin karşılaştırmalı veteriner anatomi eğitiminde uygulanabilirliği ve verimliliği

ÖZET:

Üç boyutlu (3B) baskı olarak da bilinen eklemeli üretim; mühendislik, sanat, eğitim ve tıp gibi birçok alanda teknolojik atılım getirmektedir. Bu çalışmada iki ayrı tema tanımlanmıştır. İlki, farklı dil kemiklerinin grafiksel bir 3B modelleme yaklaşımını sunmak, ikincisi ise bu kemik yapıların 3B baskı modellerini oluşturup orijinal formları ile karşılaştırmayı içerir. 3B baskı modellerini üretmek için farklı dil kemikleri (at, sığır, köpek, kedi ve domuz) kullanıldı. Dil kemikleri, multidetektörlü bilgisayarlı tomografi (MD BT) ile tarandı. İki Boyutlu (2B) görüntüler Tıpta Dijital Görüntüleme ve İletişim formatında (DICOM) saklandı ve bu görüntülerin bölümlendirilmesi ve düzeltilmesi yapıldı. Dil kemiklerinin 3B rekonstrüksiyon görüntüleri 3D Slicer yazılımıyla elde edildi. Dil kemiklerinin 3B modelleri bilgisayardaki stereolitografi (STL) dosya formatında kaydedildi. Bu STL görüntüleri daha sonra Katmanlı Üretim Teknolojisi (FDM) yazıcısı ve polilaktik asit (PLA) filamentini ile fiziksel 3B baskı modelleri üretmek için kullanıldı. Dil kemiklerin çok ince ve kırılabilir olduğu bilinmektedir. Bu nedenle, bu karakteristik kemiklerde 3B baskılı modellemenin kullanılabilirliği belirlendi. Bu 3B modellerin anatomi eğitimi için faydalı olduğu ve orijinal kemiklere kıyasla kırılmasının daha zor olduğu görüldü. Bu kemiklerin, veteriner anatomi eğitiminin uygulama dersleri için 3B baskı teknolojisi ile hızla üretilebileceği görülmüştür. Bu çalışma; dayanıklı, gerçek benzeri kemik örneklerinin minimum ekipman ve insan gücü ile üretilebileceğini göstermektedir. Üretilen 3B modeller ve 3B rekonstrüksiyon görüntüleri veteriner anatomi eğitimi sırasında kullanılabileceği gözlenmiştir.

How to cite this article: Bakıcı C, Akgün RO, Oto Ç: The applicability and efficiency of 3 dimensional printing models of hyoid bone in comparative veterinary anatomy education. *Vet Hekim Der Derg*, 90 (2): 71-75, 2019. DOI: 10.33188/vetheder.518909

* Sorumlu yazar / Corresponding author

posta adresi/e-mail address: vetcaneerbakici@gmail.com

1. Introduction

Veterinary anatomy education is considered among the most basic stones of veterinary medicine (7). During this education curricula, students experience many educational materials. These training materials vary widely. This variety has increased as a result of the impact of developing technology on education programs. There are some other reasons for this variety (1, 3). One of them is the negative effect of chemical substances used in the preparation of dissection or prosection specimens which are accepted as the gold standard (11). Dissection and prosection are time-consuming and costly processes because these specimens must be prepared before come forward to the students and lecturers must have some equipment like as chemical solutions, cadaver containers, dissection tables, and air-conditions. The adverse effect of formaldehyde on all living (students, lecturer, environment etc.) was defined in Health Safety Authority and the dose limitation that could be used was considerably reduced (3, 4, 7). The other is the lack of educational materials in laboratory courses due to the high number of students (1, 2). The need for a high number of donors for preparing specimens raises another problem. This problem is an ethic which is another main difficulty that leads to insufficient specimens in anatomy education. These problems have been led educators to seek different educational materials (2, 5, 12).

Additive manufacturing, also known as three-dimensional (3D) printing, is bringing the technological breakthrough in many areas, such as engineering, art, education, and medicine. This technology is formed by the production of the desired three-dimensional tissue layer by layer (5, 6). The application of this technology to anatomy is provided benefits in different aspects. The most important features in bone models produced by 3D printing for anatomy education are that the bones contain anatomical structures and preserve the real form of the original structures (3, 8, 13). On the other hand, these patient-specific models lead to perform preoperative surgical simulations, understand interactions between the organs, and view from a different angle for education purposes (6, 11).

Two separate themes are described in this study. The first theme is to present a graphical 3D modeling approach of different animal hyoid bones. The second theme involves making 3D printing models of these bony structures and compared with original forms.

2. Material and Methods

Different specimens (horse, cattle, dog, cat, and pig) from the collection of Faculty of Veterinary Medicine Department of Anatomy at Ankara University were used to produce 3D printing models. Hyoid bones were scanned with 256-multidetector computed tomography (Siemens Somatom Definition Flash). Slice thickness was 0,75 mm from proximal to distal direction. The scanning parameters were recorded as follows; 120 kV, 600 mAs, window level 200 Hounsfield unit (HU), and window width 50 HU. Two-dimensional (2D) images were stored in Digital Imaging and Communications in Medicine (DICOM) and then segmentation and post-processing processes of these images were performed. 3D reconstructed images of the hyoid bones were acquired with 3D slicer software (3D Slicer, GitHub, San Francisco). Bony structures were segmented using HU thresholds. Each threshold was different because hyoid bone densities were varied from animal to animal. 3D models of the hyoid bones were recorded in stereolithography or standard triangulate language (STL) file format on the computer (Figure 1). After 3D digital models were arranged, the post-segmentation process was performed on these models with MeshMixer software (Autodesk Inc., San Francisco, version 3.5) to produce the final 3D printing model. The final STL images were used to produce physical 3D printing models with the Fused Deposition Modelling (FDM) printer (Anycubic I3 Mega, Shenzhen technology, China) and polylactic acid (PLA) filament (Figure 2). The FDM printer created the 3D model layer by layer.

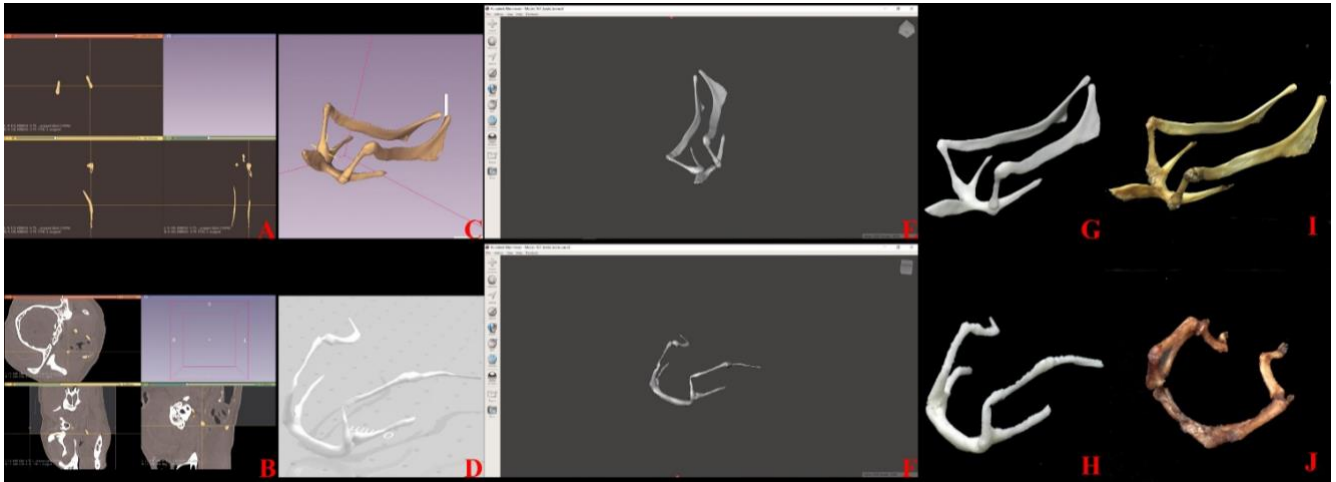


Figure 1: Production stages of 3D printing models of a horse (A-C-E-G) and a dog (B-D-F-H) hyoid bones. Original bone samples (I-J). (A-B) Segmentation process of MD CT images with 3D Slicer software, (C-D) 3D reconstruction images, (E-F) Post-segmentation process with MeshMixer software, (G-H) 3D printing models

Şekil 1: At (A-C-E-G) ve köpek (B-D-F-H) dil kemiklerinin 3B baskı modellerinin yapım aşamaları. Orijinal kemik örnekleri (I-J). (A-B) 3D Slicer program ile MD BT görüntülerinin segmentasyon işlemi, (C-D) Üç boyutlu rekonstrüksiyon görüntüleri, (E-F) MeshMixer program ile segmentasyon sonrası düzenleme işlemi, (G-H) Üç boyutlu baskı modeller.

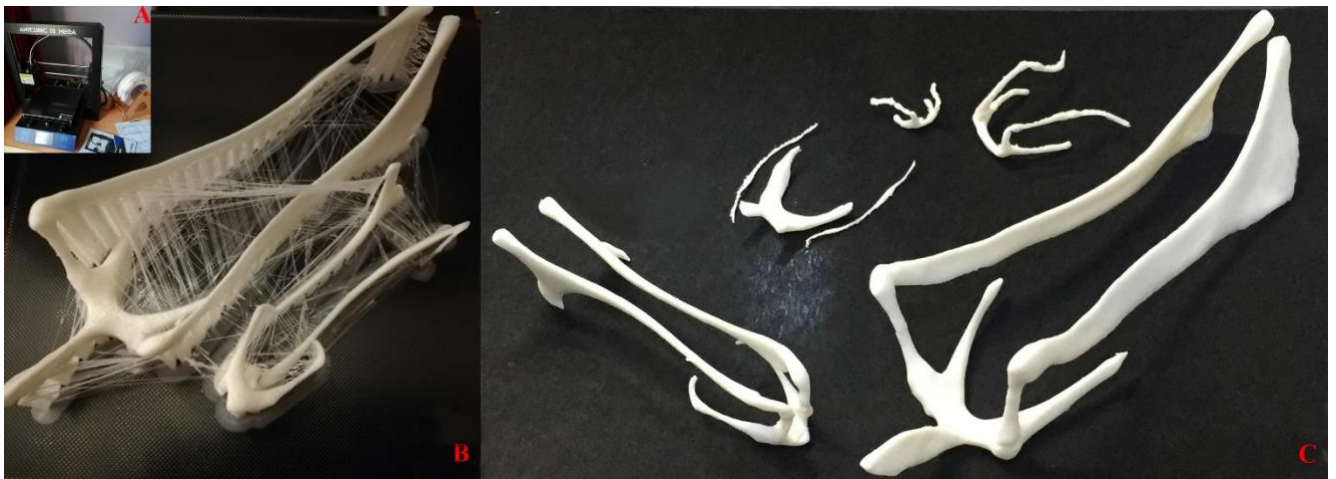

Figure 2: Anycubic I3 Mega 3D printer (A), the printing stage of 3D printing models (B), and 3D printing models of hyoid bones of different species (C).

Şekil 2: Anycubic I3 Mega 3B yazıcı (A), 3B baskı modellerinin basım aşaması (B), ve Farklı türlere ait dil kemiklerinin 3B baskı modelleri (C).

3. Results

This study described the 3D printing stages from the original bone specimen to the final 3D printing bone model. The Anycubic I3 Mega 3D printer was able to create hyoid bones of different type of animals (Figure 2).

3D Slicer, the free open source software, was displayed MD CT images in different planes. MeshMixer, another free open source software, was used to smoothen the surfaces of 3D images in STL format for a better quality of 3D printing models. The use of these two softwares were found to be quite easy.

Original hyoid bones are very thin and fragile. These 3D printing models were more durable than original hyoid bones. However, attention should also be paid because of its thin structures.

The 3D printing models were seen to be the same size as the original forms. But it was determined that the size can be changed if desired. MD CT was revealed all parts of the hyoid bone and 3D printing models of hyoid bones were created by FDM printer (Figure 1).

Structures which were not well resolved (such as articular parts of the hyoid bones) in 3D imaging techniques, were absent in 3D printing models. However, it was clear that these models could be rapidly produced by 3D printing technology for practical lessons in anatomy education because these fragile and readily unfindable materials were insufficient numbers for practical lessons (Table 1).

Table 1: Evaluation of 3D reconstruction and 3D printing images of anatomical structures of the hyoid bone. -, the feature was absent from physical specimen; +, the feature was present; ?, the feature is not well resolved.

Tablo 1: Dil kemiğine ait anatomik yapıların 3B rekonstrüksiyon ve 3B baskı görüntülerinin değerlendirilmesi

Anatomical Feature	Scan	Print
Basihyoid	+	+
Ceratohyoid	+	+
Epihyoid	+	+
Stylohyoid	+	+
Thyrohyoid	+	+
Tympanohyoid	+	+
Lingual process	+	+
Articular parts	?	-

4. Discussion and Conclusion

There were numerous studies pointed out that 3D printing models could be used for preoperative visualization, preoperative planning, demonstration the operations or education (2, 5, 7, 8). It was pointed out that some bones are quite fragile so that students face constraints such as limited handling and examination in anatomy classes (1). This study shows that durable, real-like bone specimens could be produced with minimal equipment and manpower. The 3D printing models can be used for practical lessons of veterinary anatomy and 3D reconstruction images can be used during theoretical lectures of veterinary anatomy.

In previous studies, it has been pointed out that complex anatomical structures should be investigated to test the accuracy of 3D printed bone models. Because the lack of narrow holes or some complex anatomical structures have been reported (7, 12). It was also emphasized that CT was the best imaging technique for bony structures (9). In this study, it was determined that the bone structures were well resolved in 3D images and hyoid bone models were created good quality by 3D printing. MD CT was a good choice for imaging bone tissue. Only articular parts of hyoid bones were not differentiated from bony structures because of the imaging system quality. It was also stated that it is practicable to different operative approaches or training models by re-using or modifying recorded data (10).

In this study, the scanning time of hyoid bones was approximately 2 minutes each. The processing of 3D reconstruction models took 10 minutes on the computer. The post-processing of 3D images of hyoid bones took a short time like 3 minutes. The 3D printing time took 10 - 30 minutes for small models and 2 - 3.5 hours for big models. The cost of 3D printing hyoid bones varies between 0.1 euro to 1 euro. The scanning and processing time were almost 15 minutes for one specimen. One of the previous studies, scanning time of the frog skeleton and the dogfish chondrocranium were between 1 and 2 hours, processing step was approximately 1 hour and the cost of the 3D printing

models was 13 to 10 pound (12). On the other study, the temporal bone model was produced at 3.5 hours on the purposes of dissection (8). Another researcher produced the temporal bone model with ABS thermoplastic material at 24 hours approximately. The segmentation, printing, and detergent wash time took 3-5 hours, 6 hours, and 8-12 hours, respectively (2). It was seen that the 3D printing hyoid bone models were easily replicated, and their costs were relatively lower than other education materials like cadavers or plastination specimens.

It was stated that the 3D printing models were cost efficient osteological education materials (1, 2, 7). It should be noted that the imaging process workload will be performed once, and the printer will also be taken once. Therefore, the use of the imaging technique and the acquisition of digital 3D images will be done only once. When imaging and 3D printer costs were deducted, it was seen that the production of the specimens is quite cheap.

3D printing models will be a preferable education material compared to dissection and prosection because it also protects human health. One of the important advantages was that it made the deformed or more sensitive bone samples more durable. Due to all the advantages mentioned, it is thought that the models produced by 3D printing will be a preferable training material by anatomy lecturers in the near future.

References

1. **AbouHashem Y, Dayal M, Savanah S, Strkalj G** (2015): *The application of 3D printing in anatomy education*. Med Educ Online, 20, 29847.
2. **Cohen J, Reyes SA** (2015): *Creation of a 3D printed temporal bone model from clinical CT data*. Am J Otolaryngol, **36(5)**, 619-624.
3. **Estai M, Bunt S** (2016): *Best teaching practices in anatomy education: A critical review*. Ann Anat, **208**, 151-157.
4. **HAS** (2018): *Health and safety authority 2018: Code of practice for the chemical agents regulations*. Dublin, Ireland.
5. **Hochman JB, Rhodes C, Wong D, Kraut J, Pisa J, Unger B** (2015): *Comparison of cadaveric and isomorphic three-dimensional printed models in temporal bone education*. Laryngoscope, **125(10)**, 2353-2357.
6. **Javaid M, Haleem A** (2018): *Additive manufacturing applications in orthopaedics: A review*. J Clin Orthop Trauma, **9(3)**, 202–206.
7. **Li F, Liu C, Song X, Huan Y, Gao S, Jiang Z** (2018): *Production of accurate skeletal models of domestic animals using three-dimensional scanning and printing technology*. Anat Sci Educ, **11(1)**, 73-80.
8. **Mowry SE, Jammal H, Myer C, Solares CA, Weinberger P** (2015): *A novel temporal bone simulation model using 3d printing techniques*. Otol Neurotol, **36(9)**, 1562–1565.
9. **Radetzki F, Mendel T, Noser H, Stoevesandt D, Röllinghoff M, Gutteck N, Delank KS, Wohlrab D** (2013): *Potentialities and limitations of a database constructing three-dimensional virtual bone models*. Surg Radiol Anat, **35(10)**, 963-968.
10. **Shepherd S, Macluskey M, Napier A, Jackson R** (2017): *Oral surgery simulated teaching; 3D model printing*. Oral Surg, 10(2), 80-85.
11. **Smith ML, Jones JFX** (2018): *Dual-extrusion 3D printing of anatomical models for education*. Anat Sci Educ, **11(1)**, 65-72.
12. **Thomas DB, Hisrox JD, Dixon BJ, Potgieter J** (2016): *3D scanning and printing skeletal tissues for anatomy education*. J Anat, **229(3)**, 473-481.
13. **Vaccarezza M, Papa V** (2015): *3D printing: a valuable resource in human anatomy education*. Anat Sci Int, **90(1)**, 64–65.