

Carotid intima-media thickness and cardiac functions in children with neurofibromatosis type 1

Nörofibromatozis tip 1 tanılı çocuklarda karotis intima-media kalınlığı ve kalp fonksiyonları

Alev Arslan¹

¹Department of Pediatrics, Division of Pediatric Cardiology, Kayseri Education and Research Hospital, Kayseri, Turkey

ORCID ID of the author(s)

AA: 0000-0003-4444-0027

Corresponding author / Sorumlu yazar:

Alev Arslan

Address / Adres: Adana Başkent Üniversitesi Tıp Fakültesi, Pediatrik Kardiyoloji Anabilim Dalı, Dr. Turgut Noyan Eğitim ve Araştırma Merkezi, Adana, Türkiye
e-Mail: alevkiziltas@gmail.com

Ethics Committee Approval: This study (December 2013/ Grant No: 25) was performed in accordance with the ethical standards approved by the Committee for Scientific Research and Publication Ethics at Kayseri Education and Research Hospital (Kayseri, Turkey).

Etik Kurul Onayı: Bu çalışma (Aralık 2013 / No: 25) Kayseri Eğitim ve Araştırma Hastanesinde (Kayseri, Türkiye) Bilimsel Araştırma ve Yayın Etiği Komitesi tarafından onaylanan etik standartlara uygun olarak yapıldı.

Conflict of Interest: No conflict of interest was declared by the authors.

Çıkar Çatışması: Yazarlar çıkar çatışması bildirmemişlerdir.

Financial Disclosure: The authors declared that this study has received no financial support.
Finansal Destek: Yazarlar bu çalışma için finansal destek almadıklarını beyan etmişlerdir.

Published: 7/26/2019
Yayın Tarihi: 26.07.2019

Copyright © 2019 The Author(s)
Published by JOSAM

This is an open access article distributed under the terms of the Creative Commons Attribution-NonCommercial-NoDerivatives License 4.0 (CC BY-NC-ND 4.0) where it is permissible to download, share, remix, transform, and build up the work provided it is properly cited. The work cannot be used commercially without permission from the journal.



Abstract

Aim: Neurofibromatosis type 1 is a multisystem disorder, affecting primarily the skin, nervous and musculoskeletal systems. Various cardiovascular abnormalities, ranging from congenital heart disease to vasculopathy and hypertension are main clinical features of cardiovascular involvement. The aim of this study was to evaluate cardiac functions and carotid intima-media thickness by conventional and tissue Doppler echocardiography in terms of vasculopathy and cardiac involvement in children with neurofibromatosis type 1.

Methods: A cross-sectional study is designed with 36 Neurofibromatosis patients (20 boy and 16 girl) as study group, with a mean age of 9.7(3.5) years with 36 healthy controls (18 males and 18 females) with a mean age of 10.3 (2.2) years. Instant blood pressures were measured. Conventional and tissue Doppler echocardiography were performed. Carotid intima-media thickness, left ventricular ejection fraction and left ventricular fractional shortening were measured with M mode. Mitral early (E), late (A) flow velocities were measured by pulsed-wave Doppler, mitral early (E), late (A) flow velocities ratio was calculated. Tissue Doppler echocardiography was performed from the lateral annular junction of mitral valve and left ventricular myocardial performance index (Tei) index was calculated. Early diastolic flow (E') velocity was measured with tissue Doppler echocardiography.

Results: Left ventricular systolic functions were normal in both groups. Mitral early flow velocities were lower ($P<0.001$) in the study group. Also Mitral early / late velocities ratio was significantly lower ($P=0.004$) and mitral early flow velocity/ tissue Doppler early diastolic flow velocity ratio was higher ($P=0.045$) in the study group. The left ventricular Tei index was calculated as 0.42 (0.1) in the study group and 0.39 (0.1) in the healthy controls ($P=0.03$). The mean of carotid intima-media thickness was 0.46 (0.01) in the study group and 0.44 (0.01) in the control group ($P=0.002$). Systolic blood pressures were higher in the study group ($P=0.04$).

Conclusion: Tei index and diastolic flow velocities in mitral valve support the left ventricle diastolic dysfunction in children with neurofibromatosis type 1. Carotid intima-media thickness suggests vasculopathy and early effects of hypertension due to neurofibromatosis type 1.

Keywords: Neurofibromatosis, Carotid intima-media thickness, Heart

Öz

Amaç: Nörofibromatozis tip 1 öncelikle deri, sinir sistemi ve kas iskelet sistemini tutan multisistemik bir hastalıktır. Doğumsal kalp hastalıklarından vaskülopati, hipertansiyona kadar çeşitlilik gösteren kardiyovasküler tutulum olabilir. Nörofibromatozis tip 1 tanılı çocuklarda vaskülopati ve kardiyak etkilenme açısından konvansiyonel ve doku Doppler ekokardiyografi ile kalp fonksiyonlarının ve karotis intima media kalınlığının değerlendirilmesi amaçlandı.

Yöntemler: Nörofibromatozis tip 1 tanısı alan 36 hasta (20 erkek, 16 kız), 9,7 (3,5) yıl ve yaşları 10,3 (2,2) yıl olan 36 sağlıklı kontrol ile kesitsel çalışma yapıldı. Kan basınçları ölçülerek kaydedildi. Konvansiyonel ve doku Doppler ekokardiyografiyi uygulandı. M mod ile karotis intima media kalınlığı, sol ventrikül ejeksiyon fraksiyonu, sol ventrikül kısalma fraksiyonu ölçüldü. Diastolik mitral erken akım (E) ve mitral geç akım (A) velositeleri Doppler ile ölçüldü, mitral erken akım / geç akım oranı hesaplandı. Mitral kapak lateral anüler bileşkedeki doku Doppler ekokardiyografi yapıldı, myokardiyal performans indeksi (Tei) hesaplandı. Doku Doppler ile mitral erken diyastolik akım velositesi (E') ölçüldü.

Bulgular: Sol ventrikül sistolik fonksiyonları tüm hastalarda ve kontrollerde normaldi. Çalışma grubunda erken mitral akım velositeleri daha düşüktü ($P<0,001$). Çalışma grubunda mitral erken akım / geç akım oranı anlamlı olarak daha düşük ($P=0,01$), mitral erken akım/ doku Doppler mitral erken diyastolik akım oranı sağlıklı kontrollere göre daha yüksekti ($P=0,04$). Sol ventrikül Tei indeksi çalışma grubunda 0,42 (0,1) ve sağlıklı kontrol grubunda 0,39 (0,1) olarak hesaplandı ($P=0,03$). Karotis intima media kalınlığı çalışma grubunda 0,46 (0,01), sağlıklı kontrol grubunda 0,44 (0,01) idi ($P=0,002$). Çalışma grubunda sistolik kan basınçları anlamlı olarak daha yüksek saptandı ($P=0,04$).

Sonuç: Tei indeksi ve mitral kapaktaki diyastolik akım velositeleri Nörofibromatozis tanılı çocuklarda diyastolik disfonksiyonun başladığını göstermektedir. Karotis intima media kalınlığı nörofibromatozise bağlı vaskülopatiyi ve hipertansiyonun erken belirtisini düşündürmektedir.

Anahtar kelimeler: Nörofibromatozis, Karotis intima media kalınlığı, Kalp

Introduction

Neurofibromatosis type 1 (NF1) is an autosomal dominant disorder with an incidence of approximately 1:3000 [1,2]. NF1 is characterized by its cutaneous manifestations, café-au-lait spots, lentiginos, and neurofibromas with a variable clinical expression. Individuals with neurofibromatosis type 1 can develop various cardiovascular abnormalities, ranging from congenital heart disease to vasculopathy and hypertension [3]. Neurofibromatosis type 1 - related vasculopathy includes renal and cerebral artery stenosis, aortic coarctation and arteriovenous malformations [4]. Most individuals with NF1 vasculopathy are asymptomatic, which may contribute to underestimation of its frequency. Because of the potential pathogenetic significance of NF1-associated cardiovascular alterations, we aimed to evaluate the prevalence of cardiac and vascular involvement with M-mode, 2-dimensional echocardiography and tissue Doppler scan in children with NF1.

Materials and methods

Study population

This cross-sectional study was conducted between October 2011 and August 2014. Thirty-six children who referred to the Pediatric Cardiology outpatient clinic at the Kayseri Education and Research Hospital (Kayseri, Turkey) with the diagnosis of Neurofibromatosis type 1 were accepted as study group. The healthy control group consisted of 36 healthy children (18 boy and 18 girl) who were referred to the Pediatric Cardiology clinic for innocent murmur but had normal cardiac evaluation. The mean age of the study group were 10 years (range: 4-19 years). The diagnosis of NF1 was on the basis of the guidelines developed in the 1987 National Institutes of Health Consensus Development Conference Statement [5]. Written informed consent to participate in the study was obtained from the caregiver or the individual as appropriate.

Blood pressure (BP) was measured with a standard mercury sphygmomanometer after the subjects were allowed to rest for 5 minutes. Complete 2-dimensional echocardiograms and Doppler scan studies were obtained with Vingmed System 7 (Vivid 7, GE, Horten, Norway) with 3 MHz probes. Left ventricular fractional shortening (LVFS) and left ventricular ejection fraction (LVEF) were measured on M-mode echocardiography. Diastolic mitral inflow velocity was measured with pulsed-wave Doppler echocardiography in the apical four-chamber view. Early (E) and late (A) diastolic mitral peak velocities together with E/A ratios were calculated. All study participants were examined with tissue Doppler echocardiography (TDE). At least three cardiac cycles were recorded. The velocity curves were taken from the base of the mitral annulus at the insertion of the mitral leaflets in left ventricle free wall at the standard apical four-chamber view. Myocardial performance index or Tei index was calculated from the sum of the isovolumic contraction and relaxation times divided by the ejection time. It is considered a reliable parameter for global left ventricular function [6]. Mitral valve early diastolic tissue Doppler velocity (E') was. Mitral E/E' ratios were calculated. Carotid images were taken while the patients were in supine position with a cervical angulation of 30° towards the

contralateral side. Measurements were performed at a level including an area of 1 cm at the most distal part of the right and left main common carotid arteries, at the carotid bifurcation, and at an area 2 cm from the most proximal part of the internal carotid arteries. Carotid intima-media thickness (CIMT) measurements were obtained longitudinally at the distance between the vessel lumen echogenicity and the media/adventitia echogenicity using the M mode.

Statistical analysis

Statistical analysis was performed using the statistical package SPSS software (Version 16.0, SPSS Inc., Chicago, IL, USA). If continuous variables were normally distributed (Kolmogorov-Smirnov test or Shapira-Wilk), they were described as mean (standard deviation). Comparisons between groups were applied using Mann-Whitney U test were used for the data which is not normally distributed. While investigating the associations between non-normally distributed variables, the correlation coefficients and their significance were calculated using the Spearman test. Values of $P < 0.05$ were considered statistically significant.

Results

We included 36 NF1 patients (16 girl, 20 boy) for study group and 36 healthy children (18 girl, 18 boy) for control group. The mean age was 9.7(3.5) years (minimum: 5, maximum: 18) in the study group and 10.3(2.2) years (minimum: 6, maximum: 17 years) in the control group. No significant difference was detected between the study group and the healthy controls with regard to gender and age. There were 9 NF1 patients with electroencephalographic abnormalities and taking antiepileptic drugs. Twenty-six NF1 patients have pathognomonic findings on cranial magnetic resonance imaging. Optic glioma was detected in two patients. Mild-to- moderate mitral valve insufficiency due to mitral valve prolapsus was detected in four patients. Left ventricular hypertrophy was detected in one patient with plexiform neurofibroma. The instant blood pressures were summarized in Table 1.

Table 1: Instant blood pressures of study and control group

Blood pressure	Study group Mean (SD) (min-max)	Control group Mean (SD) (min-max)	P-value
TA systolic (mmHg)	128 (18) (110-140)	118 (13) (100-130)	0.04
TA diastolic (mmHg)	69 (14) (55-85)	66 (11) (60-85)	0.09

TA: Blood pressure, SD: Standard deviation

Systolic blood pressures of study group were statistically higher than those of the healthy controls ($P=0.04$). Left ventricle systolic functions obtained from conventional echocardiography (LVFS and LVEF) were compared, and no significant differences were detected between the study group and the healthy controls. The study group showed a significantly lower early mitral peak velocities (E) with respect to healthy controls ($P < 0.001$). There was a statistically significant ($P=0.004$) lower Doppler ratio of early to late transmitral flow velocity in the study group when compared with controls. Mitral E/E' ratios were statistically significant low in the study group ($P=0.045$). Tei indices of the study group were 0.42 (0.1) (minimum: 0.36, maximum: 0.51) and it was higher when compared with healthy controls [0.39 (0.1) (minimum: 0.31, maximum: 0.43)] ($P=0.03$). CIMTs were measured as 0.46

(0.01) in the study group and 0.44 (0.01) in the control group; measurement values were statistically higher in the study group ($P=0.002$) (Table 2) (Figure 1).

Table 2: Echocardiography results of study and control group

	Study group Mean (SD)	Control group Mean (SD)	P-value
Mitral E (m/s)	0.94 (0.02)	1.08 (0.02)	<0.001
Mitral A (m/s)	0.7 (0.02)	0.7 (0.01)	0.11
Mitral E/A	1.34 (0.06)	1.54 (0.05)	0.004
Mitral E/E'	6.6 (0.2)	6.1 (0.1)	0.045
LV Tei Index	0.42 (0.1)	0.39 (0.1)	0.03
Carotid Intima-Media Thickness (mm)	0.46 (0.01)	0.44 (0.01)	0.002

SD: Standard deviation

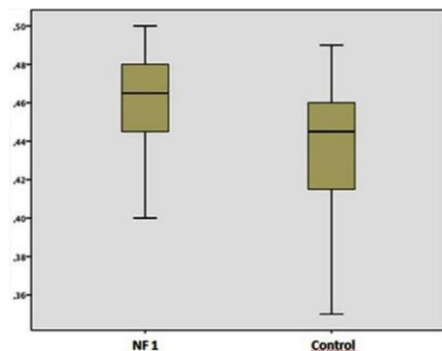


Figure 1: Carotid intima-media thickness of study group and healthy control

Discussion

Cardiac events and arrest due to vasculopathy are known pathologies in NF1 patients. Vasculopathy usually affects the arterial system, leading to cerebrovascular (e.g., narrowed or ectatic vessels, vascular stenosis, aneurysm, or moyamoya disease) or renal artery disease [4]. Left ventricular hypertrophy, mitral valve prolapsus and valve insufficiency, coarctation of aorta, and pulmonary valve stenosis have been reported in NF1 patients [7]. In this study, four patients had mild to moderate mitral valve deficiency due to mitral valve prolapsus. Systolic heart functions were similar between the study group and control group. There were significant differences in the diastolic Doppler velocities of study group when compared with the healthy controls. The exact mechanism of diastolic dysfunction should be explained with higher systolic blood pressures in the study group.

Tedesco and colleagues reported a shorter isovolumic relaxation time in NF1 patients than in controls [8]. In the current study, NF1 patients showed significantly lower early mitral peak velocities (E) with respect to controls, which reflects an impairment of the early (passive) phase of diastole requiring high energy consumption, namely active performance (relaxation) of the left ventricle. In addition, there was a lower Doppler ratio of early to late transmitral flow velocity, thus highlighting the predominant impairment of diastolic cardiac function.

It must be known that such pulsed-wave Doppler measurements are affected by multiple hemodynamic factors such as preload and heart rate variability. Tissue Doppler echocardiography measurements and Tei index are less affected from such factors. Tei indices were statistically higher in the study group, which reflects diastolic heart dysfunction with preserved systolic function.

CIMT is considered as a reflection of multiple risk factors; however, primary contributors to intima-media thickening are age and hypertension. The presence of hypertension significantly increases CIMT values due to

hypertrophy of the media layer of the vessel wall. Baroncini et al. [9] reported that CIMT was higher in hypertensive children and adolescents when compared to the control groups. Hypertension is a risk factor for intima-media thickening. In the current study systolic blood pressures were higher in the study group but just one patient with plexiform neurofibroma had hypertension and left ventricular hypertrophy. Xu et al. [10] reported an in vivo model of NF1 obstructive vascular disease and have shown that NF1 regulation of Ras plays a critical role in vascular smooth muscle proliferation after injury. Intimal thicknesses of the carotid artery, renal artery, aorta, and main branches should be measured for early diagnosis of NF1-related vascular disease and neointimal proliferation.

Our study has some limitations: First, although normal CIMT values based on age were identified for adults, a standard range according to age is unknown for pediatric populations. As no studies have been conducted on this topic thus far, it is not possible for us to draw a definitive conclusion on which CIMT values can be considered as abnormal in the pediatric age group. Until the standardization of CIMT values is achieved for children, researchers should perform comparisons with control groups that include healthy children or perform individual measurements regularly. Second, diastolic heart functions should be affected by multiple cardiovascular factors such as hypertension and vasculopathy. Heart functions should be checked regularly for prevention of dysfunction.

Conclusion

Tei index and diastolic flow velocities in mitral valve support the left ventricle diastolic dysfunction in children with neurofibromatosis type 1. Tei index is a more sensitive and precise method for evaluation of systolic and diastolic functions. CIMT monitoring should be useful for vasculopathy detection in NF1 patients.

Acknowledgement

The author gratefully acknowledge to Hatice Gamze Poyrazoğlu for referring the patients with the diagnosis of Neurofibromatosis type 1.

References

- Listernick R, Charrow J. Neurofibromatosis type 1 in childhood. *Adv Dermatol.* 2004;20:75-115.
- Hirbe AC, Gutmann DH. Neurofibromatosis type 1: a multidisciplinary approach to care. *Lancet Neurol.* 2014 Aug;13(8):834-43. doi: 10.1016/S1474-4422(14)70063-8
- Tedesco MA, Ratti G, Di Salvo G, Martiniello AR, Limongelli G, Grieco M, et al. Noninvasive evaluation of arterial abnormalities in young patients with neurofibromatosis type 1. *Angiology.* 2000 Sep;51(9):733-41
- Oderich GS, Sullivan TM, Bower TC, Gloviczki P, Miller DV, Babovic-Vuksanovic D, et al. Vascular abnormalities in patients with neurofibromatosis syndrome type I: clinical spectrum, management, and results. *J Vasc Surg.* 2007;46:475-84.
- Anon. National Institutes of Health Consensus Development Conference Statement: neurofibromatosis—Bethesda, MD, USA, July 13–15, 1987. *Neurofibromatosis.* 1988;1:172–8.
- Tei, C, Ling LH, Bailey KR, Hodge Do, Tajik AJ, Seward JB. New index of combined systolic and diastolic myocardial performance: a simple and reproducible measure of cardiac function—a study in normals and dilated cardiomyopathy. *J Cardiol.* 1995;26: 357-66.
- Lin AE, Birch PH, Korf BR, Tenconi R, Niimura M, Poyhonen M, et al. Cardiovascular malformations and other cardiovascular abnormalities in neurofibromatosis 1. *Am J Med Genet.* 2000;95:108–17.
- Tedesco MA, Di Salvo G, Natale F, Pergola V, Calabrese E, Grassia C, et al. The heart in neurofibromatosis type 1: an echocardiographic study. *Am Heart J.* 2002;143:883–8.
- Baroncini LAV, Sylvestre LC, Baroncini CV, Pecoits R Filho. Assessment of Carotid Intima-Media Thickness as an Early Marker Of Vascular Damage In Hypertensive Children. *Arq Bras Cardiol.* 2017 May;108(5):452-7. doi: 10.5935/abc.20170043.
- Xu J, Ismat FA, Wang T, Yang J, Epstein JA. NF1 Regulates a Ras-Dependent Vascular Smooth Muscle Proliferative Injury Response. *Circulation.* 2007;116:2148-56.

The National Library of Medicine (NLM) citation style guide is used in this paper. Suggested citation: Patrias K. Citing medicine: the NLM style guide for authors, editors, and publishers [Internet]. 2nd ed. Wendling DL, technical editor. Bethesda (MD): National Library of Medicine (US); 2007-[updated 2015 Oct 2; cited Year Month Day]. Available from: <http://www.nlm.nih.gov/citingmedicine>