



# Coexistence of endolymphatic hydrops and benign paroxysmal positional vertigo treated with repositioning maneuver: A case report

## Repozisyon manevrası ile tedavi edilen endolenfatik hidrops ve benign paroksizmal pozisyonel vertigo birlikteliği: Bir olgu sunumu

Süha Ertuğrul<sup>1</sup>, Emre Söylemez<sup>2</sup>, Tuğçe Gürel<sup>3</sup>

### Abstract

Benign paroxysmal positional vertigo (BPPV) is a peripheral vestibular disease that occurs by sudden head movements and is characterized by dizziness that lasts for seconds. Endolymphatic hydrops is a vestibular pathology that causes hearing loss, tinnitus, fullness in the ear and dizziness due to increased endolymphatic pressure in the inner ear. Although BPPV and endolymphatic hydrops are considered as two different entities, it has recently been reported that there may be a relationship between these two diseases. However, the pathophysiology of this relationship has not been clearly elucidated. In this paper, we discussed the relationship between these two diseases accompanied by a patient with a sudden onset of endolymphatic hydrops and BPPV which was treated with repositioning maneuver.

**Key words:** Benign paroxysmal positional vertigo, endolymphatic hydrops, hearing loss, repositioning maneuver.

### Öz

Benign paroksizmal pozisyonel vertigo (BPPV), ani baş hareketleriyle ortaya çıkan ve saniyeler süren baş dönmesiyle karakterize periferik vestibüler bir hastalıktır. Endolenfatik hidrops ise iç kulakta endolenfatik basıncın artmasına bağlı olarak işitme kaybına, kulak çınlamasına, kulakta dolgunluk hissine ve baş dönmesine neden olan vestibüler bir patolojidir. BPPV ve endolenfatik hidrops iki farklı antite olarak düşünülse de, son zamanlarda bu iki hastalık arasında bir ilişki olabileceği bildirilmiştir. Ancak bu ikilinin patofizyolojisi açık bir şekilde aydınlatılamamıştır. Biz bu yazıda, repozisyon manevrası ile düzelen ani gelişmiş endolenfatik hidrops ve BPPV birlikteliği olan bir olgu eşliğinde bu iki hastalık arasındaki ilişkiyi tartıştık.

**Anahtar Kelimeler:** Benign paroksizmal pozisyonel vertigo, endolenfatik hidrops, işitme kaybı, repozisyon manevrası.

## Introduction

Positional dizziness that occurs when otoconia particles in the utricle fall into the semicircular canals, or these crystals adhere to the cupula in the ampullas is defined as benign paroxysmal positional vertigo (BPPV). BPPV is the most common cause of vertigo caused by the peripheral vestibular system. The second most common cause of vertigo following BPPV is endolymphatic hydrops.

Although symptoms of these two diseases are quite different, recent studies on the relationship between BPPV and endolymphatic hydrops have been reported [1]. However, the relationship between the two diseases has not been fully explained. In our knowledge, there is no study in the literature on endolymphatic hydrops symptoms treated with repositioning maneuver.

In this paper, we discussed the relationship between these two diseases accompanied by a patient with a sudden onset of endolymphatic hydrops and BPPV which was treated with repositioning maneuver.

<sup>1</sup> Department of Otorhinolaryngology, Karabük University, Faculty of Medicine, Karabük, Turkey.

<sup>2</sup> Department of Audiology, Karabük University Training and Research Hospital, Karabük, Turkey.

<sup>3</sup> Department of Audiology, Gelisim University, Istanbul, Turkey.

**Informed Consent:** The written consent was received from the patient who was presented in this study.

**Hasta Onamı:** Çalışmada sunulan hastadan yazılı onam alınmıştır.

**Conflict of Interest:** No conflict of interest was declared by the authors.

**Çıkar Çatışması:** Yazarlar çıkar çatışması bildirmemişlerdir.

**Financial Disclosure:** The authors declared that this case has received no financial support.

**Finansal Destek:** Yazarlar bu olgu için finansal destek almadıklarını beyan etmişlerdir.

Geliş Tarihi / Received: 23.05.2019

Kabul Tarihi / Accepted: 04.07.2019

Yayın Tarihi / Published: 01.08.2019

Sorumlu yazar / Corresponding author

Süha Ertuğrul

Adres/Address: Şirinevler mahallesi, Alpaslan caddesi, No: 1, Merkez, Karabük, Türkiye.

e-mail: drsuhaertugrul@hotmail.com

Tel/Phone: +90 370 4125628

Copyright © ACEM

## Case report

A 43-year-old male patient was admitted to the otorhinolaryngology outpatient clinic with a complaint of dizziness. In his anamnesis, he stated that he had a sudden vertigo attack while cutting wood three days earlier and that vertigo lasted for about 30 minutes. He stated that there was fullness, hearing loss and tinnitus in the right ear which started after vertigo attack and still persist. In the process following the first attack, he reported that his head was spinning during sudden movements when he was lying on the bed and getting out of bed. The otoscopic examination of the patient revealed no pathology. In the audiological examination, sensorineural hearing loss (SNHL) was present at the lower frequencies in the right ear in the pure tone audiometry test (Figure 1A). The mean pure tone average was bilateral normal (right ear: 7.5 dB, left ear: 3.5 dB). In the immittance examination, the patient had bilateral type A tympanogram and 500, 1000, 2000 and 4000 Hz acoustic reflex thresholds were in the normal range. In the vestibular evaluation, the cervical vestibular evoked myogenic potential (c-VEMP) test, the Romberg test, the Fukuda test, tandem posture with eyes closed, tandem gait test with eyes open were performed. Oculomotor tests, Dix Hallpike test, supine roll test, and caloric test were performed under videonistagmography. Although the patient's history and symptoms indicated endolymphatic hydrops, the c-VEMP responses at 1000 Hz were within the normal limits (Figure 1B). The Fukuda test of the patient was lateralized to the right side. The Romberg and tandem gait with eyes open tests were normal. The tandem posture with eyes closed test was positive. Oculomotor tests were within the normal limits and the patient did not have spontaneous nystagmus. The Dix-Hallpike test performed on the right ear of the patient revealed horizontal-rotatory nystagmus with a vertical component lasting 20 seconds. When the patient was brought to the sitting position, a reverse phase of the nystagmus was observed (Fig. 1C). The Dix-Hallpike test performed in the left ear and supine roll tests were normal. In the caloric test, there was a 20% response asymmetry to the right side. After these tests, the patient was diagnosed with right posterior semicircular canal BPPV and endolymphatic hydrops in the right ear. Epley maneuver was performed for the right ear. After the maneuver, the patient stated that the dizziness had decreased and there was no nystagmus in the control Dix-Hallpike test. After 1 day, the patient was called back for the audiological evaluation. In the pure tone audiometry test, SNHL in the lower frequencies in the right ear was found to be improved (Figure 1D). The patient stated that the tinnitus and fullness in his right ear had improved. The patient was not given medical treatment. During the 1-year follow-up, the patient had no episodes of vertigo. A written consent form was taken from the patient.

## Discussion

BPPV causes vertigo which occurs suddenly with a change in the head's position and usually lasts for seconds. The direction and characteristics of nystagmus in BPPV differ according to the semicircular canal involved. In our case, the latency, direction, duration, and fatigue of the nystagmus encountered in the right ear in the Dix-Hallpike test performed on the patient had typical characteristics of the right posterior canal BPPV nystagmus. Head trauma, hormonal changes, aging and sleep position may be etiological factors in BPPV [2]. In our case, we think that the vibration of the patient's body during the wood crushing and the patient's continuous bending this process caused the dislocation of the otoconias.

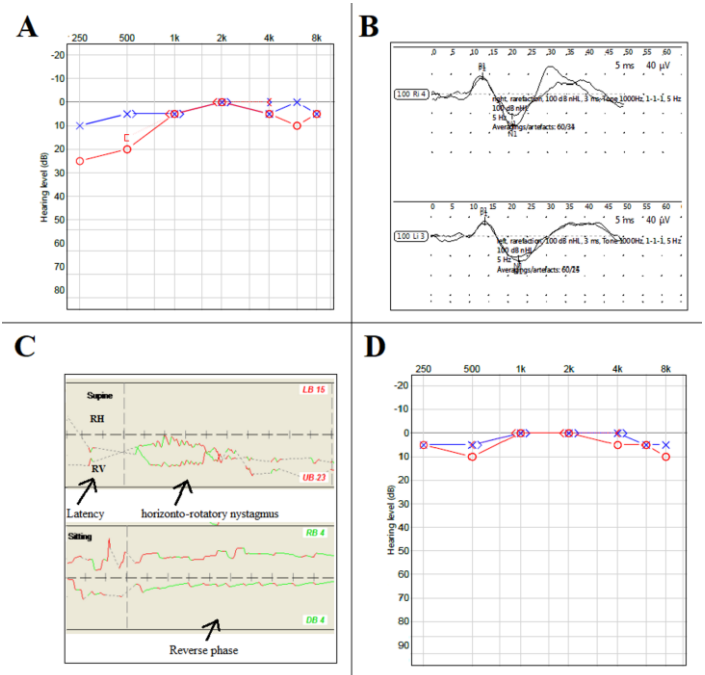


Figure 1. A, B, C, D: (A) Pure tone audiometry test shows sensorineural hearing loss in the right ear involving low frequencies. (B) Cervical vestibular evoked myogenic potential (c-VEMP) responses at 1000 Hz with 100 dB NHL intensity level (amplitude: right ear=47.2  $\mu$ v, left ear=48.6  $\mu$ v; latency: right ear: P1:13.9 ms, N1:22.9 ms, left ear: P1:13.2ms, N1:21.9 ms). (C) Nystagmus occurring during the Dix-Hallpike test recorded on videonistagmography. (D) Pure tone audiometry test performed 24 hours after the Epley maneuver shows that the sensorineural hearing loss involving low frequencies improved.

In endolymphatic hydrops, episodic dizziness, tinnitus, and floating hearing loss occur with increased endolymphatic pressure. Endolymphatic hydrops may occur primarily in cases such as Mondini aplasia and Meniere's disease [3]. It may also occur secondary to head trauma and ear surgeries [3]. In the anamnesis, floating hearing loss during vertigo attacks, tinnitus, ear fullness and episodic vertigo attacks lasting for hours are the most important criteria in the diagnosis of endolymphatic hydrops. SNHL, which occurs in low frequencies in the pure tone audiometry test, is typical for endolymphatic hydrops. In our case, because of the typical endolymphatic hydrops findings in audiometry, otoacoustic emission test and Auditory Brainstem Response test were not performed. The c-VEMP test can also be used for diagnosis purposes. In the early stages of the disease, c-VEMP responses can be obtained normally. In the later period of the disease, c-VEMP responses are lost [4]. In our case, it was considered natural for c-VEMP responses to be normal because the patient experienced the first vertigo attack. Glycerol test is another diagnostic method used in the diagnosis of Meniere's disease. In a study, 77 Meniere patients had 70% gliscol test positivity, whereas non-Meniere sensorineural hearing loss patients had no positive glycerol test [5]. However, we did not perform the glycerol test in our case. Electrocochleography is an important diagnostic tool in Meniere's disease. In Meniere's disease, an increase in the summation potential / action potential ratio is observed on electrocochleography. However, there are some studies indicating that the role of electrocochleography in the diagnosis of Meniere cannot be very meaningful [6]. In our case, we could not do electrocochleography due to limited facilities. In recent years, magnetic resonance imaging after intratympanic gadolinium injection has gained value in radiological imaging of endolymphatic hydrops [7]. However, we could not have MRI with gadolinium in our case. The

diagnosis of endolymphatic hydrops was made with tinnitus, fullness in the ear and hearing loss involving low frequencies described by the patient.

As the endolymphatic pressure in the scala media increases, the pressure to Reissner's membrane and the basilar membrane is increased. This pressure affects hairy cells called cilia, which are responsible for hearing and balance, making the cilia more insensitive [8]. Thus, an episodic dizziness attack and floating hearing loss occur. The relationship between BPPV and endolymphatic hydrops was first investigated by Mizukoshi et al. [9]. They reported that there was an epidemiological relationship between BPPV and endolymphatic hydrops [9]. In a study conducted by Hughe et al. [10] on 151 BPPV patients, they reported that 45 BPPV patients had also Meniere's disease. Jahn [11] reported that every 100 non-diagnosed vertigo patients had both BPPV and endolymphatic hydrops. The high incidence of the coexistence of these two diseases can be explained in three ways. The first is the idea that both diseases may develop due to a common etiological factor. Studies have shown that both diseases may occur in head trauma and inflammatory conditions [2, 3]. In our case, a mechanism similar to the formation of BPPV during wood crushing may have caused endolymphatic hydrops to displace the otoconias that may be present in the saccule. The second possibility is the idea that endolymphatic hydrops may trigger BPPV. Karlberg et al. [1] suggested that diseases such as vestibular neuritis, labyrinthitis, and Meniere's disease may dislocate otoconia by damaging utricle and cause BPPV. In a recent review consisting of a series of 3 cases, it was stated that BPPV might trigger endolymphatic hydrops, as a third mechanism [11]. Walter and Raymond [12] found that the endolymph fluids of Meniere patients were more intense in terms of protein content. In another study, Johnsson et al. [13] reported that the content of endolymph fluids in patients who developed endolymphatic hydrops as a result of cochlear otosclerosis was more intense than normal. Otoconia are known to consist of calcium and protein [11]. In this case, displaced otoconia can change the density of the endolymph and increase osmotic pressure. The increased osmotic pressure may cause endolymphatic hydrops. The relationship between BPPV and endolymphatic hydrops can be also explained by this hypothesis in addition to other hypotheses.

In conclusion, in a patient with endolymphatic hydrops and BPPV, both diseases may develop secondary to a common etiologic factor, or endolymphatic hydrops may induce BPPV or, finally, dislocated crystalloids in BPPV may cause endolymphatic hydrops. Trauma may cause endolymphatic hydrops by displacing otoconias in the saccule as it causes BPPV by displacing the otoconias in the utricle. In patients with coexistence of BPPV and endolymphatic hydrops, endolymphatic hydrops findings may also improve after repositioning maneuver for BPPV treatment.

## References

- Karlberg M, Hall K, Quickert N, Hinson J, Halmagyi GM. What inner ear diseases cause benign paroxysmal positional vertigo? *Acta Otolaryngol.* 2000;120:380-5.
- Lee SH, Kim JS. Benign paroxysmal positional vertigo. *J Clin Neurol.* 2010;6:51-63.
- Chen YJ, Young YH. Secondary endolymphatic hydrops after acoustic trauma. *Otol Neurol.* 2016; 37:428-33.
- Young YH, Huang TW, Cheng PW. Assessing the stage of Meniere's disease using vestibular evoked myogenic potentials. *Arch Otolaryngol Head Neck Surg.* 2003;129:815-8.
- Arenberg IK, Stroud MH, Spector GJ, Carver WF. The salt loading provocative glycerol test for the early diagnosis of auditory endolymphatic hydrops (Meniere's disease) (a preliminary report). *Rev Laryngol Otol Rhinol (Bord).* 1974;95:709-19.
- Levine S, Margolis RH, Daly KA. Use of electrocochleography in the diagnosis of Meniere's disease. *Laryngoscope.* 1998;108:993-1000.
- Naganawa S, Sugiura M, Kawamura M, Fukatsu H, Sone M, Nakashima T. Imaging of endolymphatic and perilymphatic fluid at 3T after intratympanic administration of gadolinium-diethylene-triamine pentaacetic acid. *AJNR Am J Neuroradiol.* 2008;29:724-6.
- Durrant JD, Dallos P. Modification of DIF summating potential components by stimulus biasing. *J Acoust Soc Am.* 1974; 56:562-70.
- Mizukoshi K, Watanabe Y, Shojaku H, Okubo J, Watanabe I. Epidemiological studies on benign paroxysmal positional vertigo in Japan. *Acta Otolaryngol Suppl.* 1988;447:67-72.
- Hughes CA, Proctor L. Benign paroxysmal positional vertigo. *Laryngoscope.* 1997;107:607-13.
- Jahn AF. Benign positional vertigo and endolymphatic hydrops: what is the connection? *J Laryngol Otol.* 2017;131:658-60.
- Waltner JG, Raymond S. On the chemical composition of perilymph and endolymph. *Laryngoscope.* 1950;60:912-18.
- Johnsson LG, Hawkins JE Jr, Rouse RC, Linthicum GH Jr. Cochlear and otoconial abnormalities in capsular otosclerosis with hydrops. *Ann Otol Rhinol Laryngol Suppl.* 1982;97:3-15.