

Pediatric Üst Solunum Yolunun Rijit Teleskop Video Laringoskopi Yöntemi ile Değerlendirilmesi

Evaluation of Pediatric Upper Airway Diseases with Rigid Telescope Video Laryngoscopy

İbrahim Ketenci¹, Alperen Vural¹, Kerem Kökoğlu², Mehmet İlhan Şahin¹

¹Erciyes Üniversitesi, Tıp Fakültesi, KBB Hastalıkları ve Baş Boyun Cerrahisi

²Develi Devlet Hastanesi, Kayseri, Türkiye

ÖZ

GİRİŞ ve AMAÇ: Pediatric üst solunum yolu problemlerinin ayırıcı tanısı zordur. En iyi method direkt görüntülemektir. Fleksibl nazofaingoskopi en sık uygulanan yöntemdir. Rijit teleskop video laringoskopi (RTVL), fleksible nazofaringoskopi uygulanamayan hastalarda bir alternatif olabilir. Bu çalışmada RTLV ile üst solunum yolu değerlendirilen hasta sonuçlarının değerlendirilmesi amaçlanmıştır.

YÖNTEM ve GEREÇLER: Üst solunum yolu problemi nedeniyle RTVL uygulanan hastalar retrospektif olarak çalışmaya dahil edildi. Hastaların semptomları, ek hastalıkları ve bulguları kaydedildi. Uygulamalar 30 derece rijit teleskop video laringoskop ile aynı tecrübeli KBB uzmanınca gerçekleştirildi. Hastalar fleksibl nazofaringoskopi yapılamayan ya da cerrahi planlanan hastalara yapıldı. Bulgular ve cerrah işlemler kaydedildi.

BULGULAR: 332 hastaya 427 işlem uygulandı. Stridor en sık endikasyondur. En sık bulgu laringomalaziydi. 73 hastada endikasyon ekstübasyon başarısızlığıydı. Bu hastaların 59'unda entübasyon granülomu en sık bulguydu. 67 hastaya trakeotomi işlemi yapıldı. Trakeotomi için en sık endikasyon uzamış entübasyondur. Tüm işlemler içinde tek ciddi komplikasyon bir hastada gelişen bradikardiydi ve uygun müdahale ile normale döndü.

TARTIŞMA ve SONUÇ: Stridor ve uzamış entübasyon pediatric üst havayolu için en sık semptomdu. Gastro-özefageal reflü ile birlikte olan ya da olmayan laringomalazi en sık bulguydu. Rijit teleskop - video laringoskopi uygulaması, fleksibl nazofaingoskopi yapılamayan hastalarda yararlı bir methodtur.

Anahtar Kelimeler: stridor, laringomalazi, ses kısıklığı, entübasyon

Yayın hakları Güncel Pediatri'ye aittir.

Sorumlu yazar yazışma adresi: İbrahim KETENCİ. Erciyes Üniversitesi, Tıp Fakültesi, KBB Hastalıkları ve Baş Boyun Cerrahisi, Kayseri, Türkiye

SUMMARY

INTRODUCTION: It is hard to make a differential diagnosis of upper airway diseases in pediatrics. Best method is direct visualization. Flexible nasopharyngoscopy is the most performed method. Rigid telescope-video laryngoscopy (RTVL) could be an alternative in patients who can not be performed flexible nasopharyngoscopy. It is aimed to review RTVL results of pediatric patients for the evaluation of upper airway problems.

METHODS: A retrospective analysis of patients who underwent RTVL because of upper airway problems were conducted in the study. The patients' symptoms, additional diseases and examination findings were recorded. The examinations were performed with a 30 degree rigid telescope – video laryngoscopy by a same, experienced physician. The procedures were performed when flexible video nasopharyngolaryngoscopy was unsuccessful or when any kind of surgical intervention was planned. Examination findings as well as the surgical procedures performed were recorded.

RESULTS: Total of 427 procedures were performed to 332 patients. Stridor was the most common indication for the procedure. The most common examination finding was laryngomalacia. There were 73 patients who had extubation failure and were applied rigid telescope – video laryngoscopy for this reason. Fifty-nine patients had intubation granuloma and this was the most common finding in patients with extubation failure. Tracheotomy was applied to 67 patients. The most common indication for tracheotomy was prolonged intubation. One patient experienced bradycardia during all procedures who recovered with appropriate intervention.

DISCUSSION and CONCLUSION: Stridor and prolonged intubation were the most common symptoms of pediatric upper airway diseases. Laryngomalacia with or without gastro-esophageal reflux were the most common causes. Rigid telescope – video laryngoscopy may be a useful method to evaluate pediatric upper airway diseases when flexible laryngoscopy can not be performed.

Keywords: stridor, laryngomalacia, hoarseness, intubation

Introduction

Evaluation of the larynx and the upper airway is crucial in patients with stridor, voice disorders and other upper airway symptoms. This evaluation can be troublesome in children. Although this examination can be done by flexible fiber optic laryngoscopy or indirect laryngoscopy in older children, it might be difficult in newborns and toddlers [1].

Children with congenital upper airway anomalies may have multiple pathologies in the airway thus a complete examination of the upper airway must be performed to achieve a keen diagnosis. Rigid telescope – video laryngoscopy (RTVL) is an appropriate method of examination in children on whom flexible fiber optic laryngoscopy (FFL) or indirect laryngoscopy cannot be performed. RTVL is a kind of direct laryngoscopy supported by video and recording system. Direct laryngoscopy is a useful procedure for intubation and examination of the upper airway in children. RTVL is a modified technique supported by video system. There is no article which named this procedure as RTVL in the literature. This study presents the results of 427 RTVL procedures over 9 year's period.

Materials and Methods

The study was planned as a retrospective study. After the approval of local ethical committee (Nr: 2018-160), the study was performed. Patients and collecting data: Patients who underwent RTVL between January 2007 and December 2016 were enrolled into the study and the data was examined retrospectively. The ages, genders, any comorbidities, procedure indications and examination findings of the patients were recorded. Children who underwent flexible fiber optic laryngoscopy or indirect laryngoscopy and had pharyngolaryngeal infection were ruled out. Patients were divided into 3 groups according to their ages as; newborns (0-28 days), infants (29 days-24 months) and toddlers (25 months -6 years).

Definitions: Laryngomalacia was defined as a larynx with omega-shaped elongated epiglottis, short aryepiglottic folds and collapsing of these structures towards the glottis during inspiration. Myer-Cotton staging system was used in order to stage subglottic stenosis[2]. To define a vocal cord paralysis, movements of vocal cords of patients were examined. If a patient was re-intubated in 48 hours after extubation, it was defined as extubation failure. When intubation time of a patient was longer than 7 days, it was defined as prolonged intubation. Post-cricoidal hyperemia and edema of arytenoids were accepted as gastro-esophageal reflux disease (GERD) findings.

Anesthesia: After oxygenation, anesthesia was induced by midazolam (0.1 mg/kg), sufentanyl (0.1–0.2 µg/kg), and propofol (1–2 mg/kg) intravenously. During procedures; electrocardiograms, noninvasive blood pressure measurements and pulse oximeters were continuously examined by a surgical monitor. In addition, the ventilation status was observed by auscultation of the lungs, skin color, and observation

of thorax excursions as well as following via the monitor. Muscle relaxants were not used in order to see vocal cord movements and respiration at the upper airway and to avoid tracheal intubation. Anesthesia was maintained with an infusion of propofol (6–8 mg/kg/h). After anesthesia induction, spontaneous breathing was maintained. Tracheal intubation and general anesthesia conditions were prepared for the possibility of hypoxemia and other respiratory and cardiac complications.

Procedure: RTLTV was a kind of direct laryngoscopy supported by video and recording system. While a child was unconscious, not intubated or paralyzed, RTLTV was performed. Firstly, the tongue base was elevated by an intubation laryngoscope and 30 degree telescope was proceeded through the larynx. Laryngeal structures and vocal cord movements could be seen. Then telescope was conducted to subglottic area. All procedures were applied by an experienced otolaryngologist. Before the procedures, a written informed consent was obtained from the parents both for the procedures and for the use of the patient data in scientific purposes. After the induction of anesthesia, the operator elevated the tongue base with an appropriate size of laryngoscope. Then; upper airway (oropharynx, tongue base, hypopharynx, supraglottis, vocal cords, subglottic area, upper esophagus, and trachea) was examined by 30°, 4 mm telescope (Karl Storz, Tuttlingen, Germany). Images were transferred to a HD monitor by a video system and recorded.

Findings

There were 332 patients enrolled into the study (174 boys and 158 girls) who underwent a total of 427 procedures. The ages were between 0-6 years. The youngest patient was 0 days old and the oldest one was 6 years old. Infants (29 days – 2 years) consisted 67.8 % of all patients (N=225). The most common indication of RTVL was stridor (48.8%, N:162) followed by extubation failure (22%, N:73). Table 1 shows the indications of procedures.

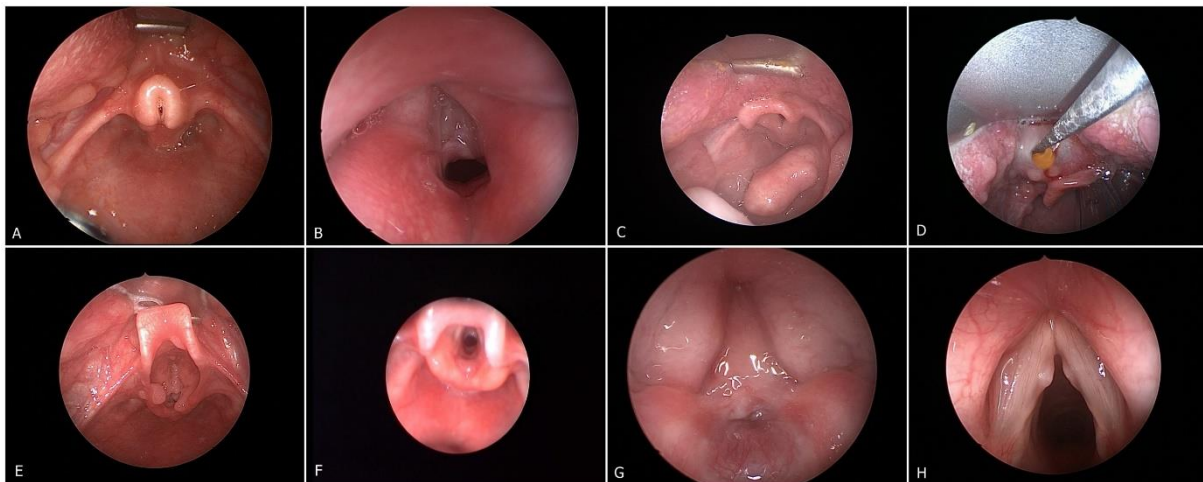
Table I. Rigid Telescope Video Laryngoscopy Indications According To Age Groups;

Indications	0 - 28 days (n:44; 13.25%)	29 days – 24 months (n:225; 67.77%)	25 months - 6 years (n:63; 19%)	Total %* (n:332)
Stridor	14 (8.6 %)	126 (77.7 %)	22 (13.6 %)	162 (48.8 %)
Extubation Failure	10 (13.7 %)	51 (69.8 %)	12 (16.4 %)	73 (22.0 %)
Respiratory Distress	12 (21 %)	32 (56.1 %)	13 (22.8 %)	57 (17.2 %)
Hoarseness	6 (25 %)	11 (45.8 %)	7 (29.1 %)	24 (7.2 %)
Dysphagia	2 (18.2 %)	3 (27.3 %)	6 (54.5 %)	11 (3.3 %)
Aspiration	-	2 (40 %)	3 (60 %)	5 (1.5 %)

**indicates the percent of total indications, not about age groups.*

There were 23 patients with normal upper airway. 309 patients had at least one upper airway pathology. Twenty-nine patients had 2 and 2 patient had 3 different pathologies at the same time when patients with only GERD were excluded. Laryngomalacia (Figure 1A) was the most common examination finding in patients with stridor followed by intubation granuloma (Figure 1B). Table 2 shows the examination findings during procedure. Eighty-one patients (24.4%) underwent surgery following RTVL procedures. The surgeries performed were; 67 tracheotomies, 18 endo-laryngeal laser surgeries, 6 cold-knife surgeries, 13 granuloma excision, 1 laryngocele excision, 1 hypo-pharyngeal mass excision (Figure 1C), 1 tongue-base mass excision (Figure 1D) and 3 foreign body extraction.

Figure 1: Picture showing laryngoscopy findings.



A: Laryngomalacia, B: Intubation Granuloma, C: Hypopharyngeal mass, D: Tongue base mass, E: Laryngeal papillomatosis, F: Subglottic stenosis, G: laryngeal atresia, H: Vocal nodules

Sixty-one patients underwent RTVL more than once. A patient with laryngeal papillomatosis (Figure 1E) was taken to the operation 8 times either for tracheotomy or laser surgery. Fifty of these 61 patients had tracheotomies and RTVL was performed to evaluate the airway if decannulation was appropriate. Seventy-three RTVL's were applied for extubation failure. There were 59 patients who had had intubation granuloma, 29 subglottic stenosis (Figure 1F), 9 bilateral vocal cord paralysis, 10 left vocal cord paralysis and 2 tongue-base mass. The mean intubation time was 24.13 days before tracheotomy. An urgent tracheotomy was performed to a baby with laryngeal atresia (Figure 1G).

There were 9 patients who had bilateral vocal cord paralysis. Four had metabolic disease. Etiology was unknown in others. There were 11 patients with unilateral vocal cord paralysis 10 of which were on the left. Five patients with left vocal cord paralysis had a history of cardiac surgery, 3 of them for Fallot's tetralogy and 2 for ventricular septal defect. There were 5 patients with laryngeal web and 7 patients with vocal nodule (Figure 1H). Stridor was the main complaint in laryngeal web patients, while hoarseness was the main in vocal nodule patients. Eighty-one patients (24.4%) had GERD which had concurrent laryngomalacia. Rate of GERD in patients with laryngomalacia was 40.1%. Severe

bradycardia occurred in one patient during the procedure which was immediately managed by anaesthesiology team. No other complication was observed.

Table II. Examination Findings According To Age Groups;

Findings	0-28 days (n:41; 12%)	29 days – 24 months (n:236; 69%)	25 months - 6 years (n:65, 19%)	Total (n:342)
Laryngeal Problems				
Laryngomalacia	16 (13.2 %)	93 (76.9 %)	12 (9.9 %)	121
GERD+Laryngomalacia	-	63 (77.7 %)	18 (22.2 %)	81
Laryngeal Nodule	-	2 (28.6 %)	5 (71.4 %)	7
Laryngeal Web	2 (40 %)	3 (60 %)	-	5
Laryngeal Papillomatosis		1 (33.3 %)	2 (66.6 %)	3
Laryngeal Foreign Body		1 (33.3 %)	2 (66.6 %)	3
Laryngocele	-	1 (50 %)	1 (50 %)	2
Epiglottic Anomaly	1 (50 %)	1 (50 %)	-	2
Laryngeal Cleft	-	1 (100 %)	-	1
Saccular cyst		1 (100 %)		1
Laryngeal Atresia	1 (100 %)	-	-	1
Glottic Problems				
Intubation Granuloma	8 (13.5 %)	34 (57.6 %)	17 (28.8 %)	59
Left Vocal Cord Paralysis	2 (20 %)	6 (60 %)	2 (20 %)	10
Bilateral Vocal Cord Paralysis	2 (22.2 %)	5 (55.6 %)	2 (22.2 %)	9
Right Vocal Cord Paralysis	-	-	1 (100 %)	1
Subglottic Problems				
1 ⁰ Subglottic Stenosis	5 (35.7 %)	8 (57.1 %)	1 (7.1 %)	14
2 ⁰ Subglottic Stenosis	1 (9.1 %)	8 (72.7 %)	2 (18.2 %)	11
3 ⁰ Subglottic Stenosis		1 (50 %)	1 (50 %)	2
Subglottic hemangioma		2 (100 %)		2
Tracheomalacia		2 (100 %)		2
Other Problems				
Tongue-Base Mass	1 (50 %)	1 (50 %)	-	2
Tracheo-esophageal Fistula	1 (100 %)			1
Hypopharyngeal hamartoma	-	1 (100 %)	-	1
Palatal Giant Polyp	1 (100 %)	-	-	1
<i>There were normal examination findings in 3,12 and 8 patients in groups respectively.</i>				

Discussion

Endoscopic examination is very crucial in the diagnosis of laryngeal upper airway pathologies. Either with rigid direct laryngoscopy (RDL) or with flexible fiber optic laryngoscopy (FFL) the larynx and the upper and sometimes the lower airway must be examined [3]. Each of the methods has advantages and disadvantages and also in a way they complete each other. In FFL technique, the instrument is passed through the nose, nasopharynx and oropharynx and vision is provided. In selected cases it can even be extended through the trachea and bronchia if needed. It provides a magnified image by a fiber optic light source [4]. Because FFL is performed during spontaneous respiration, respiration dynamics can be observed better in this technique [5]. In RDL procedure, the larynx is examined by a tubular tool with naked eyes. The tool is placed inside the mouth on larynx or vallecula. Sometimes vision is provided by a microscope or rigid telescope [3]. Intubation is often needed in this technique which might disrupt the vision. In RDL, laryngeal movements can not be seen. They are disadvantages of this technique [6]. Glass rod telescopes are developed for RDL and this provides a better vision than FFL, which is the advantage of RDL [7].

In the presented RTVL technique, 30⁰, 4 mm rigid telescopes (Karl Storz, Tuttlingen, Germany) were used. With the use of a 30⁰ telescope, the laryngeal structures can be adequately seen. The procedures were performed during spontaneous respiration and apneic intermittent ventilation, thus respiration dynamics - especially movements of vocal cords and epiglottic collapse - for the diagnosis of laryngomalacia and paralysis could be well observed. The procedure does not require tracheal intubation.

This technique provides observation of the respiration dynamics as FFL does. Images received are transferred to video screen and are routinely recorded. The limited vision disadvantage of RDL is avoided. Without sedation, the awake approach is typically limited to a diagnostic evaluation of the upper airway by which the dynamic conditions can also be observed. It can be safely performed in an office setting under topical anesthesia without sedation in children of all ages. The limitation of performing this procedure in an office setting without sedation is the inability to pass the scope below the vocal cords [8].

Spontaneous ventilation under general anesthesia is generally used for endoscopy of the pediatric airway. However, the multiple techniques in use indicate that no single method is universally accepted. Spontaneous breathing techniques in neonates and infants should be limited to shorter examinations. Under anesthesia; a combination of reduced elastance and high compliance of the pediatric airways and chest wall, increased oxygen consumption and further airflow limitations imposed by the surgical instrumentation inside and around the airway can lead to a rapid hypoxemia if spontaneous ventilation is maintained. If spontaneous ventilation fails due to apnea or hypoventilation, institution of alternative ventilation techniques must be promptly implemented [8].

For the physiologic reasons mentioned previously, apneic intermittent ventilation (AIV) in young pediatric patients is suitable for only very short procedures, such as a diagnostic bronchoscopy [8].

In children, supraglottic jet ventilation (JV) is probably most commonly used. Subglottic JV is used less frequently, because the smaller, compliant airways of infants and small children may not allow adequate exhalation, potentially leading to a higher incidence of barotrauma [9]. We used combination of spontaneous breathing and AIV in our procedure. Upper airway was examined with spontaneous ventilation to investigate vocal cord movements and supraglottic structures during inspiration, which is very important to diagnose laryngomalacia. Lower airway was examined with AIV to avoid laryngospasm.

When indications of procedure were investigated; the most common reason was stridor. Stridor is defined as noisy breathing which occurs because of turbulent flow in the airway in narrowed places [10]. It can be congenital or acquired. History of mechanical ventilator must be asked in a child with stridor. Laryngomalacia, vocal cord paralysis and congenital subglottic stenosis could be reasons for congenital stridor. Acquired stridor is usually related to mechanic ventilation and intubation granuloma, subglottic stenosis and laryngeal edema [11, 12]. Inspection of larynx is necessary in a child with stridor. The diagnosis of laryngomalacia, subglottic stenosis, vocal cord palsy and intubation granuloma were easily set by RTVL method. The most common cause of stridor in our series was laryngomalacia followed by subglottic stenosis, vocal cord palsy and laryngeal web.

Extubation failure was the second reason for RTVL. It can be defined as re-intubation of a patient after extubation. There are different sights about time between extubation and re-intubation for definition of extubation failure. Gupta et al.[13] defined this period as 24 hours; while Edmunds et al. [14] emphasized it as 48 hours. In the current study, if a patient was re-intubated in 48 hours after extubation, it was defined as extubation failure. There are some anatomical and physiological reasons for extubation failure. Subglottic area is narrow in children. Therefore; intubated younger children tend to develop subglottic edema, granuloma and stenosis[14]. Besides; compliance of chest wall increases and elastance decreases in younger children. Children consume more effort than adults to provide same tidal volume. Intubation granuloma was the most common cause of extubation failure in the present study. Baisch et al. reported 4.1% of 3193 children with extubation failure which the most common causes are multifactorial and upper airway obstruction [15]. Jang et. al reported that to avoid developing of intubation granuloma appropriate intubation protocols, endotracheal tube size, and adequate sedation are required [16]. In RTVL procedure with the indication of extubation failure, the most common pathology was intubation granuloma. It is especially seen in traumatic and/or oversized tube intubation. Another pathologic finding was intubation related subglottic stenosis[17]. Fifty-nine patients had intubation granuloma and 27 had subglottic stenosis in the current study. Subglottic stenosis was the third common cause of stridor [18]. Myer – Cotton staging system is used to stage subglottic stenosis. Grade 1 defines as narrowness to 50%, grade 2 is 51 to 70%, grade 3 is 71 to 99% and grade 4 defines total obstruction [2].

The most common examination finding was laryngomalacia. Laryngomalacia can be defined as collapsing of supraglottic structures towards glottis during inspiration [19]. Laryngomalacia could easily be observed in RTVL because respiration is not depressed and movements of laryngeal structures can be dynamically seen. Children with laryngomalacia show a high incidence of GERD (65%) and require anti-reflux treatment [20]. This rate was 40.1% in our study. It is the most common cause of stridor in neonates and children, accounting for 60-70% of cases [21]. Laryngomalacia is blamed 45 -75 % of children with stridor [22]. Laryngomalacia had less rate in the presented study. It could be related to excluding patients who can be performed FFL in the study group.

Vocal cord palsy consists 10-22% of all laryngeal diseases in children and is the second most common congenital laryngeal anomaly [23, 24]. Left sided unilateral cord palsy is more common [25, 26]. The cause of vocal cord palsy might be either idiopathic or iatrogenic - caused by surgical traumas like cardiac or neck surgery [27]. Unilateral vocal fold paralysis is considered the most common neurologic disorder of the larynx and is frequently caused by intubation or neonatal cardiothoracic surgery [28]. In this study, there were 10 left vocal cord palsy cases, 5 of which were after cardiac surgeries, which was compatible with literature. There were 9 children with bilateral vocal cord palsies. Two of them were idiopathic, 4 had metabolic diseases and 3 had neurological disturbances.

There were 67 children who underwent tracheotomy. While the most common indication was upper airway infections in the past; recently, in this study, the most common reason for tracheotomy was prolonged intubation with the rate of 76%. The mean time between the first intubation and tracheotomy was 24.13 days. Because of its possible complications, tracheotomy must be terminated as soon as possible. When a prolonged intubation requirement is assumed for a patient, tracheotomy must be applied without undue delay to avoid complications like subglottic stenosis.

Vocal nodules are the most common causes of chronic hoarseness in children. Among the 646 children Shah et al. [29] examined, 254 had vocal nodules. Their study demonstrated that vocal nodules are most commonly seen in boys especially between the ages 3-10. Interestingly, they presented 6 infants with vocal nodules (less than 7 months of age). They suggested that hyperfunction of the larynx correlates with nodule size while the presence of reflux disease does not correlate. The treatment and the evaluation of vocal nodules are based on a few principles: voice rest, speech therapy, treatment of reflux disease, and evaluation for other etiologies that result in nodules [30].

Laryngeal atresia is a rare and lethal upper airway anomaly. There are few reports in the literature related to this pathology. Fetus prenatally presents with hyperechogenic lungs, ascites or hydrops. Visualization of a dilated trachea distal to the obstruction is a direct diagnostic sign [31]. In our clinic, an urgent tracheotomy was applied to a newborn immediately after birth with a diagnosis of laryngeal atresia.

Epiglottic anomaly is another rare condition. Bifid epiglottis has been reported in the literature. It presents congenital stridor and may be associated with congenital syndromes like Pallister Hall Syndrome. Patients must also be investigated for associated hypothyroidism and hypothalamic

abnormalities. If respiratory distress is serious, malacic part of the anomalic epiglottis must be removed by sharp instrumentation or laser [32].

Laryngeal papilloma is one of the most common benign neoplasms in children. It is most commonly located on the true vocal cords but may also involve supraglottic or subglottic areas. It is suggested that a congenital transmission via the genitalia of the mother occurs in children with laryngeal papillomas [33]. There were 3 patients with laryngeal papillomatosis. One of them underwent a tracheotomy and 8 times laryngosurgery.

Conclusions: This study contributes the literature by evaluating a large case series with pediatric upper airway problems. RTVL is a valuable examination method to evaluate pediatric upper airway diseases with a minimal morbidity when flexible laryngoscopy cannot be performed and the patient is planned to have any type of airway surgery. With this method, laryngeal dynamics could be examined because it is performed without muscle relaxants. Stridor and prolonged intubation were the most common causes and laryngomalacia, subglottic stenosis were the most common findings of laryngeal diseases as consistent with the literature, in the presented study.

Author's Contribution:

I.K. ; Design, Main Thought, Performing the Procedures, Revising of the Final Manuscript

A.V. ; Design, Writing, Revising of the Final Manuscript

K.K.; Collection of Data, Analysis, Writing

M.I.Ş. ; Analysis, Revising of the Final Manuscript

Funding: None

Conflict of Interest: The authors declare no conflict of interest.

References

- 1.Haddad GG, Palazzo RM. Diagnostic Approach to Respiratory System. In: Kliegman RM, Stanton B, Geme JS, et al., editors. Nelson Textbook of Pediatrics. 19 ed: Elsevier; 2011.1378.
- 2.Myer 3rd C, O'connor D, Cotton R. Proposed grading system for subglottic stenosis based on endotracheal tube sizes. Ann Otol Rhinol Laryngol 1994;103:319-23.
- 3.Benjamin B. Technique of laryngoscopy. Int J Pediatr Otorhinolaryngol 1987 Oct;13:299-313.
- 4.Nussbaum E. Flexible fiberoptic bronchoscopy and laryngoscopy in infants and children. Laryngoscope 1983;93:1073-5.
- 5.Holinger LD. Diagnostic endoscopy of the pediatric airway. Laryngoscope 1989;99:346-8.
- 6.Handler SD. Direct laryngoscopy in children: rigid and flexible fiberoptic. Ear Nose Throat J 1995;74:100-4, 6.
- 7.Wood RE. Evaluation of the upper airway in children. Curr Opin Pediatr 2008;20:266-71.

- 8.Hagberg C A, C GJ. Operative Pediatric Airway Endoscopy and Microlaryngeal Surgery. In: Hagberg C A, C GJ, editors. Benumof and Hagberg's Airway Management. Houston, Texas: Elsevier; 2013;807-9.
- 9.Jaquet Y, Monnier P, Van Melle G, et al. Complications of different ventilation strategies in endoscopic laryngeal surgery: a 10-year review. *Anesthesiol* 2006;104:52-9.
- 10.Martins RH, Dias NH, Castilho EC, Trindade SH. Endoscopic findings in children with stridor. *Rev Brasileira Otorrinolaringol* 2006;72:649-53.
- 11.Contencin P, Narcy P. Size of endotracheal tube and neonatal acquired subglottic stenosis. Study Group for Neonatology and Pediatric Emergencies in the Parisian Area. *Arch Otolaryngol Head Neck Surg* 1993;119:815-9.
- 12.Holzki J, Laschat M, Stratmann C. Stridor in the neonate and infant. Implications for the paediatric anaesthetist. Prospective description of 155 patients with congenital and acquired stridor in early infancy. *Paediatr Anaesth* 1998;8:221-7.
- 13.Gupta P, Kuperstock JE, Hashmi S, et al. Efficacy and predictors of success of noninvasive ventilation for prevention of extubation failure in critically ill children with heart disease. *Pediatr Cardiol* 2013;34:964-77.
- 14.Edmunds S, Weiss I, Harrison R. Extubation failure in a large pediatric ICU population. *CHEST J* 2001;119:897-900.
- 15.Baisch SD, Wheeler WB, Kurachek SC, Cornfield DN. Extubation failure in pediatric intensive care incidence and outcomes. *Pediatr Critic Care Med* 2005;6:312-8.
- 16.Jang M, Basa K, Levi J. Risk factors for laryngeal trauma and granuloma formation in pediatric intubations. *Int J of Pediatr Otorhinolaryngol* 2018;107:45-52.
- 17.Weiss M, Dave M, Bailey M, et al. Endoscopic airway findings in children with or without prior endotracheal intubation. *Paediatr Anaesth* 2013;23:103-10.
- 18.Choo K, Tan H, Balakrishnan A. Subglottic stenosis in infants and children. *Singapore Med J*. 2010;51:848-52.
- 19.Landry AM, Thompson DM. Laryngomalacia: disease presentation, spectrum, and management. *Int J Pediatr* 2012;:753526.
- 20.Thompson DM. Laryngomalacia: factors that influence disease severity and outcomes of management. *Curr Opin Otolaryngol Head Neck Surg* 2010;18:564-70.
- 21.Daniel SJ. The upper airway: congenital malformations. *Paediatr Resp Rev* 2006;7:260-S3.
- 22.Friedman EM, Vastola AP, McGill TJ, Healy GB. Chronic pediatric stridor: etiology and outcome. *The Laryngoscope* 1990;100:277-80.
- 23.Brigger MT, Hartnick CJ. Surgery for pediatric vocal cord paralysis: a meta-analysis. *Otolaryngol Head Neck Surg* 2002 126:349-55.
- 24.Daya H, Hosni A, Bejar-Solar I, Evans JN, Bailey CM. Pediatric vocal fold paralysis: a long-term retrospective study. *Arch Otolaryngol Head Neck Surg* 2000;126:21-5.

25. Truong MT, Messner AH, Kerschner JE, et al. Pediatric vocal fold paralysis after cardiac surgery: rate of recovery and sequelae. *Otolaryngol Head Neck Surg* 2007;137:780-4.
26. Bent J. Pediatric laryngotracheal obstruction: current perspectives on stridor. *Laryngoscope* 2006;116:1059-70.
27. Garcia-Lopez I, Penorrocha-Teres J, Perez-Ortin M, et al. Paediatric vocal fold paralysis. *Acta Otorrinolaringol Esp* 201;64:283-8.
28. Irace AL, Dombrowski ND, Kawai K, et al. Aspiration in children with unilateral vocal fold paralysis. *The Laryngoscope* 2019;129:569-73.
29. Shah RK, Woodnorth GH, Glynn A, Nuss RC. Pediatric vocal nodules: correlation with perceptual voice analysis. *Int J Pediatr Otorhinolaryngol.* 2005;69:903-9.
30. Zeitels SM, Healy GB. Laryngology and phonosurgery. *N Engl J Med* 2003;349:882-92.
31. Bui T-H, Grunewald C, Frenckner B, et al. Successful EXIT (ex utero intrapartum treatment) procedure in a fetus diagnosed prenatally with congenital high-airway obstruction syndrome due to laryngeal atresia. *Europ J Pediatr Surg: official journal of Austrian Association of Pediatric Surgery Zeitschrift fur Kinderchirurgie* 2000;10:328-33.
32. Wiatrak BJ. Congenital anomalies of the larynx and trachea. *Otolaryngol Clin North Am* 2000;33:91-110.
33. Abramson AL, Steinberg BM, Winkler B. Laryngeal papillomatosis: clinical, histopathologic and molecular studies. *Laryngoscope* 1987;97:678-85.