



# Successful Surgical Removal of a Large Pedunculated Apical Thrombus without Any Embolic Events

## Büyük Saplı Apikal Yerleşimli Trombüsün Embolik Olay Olmaksızın Başarılı Bir Şekilde Cerrahi Olarak Çıkarılması

Ersin Çağrı Şimşek<sup>1</sup>, Hakan Köksal<sup>2</sup>

<sup>1</sup> University of Health Sciences, Tepecik Training and Research Hospital, Clinic of Cardiology, İzmir, Turkey

<sup>2</sup> University of Health Sciences, Tepecik Training and Research Hospital, Clinic of Cardiovascular Surgery, İzmir, Turkey

Left ventricular (LV) thrombus, a feared complication of severe LV dysfunction, is usually located in left ventricular apical aneurysm<sup>(1)</sup>. Protrusion and mobility of thrombi have a high risk of recurrent embolic strokes than mural thrombi<sup>(2)</sup>. A 67-year-old male newly diagnosed with ischemic dilated cardiomyopathy was admitted to our hospital with severe dyspnea and pulmonary edema. Echocardiography on admission revealed an LVEF of 20%-25%; global hypokinesis with apical akinesis; and a large, mobile apical thrombus measuring 50 mm x 20 mm (Figure 1). Intravenous (IV) unfractionated heparin, IV diuretics, and non-invasive mechanical ventilation were initiated to relieve symptoms and minimize embolic risk. Before the treatment options were discussed within the heart team, coronary angiography was performed that revealed two vessels indicating coronary artery disease with stenosis of the left anterior descending (LAD) and first diagonal (D1) coronary arteries. Because a thrombus carries a high risk of embolization, emergency open-heart surgery was planned via a median sternotomy. The fragile thrombus of about 5 cm in diameter attached to the apex was completely resected, and the left internal mammary artery and a saphenous vein graft were anastomosed to the LAD and D1 coronary arteries, respectively. Postoperative transthoracic echocardiogram showed no evidence of a residual thrombus with an ejection fraction of 25% (Figure 2). Following the postoperative course, the patient was discharged uneventfully with the administration of warfarin, metoprolol, and ramipril on the sixth day.

*Cite this article as: Şimşek EÇ, Köksal H. Successful surgical removal of a large pedunculated apical thrombus without any embolic events. Koşuyolu Heart J 2019;22(2):137-8.*

### Correspondence

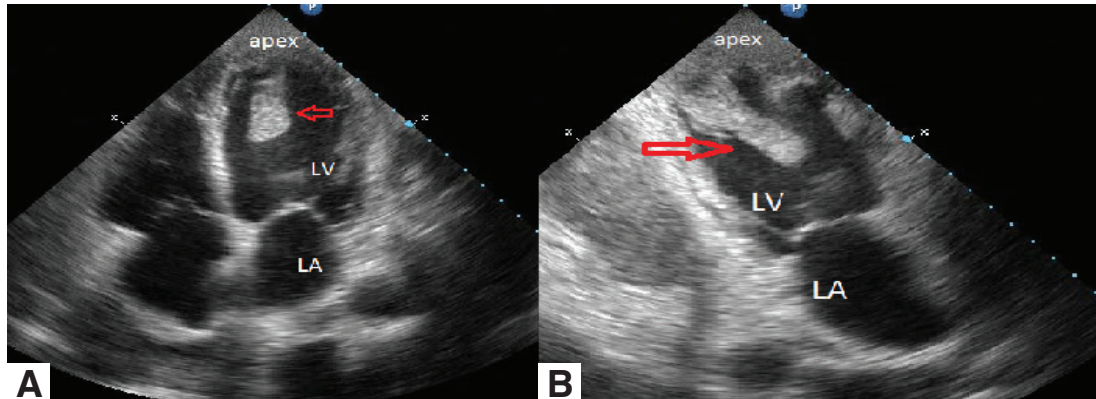
Ersin Çağrı Şimşek

E-mail: ercagsim@hotmail.com

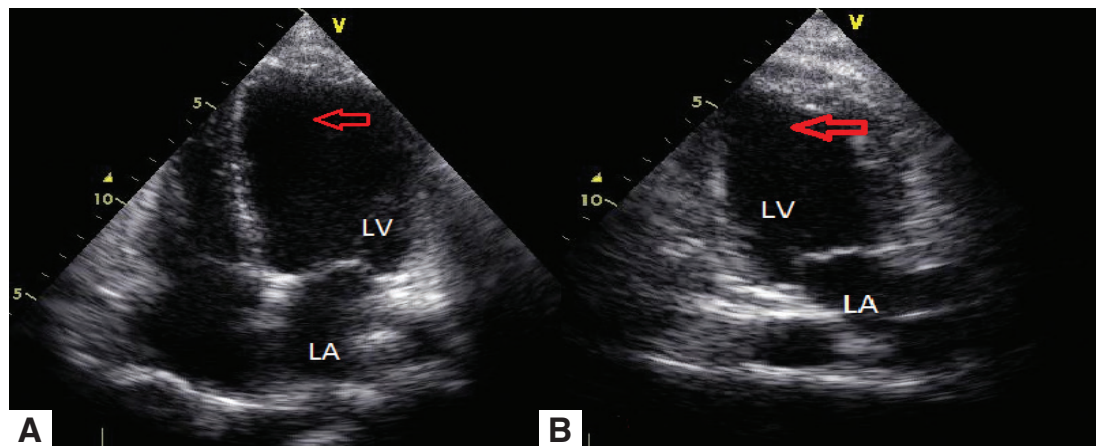
Submitted: 10.01.2019

Accepted: 17.02.2019

© Copyright 2019 by Koşuyolu Heart Journal. Available on-line at [www.kosuyoluheartjournal.com](http://www.kosuyoluheartjournal.com)



**Figure 1.** (A) Apical 4-chamber and (B) apical 2-chamber views following transthoracic echocardiography showing an apical thrombus (arrow) measuring 50 mm x 20 mm.  
LA: Left atrium, LV: Left ventricle.



**Figure 2.** (A) Apical 4-chamber and (B) apical 2-chamber views following postoperative transthoracic echocardiography demonstrating no evidence of a residual thrombus.  
LA: Left atrium; LV: Left ventricle.

## REFERENCES

1. Chiarella F, Santoro E, Domenicucci S, Maggioni A, Vecchio C. Pre-discharge two-dimensional echocardiographic evaluation of left ventricular thrombosis after acute myocardial infarction in the GISSI-3 study. *Am J Cardiol* 1998;81:822-7.
2. Johannessen KA, Nordrehaug JE, von der Lippe G, Vollset SE. Risk factors for embolisation in patients with left ventricular thrombi and acute myocardial infarction. *Br Heart J* 1988;60:104-10.