




■ Case Report

Metastasis of lung cancer in jugular foramen: a case report

Jugular foramende akciğer kanseri metastazı: olgu sunumu

Meltem Özdemir ¹ , Aynur Turan ^{1*} , Önder Eraslan ¹ 

¹ Dışkapı Yıldırım Beyazıt Training and Research Hospital, Department of Radiology, Ankara, Turkey

* Corresponding author: Aynur Turan E-mail: aturanrad@gmail.com ORCID: 0000-0001-6654-3129

Received: 19 July 2018 Accepted: 15 October 2018

ABSTRACT

Jugular foramen tumors are uncommon cranial base lesions that cause difficulties not only in diagnosis but in treatment as well. Paraganglioma is the most common tumor involving this region. Other common tumors arising in the jugular foramen are meningiomas, schwannomas and chondrosarcomas. Metastatic involvement of this location is rare. We present a case of metastasis of lung adenocarcinoma in jugular foramen presented with cranial neuropathy. Although it is rare, metastasis of a systemic malignancy should always be considered in the differential diagnosis of a mass involving jugular foramen.

Keywords: Jugular foramen tumor, jugular foramen metastasis, lung cancer

ÖZ

Jugular foramen tümörleri, sadece tanı için değil aynı zamanda tedavide de zorluklara neden olan nadir kafa tabanı lezyonlardır. Paraganglioma bu bölgede görülen en yaygın tümördür. Jugular foramende diğer sık görülen tümörler meningioma, schwannoma ve kondrosarkomlardır. Bu bölgenin metastatik tutulumu nadirdir. Burada kraniyal sinir tutulumu ile başvuran juguler foramende akciğer adenokarsinomu metastazı olgusu sunulmaktadır. Nadir olmasına rağmen, sistemik bir malignitenin metastazı her zaman juguler foramen kitlelerinin ayırıcı tanısında düşünülmelidir.

Anahtar kelimeler: Jugular foramen tümörü, jugular foramen metastazı, akciğer kanseri

BACKGROUND

Jugular foramen tumors are rare cranial base lesions which cause difficulties not only in diagnosis but in treatment as well. Paraganglioma is the most common tumor involving this region. Other common tumors arising in the jugular foramen are meningiomas, schwannomas, and chondrosarcomas. Metastatic involvement of this location is rare [1]. We report a case of a lung cancer metastasis in jugular foramen who presented with a cranial neuropathy.

CASE REPORT

A 56-year-old woman who has been under the follow-up for a surgically treated primary lung adenocarcinoma for 6 years, admitted to the Department of Otorhinolaryngology suffering from hoarseness and a pharyngeal pain of 1 week. On examination, she was noted to have a right vocal cord paresis. Computerized tomography (CT) of thorax showed

no remarkable change compared to her prior examination. CT of neck revealed a right vocal cord paresis (**Figure 1**). Contrast-enhanced neck CT demonstrated a well defined, diffusely enhancing skull base mass involving the right jugular foramen and extending extracranially (**Figure 2**). The jugular spine was well delineated and no evidence of bone erosion in either the right jugular foramen or the neighboring bone structures was noted. The right jugular vein was displaced posterolaterally (**Figure 3**). On magnetic resonance imaging (MRI), the mass was; 3.3x1.4x1.1 cm on size, showed high signal on T2 weighted images and was diffusely enhancing on gadolinium enhanced sequences. There was no evidence of vascular infiltration on MRI (**Figure 4**). On 18-fluoro deoxyglucose (FDG) positron emission tomography (PET) scan, the mass revealed high positive FDG

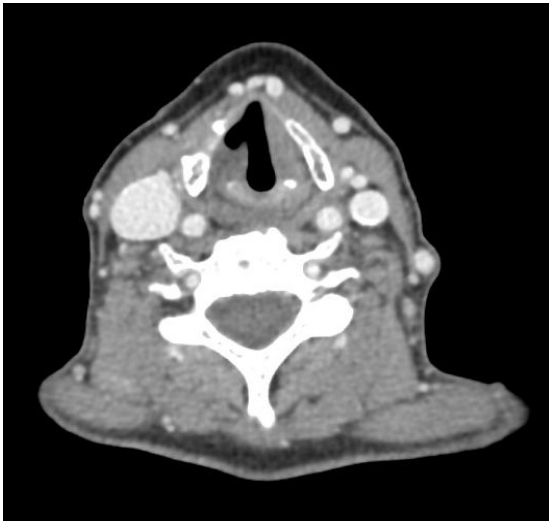


Figure 1. Axial contrast-enhanced computerized axial tomography image through larynx shows a right vocal cord paresis

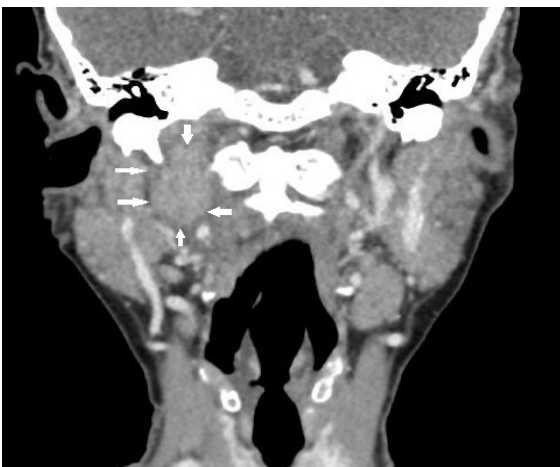


Figure 2. Coronal contrast-enhanced computerized axial tomography image demonstrates a relatively well defined, lobulated, diffusely enhancing mass involving the right jugular foramen (white arrows). Note the extracranial extension of the mass

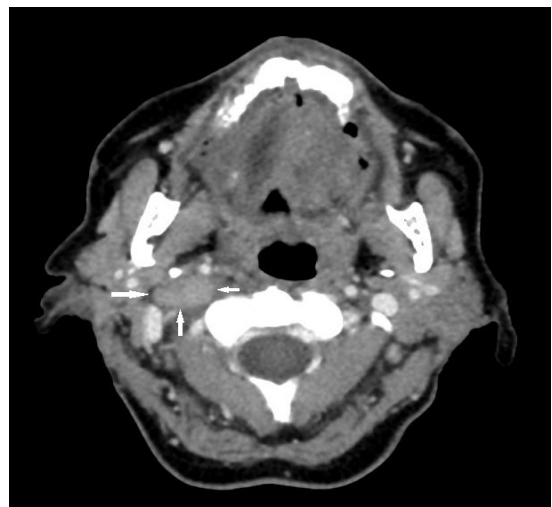


Figure 3. Axial contrast-enhanced computerized axial tomography image shows that the right jugular vein is displaced posterolaterally by the mass involving the right jugular foramen (white arrows)

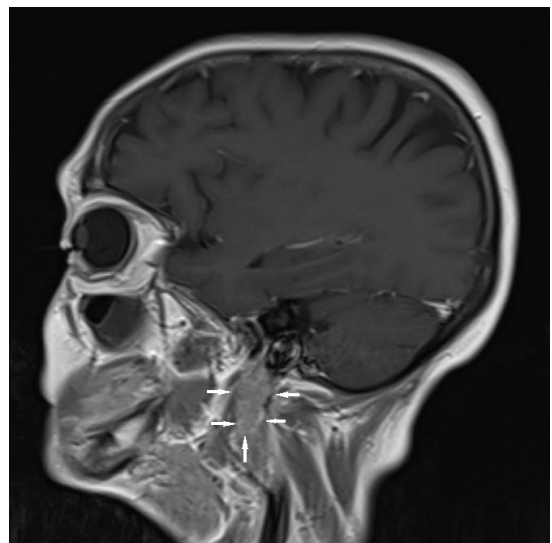


Figure 4. Sagittal contrast-enhanced T1 weighted magnetic resonance image shows a well defined, lobulated, diffusely enhancing mass of the right jugular foramen with an extracranial extension (white arrows)

uptake and diagnosed as metastasis. Chemotherapy in conjunction with radiation therapy was planned for the treatment of the patient. She rejected chemotherapy. The patient was then transferred to the Department of Radiation Oncology and an external-beam radiation therapy was planned.

DISCUSSION

Metastatic involvement of cranial base is seen in only 4% of patients with systemic malignancies. The breast, lung, and prostate malignancies are shown to have a tendency to metastasize to the structures of cranial base [2]. Being only 3.5% of all cranial base metastases, jugular foramen involvement is very uncommon among the other cranial base structures [3].

The presenting symptoms of jugular foramen metastases are; hoarseness, dysphagia, and pain in the occipital and pharyngeal regions, as in the present case. Neurological examination reveals involvement of the last four cranial nerves (IX- XII), occasionally associated with Horner's syndrome [2]. A similar clinical presentation may be the result of a large number of lesions, so the differential diagnosis of a jugular foramen tumor may be very difficult. This is true especially in the cases without a previous cancer diagnosis. Radiological assessment plays a critical role in both accurate diagnosis and management [4-8]. The identification of most lesions can be made by combination of CT and MRI [9].

The evaluation of bone structures in cases of meningiomas, aneurysmatic bone cysts, and chondrosarcomas is made by CT. It is also the choice of imaging modality in demonstrating hyperostosis and tumor calcification. Gadolinium enhanced MRI clearly demonstrates the morphology and extension of the tumor, its vascularization and its relationship with other structures. If needed, MR angiography and/or digital subtraction angiography (DSA) may be performed to show the tumor vascularization and venous circulation. Paragangliomas are highly vascularized lesions that show heterogeneous contrast enhancement. Schwannomas are also strongly enhancing masses which present a regular contour, cystic appearance in some cases, and occasionally "hour glass" shape. Meningiomas may show dural tail, hyperostosis, and characteristic "sunburst" appearance following gadolinium administration. Chondrosarcomas are destructive masses with irregular contours, showing heterogeneous contrast enhancement [1,9]. Metastases at the jugular foramen and at other regions of the skull base classically present as lytic lesions [9-13]. In the present case, imaging findings of the mass were not

typical of a metastasis. There was neither bone destruction nor soft tissue infiltration. In contrast to most of the previously reported cases, it was a homogeneously enhancing, well defined, lobulated mass which is consistent with a benign lesion rather than a metastasis. However, sudden onset of the symptoms and the known primary lung malignancy of the patient were taken into account and the final diagnosis was a metastasis. In the cases of jugular foramen involvement, surgical resection has the potential risks of; cerebrovascular morbidity, meningitis, cerebrospinal fluid leakage, and additional cranial nerve deficits. Conformal fractionated radiation therapy to the region of involvement and control of the systemic malignancy with chemotherapy are shown to be the best choices of treatment for most cases [2]. For primary management or for the treatment of residual and recurrent skull base metastases following surgery or radiotherapy, stereotactic radiosurgery is a minimally invasive palliative option. The prognosis for skull base metastases is poor, with a median survival of about 1 year [11].

Although it is rare, metastasis of a systemic malignancy should always be considered in the differential diagnosis of a mass involving jugular foramen.

DECLARATION OF CONFLICT OF INTEREST

There is no conflict of interest concerning this manuscript.

REFERENCES

1. Ramina R, Maniglia JJ, Fernandes YB et al. Tumors of the jugular foramen: Diagnosis and management. *Neurosurgery* 2005; 57: 59-68.
2. Hayward D, Morgan C, Emami B, et al. Jugular foramen syndrome as initial presentation of metastatic lung cancer. *J Neurol Surg Rep* 2012; 73:14-8.
3. Laigle-Donadey F, Taillibert S, Martin-Duverneuil N, et al. Skull-base metastases. *J Neurooncol* 2005; 75: 63-9.
4. Vogl TJ, Bistas S. Differential diagnosis of jugular foramen lesions. *Skull Base* 2009; 19: 3-16.
5. Robbins KT, Fenton RS. Jugular foramen syndrome. *J Otolaryngol* 1980; 9: 505-16.
6. Biller J, Brazis PW, Masdeu JC. *Localization in Clinical Neurology*. Hagerstown, MD: Lippincott Williams and Wilkins; 2011.
7. Shine NP, O'Sullivan P. Collet-Sicard syndrome: a rare presentation of metastatic prostate adenocarcinoma. *Auris Nasus Larynx* 2005; 32: 315-8.

8. Agarwal A, Baisakhiya N, Kakani A, et al. Metastatic lung cancer presenting with a jugular foramen syndrome in a case of von Recklinghausens disease. *J Cancer Res Ther* 2010; 6: 391-3.
9. Lowenheim H, Koerbel A, Ebner FH, et al. Differentiating imaging findings in primary and secondary tumors of the jugular foramen. *Neurosurg Rev* 2006; 29: 1-1.
10. Bourlon MT, Glode LM, Crawford ED. Base of the skull metastases in metastatic castration-resistant prostatic cancer. *Oncology*, Dec 15, 2014. Published on Cancer Network (<http://www.cancernetwork.com>)
11. Mitsuya K, Nakasu Y. Metastatic Skull Tumors: Diagnosis and management. *Eur Assoc Neurooncol Mag* 2014; 4: 71-4.
12. Kaloostian PE, Chen H, Stippler M. Case report: Uterine adenocarcinoma metastasis to the skull base and cervical spine presenting with pathological fracture and myelopathy. *OJMN* 2013; 3: 33-5.
13. Çetinalp NE, Divanlıoğlu D, Yıldırım AE, Belen AD. Juguler foramen sendromu ile prezente olan kafa tabanının adenokarsinom metastazı: bir olgu sunumu. *Türk Nöroşirürji Dergisi* 2013; 23: 319-22.

