

The Role of Arthroscopic Decompression in Subacromial Impingement Syndrome

Subakromiyal Sıkışma Sendromunda Artroskopik Tedavinin Yeri

Aziz Atik^{1*}

1.Balıkesir University Medical Faculty, Department of Orthopaedics and Traumatology, Balıkesir, Turkey

ABSTRACT

Aim: The aim of this study was to evaluate the clinical results of patients who had arthroscopic subacromial decompression for the diagnosis of subacromial impingement syndrome which is characterized by compression of the coracoacromial arc on rotator cuff tendons.

Patients and Methods: We have evaluated the Constant scores, rest VAS and motion VAS scores of 25 patients who had arthroscopic subacromial decompression after six months of failed conservative treatment, at the preoperative day, 15th day and 6th month after the operation.

Results: There was a statistically significant difference between pre-operative and 15th day / 6th month scores with Mann Whitney U test ($p < 0.0001$). We found that the patients' pain decreased and shoulder functions improved statistically.

Conclusion: We believe that the choice of treatment for early stages of subacromial impingement syndrome is conservative, but if complaints persist even six months after conservative treatment, then arthroscopic subacromial decompression is a good choice of treatment.

Keywords: shoulder, rotator cuff, subacromial impingement syndrome, arthroscopic decompression

ÖZ

Amaç: Bu çalışmanın amacı, rotator manşet tendonları üzerine korakoakromiyal arkın basısı ile karakterize subakromiyal sıkışma sendromu tanısı ile artroskopik subakromiyal dekompresyon yapılan hastaların klinik sonuçlarını değerlendirmektir.

Hastalar veYöntem: En az altı ay konservatif tedavi uygulamalarından fayda görmeyen ve artroskopik subakromiyal dekompresyon uyguladığımız 25 hastanın, tedavi öncesi ve cerrahi sonrası 15. gün ve 6. aydaki Constant, istirahat VAS ve hareket VAS skorlarını değerlendirdik.

Bulgular: Ameliyat öncesi ve 15. gün / 6. ay skorları arasında Mann Whitney U testi ile istatistiksel olarak anlamlı bir fark vardı ($p < 0.0001$). Hastaların ağrılarının azaldığını ve omuz fonksiyonlarında iyileşme olduğunu istatistiksel olarak tespit ettik.

Sonuç: Erken evre subakromiyal sıkışma sendromunun tedavisinin konservatif olduğu; ancak, 6 ay konservatif tedaviye rağmen şikayetleri devam eden hastalarda artroskopik subakromiyal dekompresyonun iyi bir tedavi seçeneği olduğu kanaatindeyiz.

Anahtar kelimeler: omuz, rotator manşet, subakromiyal sıkışma sendromu, artroskopik dekompresyon

Received Date: 18.05.2019 Accepted Date: 30.07.2019 Published (Online) Date:26.10.2019

*Corresponding author: Aziz Atik, MD, Department of Orthopaedics and Traumatology, Balıkesir University Medical Faculty, Balıkesir, Turkey E-mail: azizatik@yahoo.com Phone :+90-532-465-1743

ORCID: 0000-0002-2125-6465

INTRODUCTION

The shoulder joint is the joint with the widest movement in the body. Shoulder pain is the second most common after low back pain. One of the most common causes of shoulder pain is rotator cuff lesions. The incidence of rotator cuff tendinitis is 0,32-0,42% among normal population. The reported reason of 95% of rotator cuff lesions is subacromial impingement syndrome (SAIS). SAIS is a syndrome characterized by compression of the coracoacromial (CA) arc on rotator cuff tendons and presents with pain in the flexion, abduction and external rotation. Pathology is located on the anterior surface of the 1/3 anterior part of the acromion; and at the anterior edge, coracoacromial ligament and acromioclavicular (AC) joint. However, degenerative changes in the rotator cuff especially in the supraspinatus tendon may cause impingement due to muscle imbalance (intrinsic factors) [1,2].

The general health status, age, motivation, daily living habits, stage of the disease, and occupation should be taken into consideration when deciding treatment modalities. Stage 1 and 2 impingement syndrome may respond to conservative treatment methods such as exercise, NSAID drugs, subacromial corticosteroid injections. Surgical interventions should be considered for stage 2-3 lesions which do not respond to conservative treatment. Several arthroscopic and open methods have been described to decompress the mechanical load of acromion over rotator cuff. Arthroscopic subacromial decompression (ASD) was first described by Ellman in 1987 and was proposed as an alternative to open surgery. And recently Ellman's article was reinvestigated again and proved its reliability over past thirty years [1].

In this study we aimed to investigate the results of ASD in patients who did not favor conservative treatment at least for six months. The exact etiology of this syndrome is still being discussed and reasons and treatment modalities may present differences. The complex biomechanics of subacromial region is still a source for many authors' researches. We hypothesized that ASD would be a good choice for selective patients.

PATIENTS and METHOD

Twenty-five patients who underwent conservative treatment for 6 months with the diagnosis of SAIS and then underwent ASD because of ongoing symptoms, were included in the study after signing informed consent forms and local ethical committee approval.

Shoulder anteroposterior and supraspinatus outlet graphics were investigated as well as MRI. Patients with rotator cuff tears requiring surgical repair, patients with connective tissue diseases, patients who had previously undergone shoulder surgery were excluded from the study.

All examinations, tests and evaluations were carried out by the same physician for the standardisation of the findings. In the first part; demographic data related to the patients were recorded and physical examinations were performed. To evaluate the effects of the pathology defined by the patient on the activities of daily living; Constant Murley scoring, motion Visual Analogue Scale (VAS), and resting VAS scores were recorded.

The patients were hospitalized the day before surgery. All patients were applied a single dose i.v. antibiotic prophylaxis the night before the operation and one single dose immediately after the operation (1000 mg cefazolin sodium).

All surgeries were performed in beach-chair position, under general anesthesia by placing a supporting neck collar on the patient's neck. Anatomic structures and portals were drawn following sterile dressing (Figure 1).

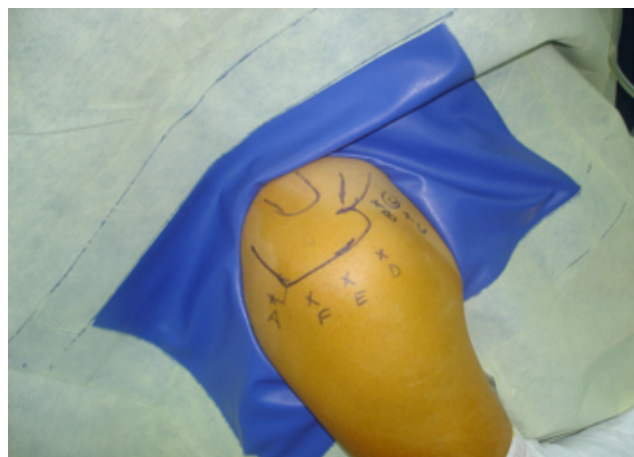

Figure 1. Portals for Shoulder Arthroscopy

After debridement of bursae, the rotator cuff muscles were checked for rupture or degeneration. Bony decompression was performed from inferior surface of the acromion until it was seen as adequate by using a standard acrominizer. After decompression, the shoulder was controlled under direct vision by moving each direction to determine whether the decompression was sufficient and whether there was a compressive surface.

The day after the operation, shoulder movement was initiated by the same physiotherapist with the continuous passive motion device. Anesthetic agent was applied from a catheter in order to eliminate pain and give full movement in the earlier period. Nonsteroid anti-inflammatory drug was started (Meloxicam 15 mg.) before patients were discharged and physiotherapy was ordered.

Constant-Murley, motion VAS and rest VAS scores were repeated and recorded by the same physician who performed the first tests during the control examination in the 15th day and 6th month after the operation. That's because we compared two sample means that came from the same population, and looked for whether two sample means were equal or they had differences; all statistical data was analysed with non-parametric Mann Whitney U test by using SPSS program (SPSS for Windows, Version 16.0. Chicago, SPSS Inc).

RESULTS

16 patients (64%) were female and 9 (36%) were male. The mean age was 56 (24-68). The right upper extremity was dominant in 22 (88%) of the cases and the left upper extremity was dominant in 3 (12%); and 17 patients (68%) had right and 8 patients (32%) had left SAIS. 5 (%20) had SAIS on nondominat extremity. None of the patients had previous operation history on the operated shoulder, but 1 had contralateral shoulder ASD in another facility. The mean duration of complaints was 15.3 months (6-48 months). 14 of 25 patients had type 2, 9 had type 1 and 2 had type 3 acromion. In 11 of the patients, AC arthrosis findings were observed. Besides eight patients had presented early stage GH arthrosis.

The mean preoperative Constant score was 39.8. This became 73.9 at the 15th day, and 75 at the 6th month (Figure 2). There was a significant dif-

ference between pre-operative and 15th day / 6th month Constant scores. The difference was statistically significant ($p < 0.0001$). There was no statistically significant difference between the Constant scores on the 15th day and 6th month postoperatively ($p = 0.930$). Patients' shoulder functions and daily activities had improved early postoperative and lasted for six months.

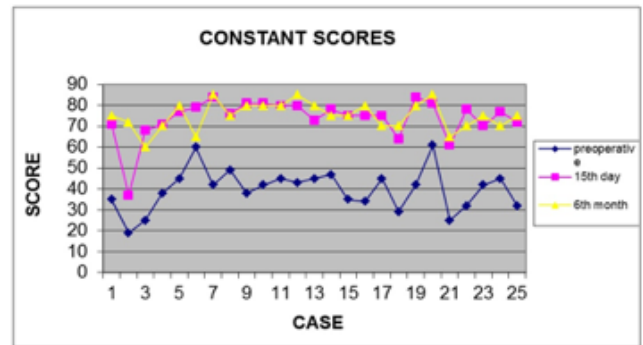


Figure 2. Constant Scores

Table 1: Statistical Analysis of the Patients (Mann Whitney U Test)

	Pre-operative	15th day	6th month	Significance preop-15th day	Significance preop-6th month	Significance 15th day-6th month
Rest VAS	6.6 ± 1.2sd	1.6 ± 0.9sd	1.7 ± 1.3sd	$p < 0.0001$	$p < 0.0001$	$p > 0.05$ ($p = 0.976$)
Motion VAS	8.0 ± 0.9sd	2.9 ± 1.1sd	2.7 ± 1.6sd	$p < 0.0001$	$p < 0.0001$	$p > 0.05$ ($p = 0.261$)
Constant	39.8 ± 9.9sd	73.9 ± 9.6sd	75.0 ± 6.5sd	$p < 0.0001$	$p < 0.0001$	$p > 0.05$ ($p = 0.930$)

The mean preoperative rest VAS score was 6.6. This became 1.6 at the 15th day, and 1.7 at the 6th month (Figure 3). There was a statistically significant difference between pre-operative and 15th day / 6th month rest VAS scores ($p < 0.0001$). However there was no statistically significant difference between the rest VAS scores on the 15th day and 6th month postoperatively ($p = 0.976$). Patients' pain had decreased early postoperative and lasted for six months.

The mean preoperative motion VAS score was 8.08. This became 2.9 at the 15th day, and 2.7 at the 6th month (Figure 2). There was a statistically significant difference between pre-operative and 15th day / 6th month motion VAS scores ($p < 0.0001$). However there was no statistically significant difference between the motion VAS scores

res on the 15th day and 6th month postoperatively ($p = 0.261$). Patients' pain during movement decreased in early postoperative period and this reduction was maintained for six months. Therefore the motion p value was smaller than the resting p value, it made us think that more pain may be felt in motion than in the rest. All statistical data was summarized in Figure 3.

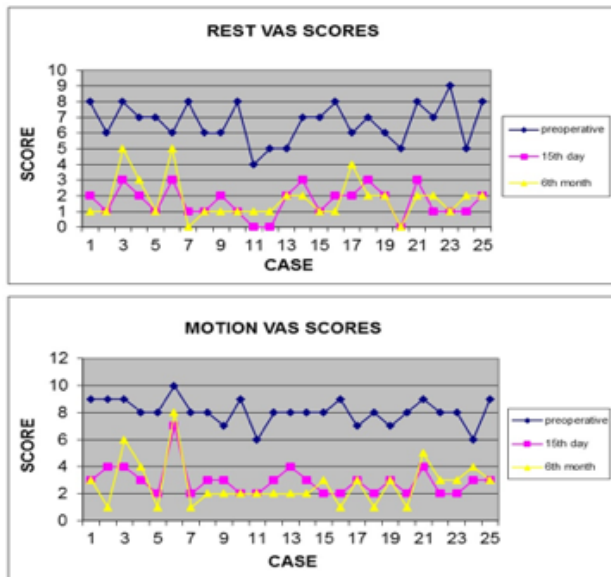


Figure 3. Rest and Motion VAS Scores

DISCUSSION

In the majority of our patients, the right upper extremity was dominant (88%) and SAIS was most common in the right shoulder (68%). The main reason for this is more usage of the right arm in daily work that facilitates wear and degenerative process. However, not all the patients with dominancy in right upper extremity showed impingement in the right shoulder, which may be the reflection of the intrinsic factors.

We have seen type 1 and type 2 acromions more common in our study. Schippinger et al. reported an MRI study on 31 normal shoulders of 29 patients between 24 and 36 years of age (mean 31), and no type 3 acromion was detected in their study. In this study, it was assumed that type 3 acromion was not seen in normal population, so it is an acquired type which was caused by an overgrowth on the inferior surface of the anterior acromion due to chronic upward irritation of the humeral head [3]. Ozaki et al. thought that acromial morphology was subsequently acquired due

to rotator cuff tear [4]. Hirano et al. found type 1 acromion in 33 patients (36.3%), type 2 in 22 patients (24.1%), and type 3 in 36 patients (39.5%) of the 91 shoulders with full-thickness rotator cuff tears. They concluded that there was a relationship between the size of the rotator cuff tear and the shape of the acromion, but there was not a strong relationship, as described in the literature, between the acromion shape and the incidence of rotator cuff tear [5]. Shah et al. examined the acromion both macroscopically and microscopically and found degenerative changes in collagen, fibrocartilage and bony tissue in all of the type 2 and type 3 acromions. They thought that different acromion shapes developed due to the traction of CA ligament [6]. We saw just two type 3 acromions in our study.

One of the two mechanisms that may jeopardize the supraspinatus blood flow is the tendon tension due to glenohumeral joint adduction, and the other is the disruption of rotator cuff microcirculation due to the increase in subacromial pressure. The critical zone, which was described by Codman in 1934, is more prone to degeneration.

While the subacromial pressure is 8 mmHg in the normal resting position, it may increase to 39 mmHg at 45° flexion and 56 mmHg when 1 kg weight was held. Although Lewis stated that the body posture doesn't have any effect on SAIS etiology [7], Hagiwara et al. reported that the anterior acromion would compress the subacromial bursa or supraspinatus tendon during arm elevation in forward head posture [8]. However, since the shoulder moves frequently, it remains unclear which of these mechanisms is effective enough to cause tendon ischemia. That's why we also saw increased pain during elevation.

After their microradiographic and histological examinations inside the supraspinatus tendon in the Codman critical zone; Moseley and Goldie reported that the osseous side of the stump was fed by the anterior circumflex branch of the humeral artery, while the tendinous side was fed by the subscapular and suprascapular arteries which formed an anastomosis site where they thought was the real critical zone [9]. We did not include patients with rotator cuff tears in our study. However, in the other surgeries we performed repair, we also

observed lesions in that critical area.

According to Ko et al. articular-side lesions are mostly caused by intrinsic pathologies with less pathological changes in the acromion and worse Zlatkin scores; whereas bursal-side lesions are mostly formed by subacromial compression with more prevalent AC arthrosis [10]. Early degenerative changes in GH joint may mimic SAIS. Guntern et al. found cartilage lesions in the GH joint in 1/3 of the patients who underwent MR arthrography due to impingement syndrome [11]. Petersson et al. reported that the cartilage pathologies of GH joint and rotator cuff lesions coincided 75% in their autopsy study [12]. We found early stage GH arthrosis in 8 of our patients.

Singh et al. described a scoring system to preoperatively estimate possible benefit after ASD [13]. Watson claimed that the postoperative results of preoperative steroid injected patients would be worse after surgery [14]. Whereas the steroids may stimulate apoptosis in some cells, some authors believe they do not induce apoptosis in fibroblasts [15]. Yıldız et al. reported no correlation between repeated steroid injections and postoperative results [16]. We also utilized subacromial steroid injection once during conservative treatment period.

After publishing first successful results about ASD by Ellman, many successful series have also been reported. Roye et al. reported 80-90% satisfactory results with ASD, Brox et al. stated that surgery should be recommended if conservative treatment does not improve symptoms for 6 months, and in their study they reported better results with ASD than physiotherapy with Neer scores in 2,5 years follow-up of 125 patients [17]. Karaman et al. advised ASD for better results instead of open decompression [18]. Recently a multicenter Lancet study approved better results with surgery than without treatment [19].

Bouchard et al. prescribed some factors for any fail of ASD surgery [20]. We believe there is a much greater chance of success in a decompression performed with meticulous attention to anatomy by placing markers for particular regions (such as a needle inserted in AC joint). Bhattacharyya et al. also reported good outcomes after ASD with Constant and Oxford scores in 6 months [21].

In a recent study, Farfaras et al. reported better results with ASD in their 10-year follow-up study [22]. Furthermore, Lerch et al. reported successful results in a 20-year follow-up study with ASD [23]. Jaeger et al. showed good clinical outcomes after 20 years of ASD even in presence of a rotator cuff tear [24].

Arthroscopic treatment is not only less invasive, but also offers the opportunity to observe normal anatomy better in some areas. To our experience, particularly in a multifactorial disease like SAIS, it is more appropriate to follow the patient's native anatomy without disturbing the environment, and to determine the treatment of choice. Our results are similar to the series given in the literature, all of our patients in all of our research parameters, showed improvement when compared to preoperative values.

This present study has certain limitations; such as short follow-up time, small number of patients, but nevertheless their return to painless, daily life quickly encourages us to the effectiveness of the treatment we prefer.

Conclusion: We believe that first treatment choice for SAIS is conservative modalities; however, in our study we found ASD is a useful and selective treatment modality in patients who have not improved for at least six months despite conservative treatment.

Funding sources: The author declared no financial support for this study.

Conflict of Interest: No conflict of interest was declared by the author.

Acknowledgements: This study was derived from the thesis of "speciality in medicine" of the author. The author would like to thank to Prof. Dr. Servet Tunay and Prof. Dr. Mahmut Kömürcü for their constructive support in establishing this study.

REFERENCES

1. Oates KM. Re: Arthroscopic subacromial decompression: analysis of one- to three-year results. *Arthroscopy: J Arthrosc & Relat Surg.* 2010;26(1):104. DOI: 10.1016/j.arthro.2009.10.003
2. Özsoy MH, Fakioğlu O, Aydoğan NH. Subakromiyal sıkışma sendromu. *TOTBİD Dergisi* 2013; vv:340–352 doi: 10.14292/totbid.dergisi.2013.42
3. Schippinger G, Bailey D, McNally EG, Kiss J, Carr AJ. Anatomy of the normal acromion investigated using MRI. *Langenbecks*

- Archiv für Chirurgie. 1997;382(3):141-4. PMID: 9239637
4. Ozaki J, Fujimoto S, Nakagawa Y, Masuhara K, Tamai S, Tears of the rotator cuff of the shoulder associated with pathological changes in the acromion. A study in cadavera. J Bone Joint Surg Am, 1988;70(8): 1224-30 PMID: 3417708
 5. Hirano M, Ide J, Takagi K, Acromial shapes and extension of rotator cuff tears: magnetic resonance imaging evaluation. J Shoulder Elbow Surg, 2002; 11(6):576-8. DOI: 10.1067/mse.2002.127097
 6. Shah NN, Bayliss NC, Malcolm A, Shape of the acromion: congenital or acquired-a macroscopic, radiographic, and microscopic study of acromion. J Shoulder Elbow Surg, 2001;10(4):309-16 DOI: 10.1067/mse.2001.114681
 7. Lewis JS, Green A, Wright C, Subacromial impingement syndrome: the role of posture and muscle imbalance. J Shoulder Elbow Surg, 2005;14(4):385-92. DOI: 10.1016/j.jse.2004.08.007
 8. Hagiwara Y, Kanazawa K, Ando A, Nimura A, Watanabe T, Majima K, Blood flow changes of the anterior humeral circumflex artery decrease with the scapula in internal rotation. Knee Surg Sports Traumatol Arthrosc, 2015;23(5):1467-72. DOI: 10.1007/s00167-013-2823-2
 9. Moseley HF, Goldie I, The Arterial Pattern of the Rotator Cuff of the Shoulder. J Bone Joint Surg Br, 1963. 45(4):780-9 PMID: 14074332
 10. Ko JY, Huang CC, Chen WJ, Chen CE, Chen SH, Wang CJ, Pathogenesis of partial tear of the rotator cuff: a clinical and pathologic study. J Shoulder Elbow Surg, 2006;15(3): 271-8. PMID: 16679225
 11. Guntern DV, Pfirrmann CW, Schmid MR, Zanetti M, Binkert CA, Schneeberger AG, Articular cartilage lesions of the glenohumeral joint: diagnostic effectiveness of MR arthrography and prevalence in patients with subacromial impingement syndrome. Radiology, 2003;226(1):165-70. PMID: 12511686
 12. Petersson CJ, Degeneration of the gleno-humeral joint: an anatomical study. Acta Orthop Scand, 1983;54(2):277-283. PMID: 6846007
 13. Singh HP, Mehta SS, Pandey R, A preoperative scoring system to select patients for arthroscopic subacromial decompression. J Shoulder Elbow Surg, 2014;23(9):1251-6. PMID: 25127909
 14. Watson M, Major ruptures of the rotator cuff. The results of surgical repair in 89 patients. J Bone Joint Surg Br, 1985;67(4):618-24 PMID: 4030862
 15. Wong MW, Tang YY, Lee SK, Fu BS, Chan BP, Chan CK, Effect of dexamethasone on cultured human tenocytes and its reversibility by platelet-derived growth factor. J Bone Joint Surg Am, 2003;85-A(10): 1914-20 . PMID: 14563798
 16. Yıldız V, Aydın A, Kalalı F, Yıldırım ÖS, Topal M, Aydın P, Kronik İmpingement Sendromlu Hastalarda Uygulanan Steroidin Artrioskopik Subakromiyal Dekompresyon Sonrasına Klinik Etkisi. Fırat Tıp Dergisi. 2012;17(1): 32-35.
 17. Brox JI, Gjengedal E, Uppheim G, Bohmer AS, Brevik JI, Ljunggren AE, Arthroscopic surgery versus supervised exercises in patients with rotator cuff disease (stage II impingement syndrome): a prospective, randomized, controlled study in 125 patients with a 2 1/2-year follow-up. J Shoulder Elbow Surg, 1999;8(2): 102-11. PMID: 10226960
 18. Karaman Ö, Karakuş Ö, Kaynak G, Çalışkan G, Saygı B, Artrioskopik subakromiyal dekompresyon: 1-4 yıllık sonuçlar. Şişli Etfal Tıp Bülteni, 2012;46(3):136-139.
 19. Beard DJ, Rees JL, Cook JA, Rombach I, Cooper C, Merritt N, Arthroscopic subacromial decompression for subacromial shoulder pain (CSAW): a multicentre, pragmatic, parallel group, placebo-controlled, three-group, randomised surgical trial. Lancet, 2018; 391(10118):329-338 DOI: 10.1016/S0140-6736(17)32457-1
 20. Bouchard A, Garret J, Favard L, Charles H, Ollat D, Failed subacromial decompression. Risk factors. Orthopaedics & Traumatology: Surgery & Research, 2014; 100(8): S365-S369 PMID: 25454330
 21. Bhattacharyya R, Edwards K, Wallace AW, Does arthroscopic sub-acromial decompression really work for sub-acromial impingement syndrome: a cohort study. BMC musculoskeletal disorders, 2014;15(1):324. PMID: 4190469
 22. Farfaras S, Sernert N, Rostgard Christensen L, Hallström EK, Kartus JT, Subacromial decompression yields a better clinical outcome than therapy alone: a prospective randomized study of patients with a minimum 10-year follow-up. The American journal of sports medicine, 2018. 46(6):1397-1407. PMID: 29543510
 23. Lerch S, Elki S, Jaeger M, Berndt T, Arthroskopische subakromiale Dekompression. Operative Orthopädie und Traumatologie, 2016. 28(5):373-391 DOI: 10.1007/s00064-016-0450-z
 24. Jaeger M, Berndt T, Rühmann O, Lerch S, Patients with impingement syndrome with and without rotator cuff tears do well 20 years after arthroscopic subacromial decompression. Arthroscopy: The Journal of Arthroscopic & Related Surgery, 2016;32(3): 409-415. PMID: 26507160

How to cite this article/Bu makaleye atıf için:
 Atik A. The Role Of Arthroscopic Decompression In Subacromial Impingement Syndrome. Acta Med. Alanya 2019; 3(3):28-253.
 doi:10.30565/medalanya.567430