

## CASE REPORT

# Alternative treatment method with mineral trioxide aggregate in open apex formation: Case report

Banu Arıcıoğlu(0000-0002-1124-1905)<sup>α</sup>, Ömer Hatipoğlu(0000-0002-4628-8551)<sup>β</sup>

*Selcuk Dent J, 2019; 6: 177-181 (Doi: 10.15311/selcukdentj.396838)*

Başvuru Tarihi: 19 Şubat 2018  
Yayına Kabul Tarihi: 27 Kasım 2018

### ABSTRACT

#### **Alternative treatment method with mineral trioxide aggregate in open apex formation: Case report**

The study aims to determine the efficiency and effectiveness of apexification treatment using mineral trioxide aggregate (MTA). For this purpose, two cases were taken into consideration in the examination on the basis of clinical records in the Faculty of Dentistry at Recep Tayyip Erdoğan University. These cases were a female patient at the age of 16 and a male patient at the age of 8. A treatment protocol was designed for and applied on both cases. This way, the whole treatment could be divided into three stages: preoperative, procedural and follow-up steps. The follow-up process consisted of two parts: clinical and radiographic examinations. In the procedural stage, the clinician first rinsed the root canals with 5 ml of 2.5% NaOCl and administered calcium hydroxide (CH) in the canals and allowed it to remain within a 1-week period in order to fill the apical area (4 mm) of the immature, necrotic permanent incisors with an MTA plug. After MTA application, the clinic doctor filled the rest with gutta-percha cones. On the clinical and radiographic follow-ups performed semi-annually within one year, the lesions were dissected, and the tissues were regenerated in the periradicular area. In conclusion, use of MTA material was determined as an efficient and effective method in apexification with respect to time and quality of treatment and it is still a well-accepted technique.

### KEYWORDS

**Apexification, MTA bio, periapical diseases**

### ÖZ

#### **Açık apeksli dişlerde mineral trioksit agregat ile alternatif tedavi yöntemi: Olgu sunumu**

Bu olgu sunumunun amacı apeksi açık dişlerde Mineral Trioksit Agregat (MTA) kullanımı sonucunda apeksifikasyon tedavisinin verimliliğinin ve etkinliğinin belirlenmesidir. Bu amaçla, Recep Tayyip Erdoğan Üniversitesi Diş Hekimliği Fakültesi'nde klinik kayıtlara göre 16 yaşında bir bayan ve 8 yaşında bir erkek olmak üzere 2 vaka ele alındı. Her iki olgu için ameliyat öncesi, uygulama ve takip aşamaları olmak üzere üç aşama planlandı. Takip süreci ise klinik ve radyografik incelemeler olarak belirlendi. Uygulamanın ilk aşamasında, kök kanalları 5 ml %2.5'lik NaOCl ile yıkandı ve bir hafta süre ile kalsiyum hidroksit (CH) uygulandı. Kök kanallarının apikal 4 mm'lik kısmı MTA ile kapatıldıktan sonra kalan kısmı gutta percha konileri ile dolduruldu. Bir yıl içerisinde altı ay ara ile yapılan klinik ve radyolojik takiplerde periapikal bölgedeki dokuların yeniden yapıldığı ve lezyonların iyileştiği tespit edildi. Sonuç olarak, MTA materyali apeksifikasyon tedavisinde tedavi süresi ve kalitesi de göz önünde bulundurulduğunda hala kabul edilebilir güçlü bir alternatif yöntemdir.

### ANAHTAR KELİMELER

**Apeksifikasyon, MTA bio, periapikal hastalık**

Some traumatic events that result in dentoalveolar injuries obviate the formation and maturation of a necrotic permanent tooth. As a result of root resorption, an immature incisor's apex would open wide. There is a requirement for much more time and a possibility of the unclear estimate of prognosis for the root canal treatment.

Apexification is one of the treatment methods applied to the patients with such dental problems. The apical area becomes an ideal environment by means of this method which forms a barrier<sup>1</sup> to constrain bacterial infection and induce tissue calcification. In this respect, calcium hydroxide (CH) is universally valid for apexification. There are a lot of disadvantages including much longer time requirement for continuous cooperation with patients, tooth cracks on the thin wall of the root during the clinical procedure<sup>2</sup>, and the barrier's porous structure even with

small particles of tissue.<sup>3</sup> Due to all these disadvantages, a barrier was artificially made as substitute for CH by Coviello and Brilliant in 1979.<sup>4</sup> To use an apical plug, Torabinejad and Chivian<sup>5</sup> developed a method with mineral trioxide aggregate (MTA), a hydrophilic powder of tricalcium silicate, tricalcium aluminate, tricalcium oxide and other mineral oxides. With a pH value of 12.5, the composite becomes solid in almost 4 hours following contact with a fluid.<sup>6</sup> In recent studies<sup>7,8</sup> its potential has been proven as a material to fill the apical part of the root canal, and it seems to have equal or greater importance than other similar ones have in consideration of dyeing and bacterial leakage.

<sup>α</sup> Department of Endodontics, Faculty of Dentistry, Recep Tayyip Erdoğan University, Rize, Turkey

<sup>β</sup> Department of Restorative Dentistry, Faculty of Dentistry, Sutcu Imam University, Kahramanmaraş, Turkey

The advantages of hard barrier formation may be listed as its ability of sealing, biocompatibility, low cytotoxicity, and its role as a starter for odontoblasts.<sup>9,10</sup>

This scientific article introduces the clinical results of MTA plug application and root formation under the apexification method.

## CASE PRESENTATION

### CASE 1

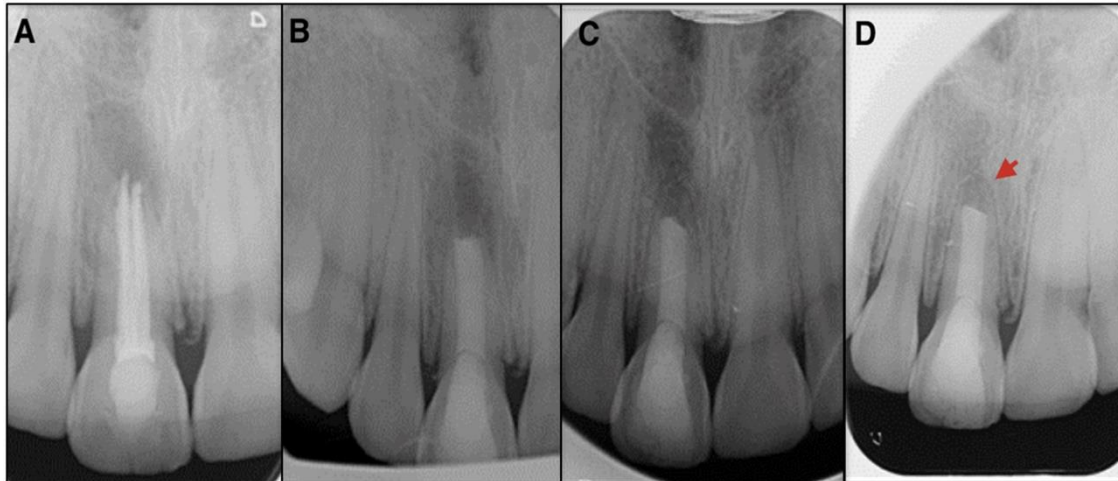
This was a retreatment case for a female patient at the age of 16 years who had a healthy history except for a trauma that she underwent on her teeth at 9 years, according to the hospital records of Faculty of Dentistry at Recep Tayyip Erdoğan University. At clinics, the root canal treatment that was made by an endodontist was unsuitable as her upper right incisor area was slightly discoloured and the labial sinus tract was detected as well as improper gutta-percha cones and wide-open apices of immature teeth as observed in radiography. To correct these results of bad treatment, it was determined that the impaired teeth would be recovered in consideration that the tooth was suitable for percussion. When the treatment was started, primarily local anesthesia was performed (0.012 mg; Ultracaine D-S Forte, Sanofi-Aventis Deutschland GmbH) and a rubber dam established. The pulp chamber was clean, and the canal was prepared using NiTi rotary files (ProTaper Universal, Dentsply/Maillefer, Ballaigues, Switzerland) following the removal of cones and application of 2.5% sodium hypochlorite (NaOCl). An apex locator (Sybron Endo, Sybron Dental, Orange, CA) and radiograph determined the working length, and the canal width was measured above an ISO 80 no. K-file (Beutelrock, München, Germany). After distilled water was added into CH (Kalsin; Spotdent, İzmir, Turkey) and the mixture was solidified, the resulting substance was embedded into the canal that had been dried with paper points and a cotton pellet was put into the area. The procedure was completed by closing the cavity with temporary filling material (Coltosol F; Coltosol Whaledent, Altstätten, Switzerland). Only 2 weeks were sufficient for the sinus tract to heal even without any symptoms thanks to the procedure. The CH tamp was taken out by means of a file and 5 ml of 2.5% NaOCl and 5 ml of 17% EDTA (Saver, Atik Dental, İstanbul, Turkey) were applied to clean the residual part. In order to get a plug in the apical area, paper points made the canal dry and a bit of sponge which could absorb with its gelatin substance

(Spongostan, Johnson and Johnson Medical, Skipton, U.K.) was compressed onto the apex via a hand plugger (Buchanan Hand Pluggers, Kerr). The guidelines of the manufacturer, (Angelus, Londrina, guidelines of the manufacturer, (Angelus, Londrina, PR, Brazil) were strictly followed to make a mixture for the MTA substance. A carrier was used to put it into the canal, while a plugger was used later to close its walls. Periapical radiography determined whether its position was appropriate. A pellet was put onto the chamber in wet and the hole was closed with a pack to set the MTA. On her visit the following day, the pellet was out, and the MTA was set. Then, the rest was closed with a technique, lateral condensation of the cones was applied into the canal with a sealer, AH Plus (Dentsply, DeTrey, Konstanz, Germany). On follow-up, coronal restoration had been provided with a hybrid composite (Clearfil ST, Kuraray Medical Co., Japan). The clinical results confirmed that the treatment method was effective as there were no symptoms even without the sinus tract. Radiography displayed the healing six-month later with the regenerating periradicular tissue and the newly forming apical cement.

### CASE 2

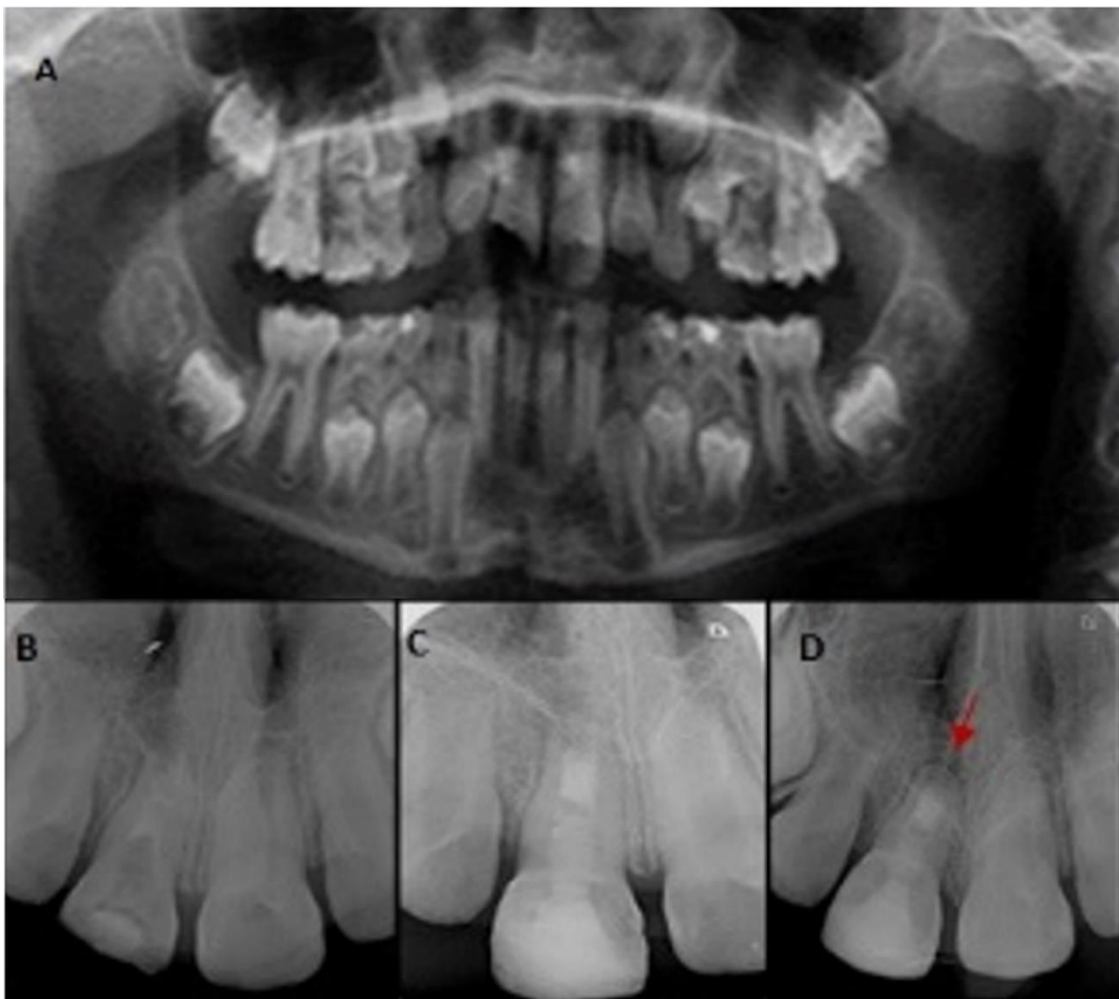Another case was a male patient at the age of 8 with a sinus tract in the upper right incisor area. Upon information given by his parents of a trauma on his teeth caused by a biking accident, crown cracks were extensive, open apices were immature and radiolucent lesion was absent according to periapical radiography in the clinical examination. The vitality test was failed and a percussion test could not be made because of tenderness. The treatment was followed under a protocol as above to form an MTA plug in the apical area.

One month later, an initial sign of healing was observed as a radiolucent image in radiograph was unseen for periapical lesion and symptoms were also absent. On follow-up visit 1-year later, the results of the examination on radiograph were that the periradicular lesion was resolute, the canal walls were increasingly thickening, the root was further developing, and the root apex was continuing to close.



**Figure 1.**

**a)** A radiograph displaying the preoperative situation of upper left central incisor with an open apex, **b)** A radiograph of the periapical positioning of the MTA plug, **c)** 6 month later and **d)** 1 year later follow-ups confirming complete recovery of the periapical radiolucent area by regeneration of periradicular tissue and the newly forming apical cement



**Figure 2.**

**a)** A radiograph displaying the preoperative situation of upper central incisors with open apices, **b)** A radiograph showing the root filled with MTA in its apical part, **c)** 6 months and **d)** 1 year later follow-ups confirming recovery of the radiolucent area with the closure of root apex

## DISCUSSION

The major problem of traumatized teeth can be dealt with apexification in which open apices are adequately closed in those with pulpal necrosis. There is some evidence that CH is almost the best material for such a treatment method with a high rate of success.<sup>5</sup> However, it has a disadvantage of long duration<sup>11</sup> so that reinfection is possible due to a crack and leak on the coronal filling material established for a specific time period. Even if the canal treatment is unquestionable, the rate of achievement is likely to be below 10% in relation to the insufficient restoration of the crown and possible tooth crack as well.<sup>12</sup> The teeth become less resistant to fractures due to CH left in the root canal for 30 days or longer. Therefore, a MTA apical plug is preferable to CH treatment. Sealing ability, marginal adaptation, biocompatibility, alkaline pH, calcium and phosphate ions and shorter time, which are all needed for achievement in healing the trauma, are the advantages of MTA in depositing hard tissue over it and providing a desired environment for the formation of cement.<sup>13</sup> MTA provides scaffolding to promote the formation of hard tissue. However, the orthograde method is sensitive to manipulate and verify MTA by radiography.

Recently, a novel procedure was introduced based on biological treatment. Regenerative endodontic treatment aims to allow regeneration of pulp tissue and sustain root apex formation.<sup>14</sup> However, some studies<sup>15,16</sup> reported many disadvantages and unfavourable outcomes such as discolouration of the tooth, long disinfection time and more clinical visits compared to the one-visit MTA apical barrier technique. In addition, some studies<sup>17-19</sup> showed that inadequate root length, wall thickness and apex formation in cases were treated with the regenerative endodontic procedure. A recent study<sup>18</sup> reported recovery of all periradicular lesions in cases treated with ideal disinfection protocols.

The successful outcomes in this study are similar to previously reported cases<sup>9,20</sup> of MTA plug application in the necrotic and open apices teeth. In a case series presentation<sup>21,11</sup> teeth with apical periodontitis and buccal sinus tract of endodontic origin were treated with MTA apical plug application. After 2 years of follow-up complete healing was observed in 10 of 11 cases. In another study<sup>22</sup>, seventy-two patients with 78 teeth with chronic apical periodontitis and extreme apical enlargement treated with MTA apical plug were evaluated retrospectively. For the result, 100% rate of healing was observed at the teeth without periapical radiolucency and 78% rate of healing was observed at the teeth with preoperative periapical radiolucency. These studies supports the successful results of the current study. On the other hand, failures in same cases can be attributed to the difficulty of applying the MTA and removing easily from the root canal area due to the long hardening time.

Hachmeister et al<sup>23</sup> reported that, the irregular dentinal walls in the necrotic teeth and the divergent apices make the adaptation of MTA more difficult and it doubts the sealing ability. But, on the contrary, Aminoshariae et al<sup>24</sup> (showed the handcondensation of MTA by radiographic imaging resulted in better adaptation than ultrasonic compaction. In the present study, the MTA apical plugs were placed by a standardized handcondensation technique. In the cases of needed retreatment, is not easy to remove and requiring an ultrasonic device is one of the disadvantages.

As applied in this study, the treatment method confirmed that MTA allows establishing a normal periodontal ligament and forming a new bone and cementum when it is started as soon as the root canal is ready. Even if exudate and contamination are observed in the preparation stage, MTA acts like a CH paste and cleans the canal from infection, as well as establishing a hard tissue barrier in the apical area. Likewise, one study suggested that hard tissue can be formed by a MTA by statistical significance.<sup>10</sup>

Consequently, we aimed to show medicinal results with this study by using an MTA substance to treat any trauma that is a cause of immaturity in permanent teeth. This study is very satisfactory, yet it is for sure that further research needs to be conducted on this issue. We recommend conduction of randomized clinical trials that compare the outcomes of new approaches of regenerative endodontic procedures to the traditional MTA apical barrier technique in longitudinal terms.

## CONCLUSION

In conclusion, the applied method of a MTA apical plug was efficient in terms of treatment duration and effective so as to post-operative resistance to cracks in immature permanent teeth. According to the treatment of two cases in the study, follow-up visits clinically and radiographically confirmed that periodontitis could be healed in the apical area and hard tissue formed in the adjacent teeth by means of the treatment method. This can produce similar results to another case where MTA was applied to central incisor, and thus the advantage of quicker healing can be made use of in treatment for central permanent teeth. Its biocompatibility feature is provided by new cementum, bone and periodontal ligament. As a conclusion, MTA is an efficient and effective material for apexification treatment in time and quality.

## REFERENCES

1. Moretton TR, Brown CE, Legan JJ, Kafrawy A. Tissue reactions after subcutaneous and intraosseous implantation of mineral trioxide aggregate and ethoxybenzoic acid cement. *Journal of Biomedical Materials Research Part A*, 2000, 52: 528-33.
2. Pinar Erdem A, Sepet E. Mineral trioxide aggregate for obturation of maxillary central incisors with necrotic pulp and open apices. *Dental Traumatology*, 2008, 24.
3. Bakland L. Management of traumatically injured pulps in immature teeth using MTA. *Journal of the California Dental Association*, 2000, 28: 855-8.
4. Schumacher JW, Rutledge RE. An alternative to apexification. *Journal of endodontics*, 1993, 19: 529-31.
5. Torabinejad M, Ford T. Root end filling materials: a review. *Dental Traumatology*, 1996, 12: 161-78.
6. Torabinejad M, Chivian N. Clinical applications of mineral trioxide aggregate. *Journal of endodontics*, 1999, 25: 197-205.
7. Moretti A, Oliveira T, Sakai V, Santos C, Machado M, Abdo R. Mineral trioxide aggregate pulpotomy of a primary second molar in a patient with agenesis of the permanent successor. *International endodontic journal*, 2007, 40: 738-45.
8. Torabinejad M, Watson T, Ford TP. Sealing ability of a mineral trioxide aggregate when used as a root end filling material. *Journal of endodontics*, 1993, 19: 591-5.
9. Felipe W, Felipe M, Rocha M. The effect of mineral trioxide aggregate on the apexification and periapical healing of teeth with incomplete root formation. *International endodontic journal*, 2006, 39: 2-9.
10. Shabahang S, Torabinejad M, Boyne PP, Abedi H, McMillan P. A comparative study of root-end induction using osteogenic protein-1, calcium hydroxide, and mineral trioxide aggregate in dogs. *Journal of endodontics*, 1999, 25: 1-5.
11. Metzger Z, Solomonov M, Mass E. Calcium hydroxide retention in wide root canals with flaring apices. *Dental Traumatology*, 2001, 17: 86-92.
12. Schwartz RS, Mauger M, Clement DJ, Walker WA. Mineral trioxide aggregate: a new material for endodontics. *The Journal of the American Dental Association*, 1999, 130: 967-75.
13. Sarkar N, Caicedo R, Ritwik P, Moiseyeva R, Kawashima I. Physicochemical basis of the biologic properties of mineral trioxide aggregate. *Journal of endodontics*, 2005, 31: 97-100.
14. Hargreaves KM, Geisler T, Henry M, Wang Y. Regeneration potential of the young permanent tooth: what does the future hold? *Journal of endodontics*, 2008, 34: 51-6.
15. Kim J-H, Kim Y, Shin S-J, Park J-W, Jung I-Y. Tooth discoloration of immature permanent incisor associated with triple antibiotic therapy: a case report. *Journal of endodontics*, 2010, 36: 1086-91.
16. Reynolds K, Johnson J, Cohenca N. Pulp revascularization of necrotic bilateral bicuspids using a modified novel technique to eliminate potential coronal discoloration: a case report. *International endodontic journal*, 2009, 42: 84-92.
17. Chen MH, Chen KL, Chen CA, Tayebaty F, Rosenberg P, Lin L. Responses of immature permanent teeth with infected necrotic pulp tissue and apical periodontitis/abscess to revascularization procedures. *International endodontic journal*, 2012, 45: 294-305.
18. Nosrat A, Homayounfar N, Oloomi K. Drawbacks and unfavorable outcomes of regenerative endodontic treatments of necrotic immature teeth: a literature review and report of a case. *Journal of endodontics*, 2012, 38: 1428-34.
19. Petrino JA, Boda KK, Shambarger S, Bowles WR, McClanahan SB. Challenges in regenerative endodontics: a case series. *Journal of endodontics*, 2010, 36: 536-41.
20. Shabahang S, Torabinejad M. Treatment of teeth with open apices using mineral trioxide aggregate. *Practical Periodontics and Aesthetic Dentistry*, 2000, 12: 315-20.
21. Pace R, Giuliani V, Pini Prato L, Baccetti T, Pagavino G. Apical plug technique using mineral trioxide aggregate: results from a case series. *International endodontic journal*, 2007, 40: 478-84.
22. Mente J, Hage N, Pfefferle T, Koch MJ, Dreyhaupt J, Staehle HJ, Friedman S. Mineral trioxide aggregate apical plugs in teeth with open apical foramina: a retrospective analysis of treatment outcome. *Journal of endodontics*, 2009, 35: 1354-58.
23. Hachmeister DR, Schindler WG, Walker WA, Thomas DD. The sealing ability and retention characteristics of mineral trioxide aggregate in a model of apexification. *Journal of endodontics*, 2002, 28: 386-90.
24. Aminoshariae A, Hartwell GR, Moon PC. Placement of mineral trioxide aggregate using two different techniques. *Journal of endodontics*, 2003, 29: 679-82.

Corresponding Author:

Banu ARICIOĞLU  
 Department of Endodontics  
 Faculty of Dentistry  
 Recep Tayyip Erdoğan University  
 5300, Merkez, Rize, Turkey  
 Tel : +90 464 222 00 00 - 01  
 E-Mail : banu.arc@gmail.com